

IMMEDIATE BONE AUGMENTATION AFTER INFECTED TOOTH EXTRACTION USING TITANIUM MEMBRANES

Efraim Kfir, DDS; Vered Kfir, DDS; Edo Kaluski, MD

Infectious process frequently results in extensive bone resorption and defect, periradicular or periapical lesions, or vertical fracture with infected sinus tract. When tooth extraction is mandated it typically results in additional bone loss in the buccal or lingual cortical plate. Immediate guided bone regeneration (GBR) and implant fixation at an infected site is frequently complicated by soft-tissue dehiscence, membrane exposure, and implant failure. The objective of this research is to assess the feasibility of immediate bone augmentation (IBA) after purulent tooth extraction, employing a dedicated titanium membrane. An intrasulcular incision was made around the tooth to be extracted and extended to 2 adjacent teeth while maintaining the papillae. Vertical releasing incisions were made to mobilize the mucoperiosteal flap. Cautious tooth extraction was executed utilizing conventional measures and was followed by meticulous curettage of the infected and granulated tissue in the socket. Titanium membranes were applied to the socket walls followed by socket filling with autologous platelet-rich fibrin and primary closure. Eight or more weeks later membrane removal and implant placement were performed. Of the 15 patients who underwent this procedure, 7 patients (47%) had early membrane exposure (between weeks 2 and 6), which was treated conservatively. No infection or early membrane removal was reported. All patients achieved sufficient bone augmentation, and 8 patients received implants without any additional GBR. IBA after infected tooth extraction, using titanium membrane application was feasible and safe and yielded adequate bone filling to support implant fixation at ≥ 8 weeks. Further studies need to evaluate if the titanium membrane helped in any way to inhibit plaque accumulation or resist infection in cases of early membrane exposure.

Key Words: guided bone regeneration, bone augmentation, titanium membrane

Efraim Kfir, DDS, is in private practice at the Dental Clinic in Petah-Tikvah, Israel.

Vered Kfir, DDS, is in private practice at the Dental Clinic in Kupat Holim Clalit, Rehovot, Israel.

Edo Kaluski, MD, associate professor of medicine, director of cardiac catheterization laboratories and invasive cardiology, University of Medicine and Dentistry of New Jersey, Newark. Address correspondence to Dr. Kaluski at 812 Sun Valley Way, Florham Park, NJ 07932 (email: ekaluski@gmail.com).

INTRODUCTION

Immediate implant placement after tooth extraction may result in early implant failure caused by insufficient mature bone mass and quality¹ to adequately support the implant, and difficulty in obtaining complete coverage of the extraction socket by soft tissue. Even if primary closure is accomplished, early membrane exposure by epithelial dehiscence can occur. This may cause membrane exposure and infection, which can jeopardize bone

augmentation²⁻³ and ultimately may result in implant failure.⁴ Placement of the implant immediately after tooth extraction reduces costs, surgical procedures, and time to rehabilitation while preserving papillae and soft-tissue scalloping. Appropriately selected immediate implant cases have reported short-term (1–2.5 years) success rates approximately equal to 90%.⁵ However, there is a higher (threefold) incidence of early membrane exposure⁶ and infections when compared to early implant placement (after 8 weeks), especially when immediate bone augmentation (IBA) was simultaneously performed with implant placement.⁷ Jovanovic⁸ suggested that immediate implants require sufficient bone wall around the extraction socket and apical to the bottom of the extraction socket for primary stability, and an absence of lesion in the extraction socket. Sufficient soft tissue for wound closure is also required.

The decision whether to perform immediate⁹⁻¹⁰ or delayed guided bone regeneration (GBR) and implant placement¹¹ is subject to considerable debate. Some clinicians suggest that simultaneous GBR and implant placement can be performed 2 months after tooth extraction with membrane removal 6 months later.¹² If the condition of the alveolar ridge is poor, immediate GBR and delayed implant placement may be the preferred option, but this has not been supported by a randomized clinical trial.¹³ IBA prevents the additional bone resorption that typically occurs in the initial 6 months post extraction and abbreviates the rehabilitation period. Unfortunately, a higher failure rate caused by early membrane exposure¹ with subsequent infection remains a concern.

Since it is difficult to define the acuity, severity, and histology of the bone-destructive process responsible for both tooth loss and bone deficit, it is cumbersome to conduct a randomized clinical trial to define the best strategy. In the absence of randomized clinical trials, the optimal time for GBR in reference to the tooth extraction and implant fixation is controversial and should be individualized based on patient and lesion characteristics.

The absolute contraindications to IBA are not well defined. Patients with such pathologies as vertical fracture with infected sinus tract, extensive periodontal disease or external resorption, and severe periapical or periradicular process, are not considered ideal candidates for either IBA or immediate implant placement.

Contraindications for immediate implant placement include extensive deficient alveolar bone, close proximity to the mandibular canal and maxillary sinus, inability to achieve primary closure of the surgical

incision, and extensive periapical or gingival inflammatory process.¹⁴ Unfortunately, complications requiring unplanned additional surgical procedures may approach 50%¹⁵ in high-risk groups.

This report documents 15 consecutive cases of immediate bone augmentation in a subset of high-risk patients using a titanium membrane.

METHODS

Patients

Study participants were candidates for tooth extraction because of an extensive inflammatory process including one or more of the following pathologies: vertical fracture with infected sinus tract, extensive periodontal disease or alveolar ridge resorption, and/or severe periapical or periradicular process. All patients received an explanation regarding the procedure and signed an informed consent.

Equipment and materials

- Silk sutures 3/0, polypropylene Nylon 5/0 sutures (CliniSut, Sasurel, Middlesex, UK)
- Titanium membrane (Hi-Tec Implants Herzlia, Israel)
- Autologous fibrin obtained by centrifugation of 40 mL autologous blood divided into 4 test tubes and spinned for 10 minutes at 2700 rpm by FiberTec centrifuge.
- Synthetic bone graft (Bi-Ostetic, Berkeley Advanced Biomaterials Inc, San Leandro, Calif).

Procedure

A preprocedural nonsteroidal anti-inflammatory agent (Celecoxib, 200 mg daily) and amoxicillin and clavulanate potassium (Augmentin 875, Smithkline Beecham Healthcare Ltd, Brentford, UK) administered twice daily, were initiated 24 hours prior to the procedure. Nitric oxide gas was administered, and local anesthesia (infiltration of buccal and palatal region in upper jaw, and inferior mandibular and long buccal block in the lower jaw) was accomplished by articain 4% (Ubistesin forte, 3M ESPE AG, Seefeld, Germany). An intrasulcular flap-releasing incision was made around the tooth to be extracted and extended to 2 adjacent teeth while carefully maintaining the papillae ("envelope flap").

Atraumatic tooth extraction was performed according to conventional standards and was followed by meticulous curettage of the infected and granulated tissue in the socket (Figure 1a). The defect size was measured with a periodontal probe, and the

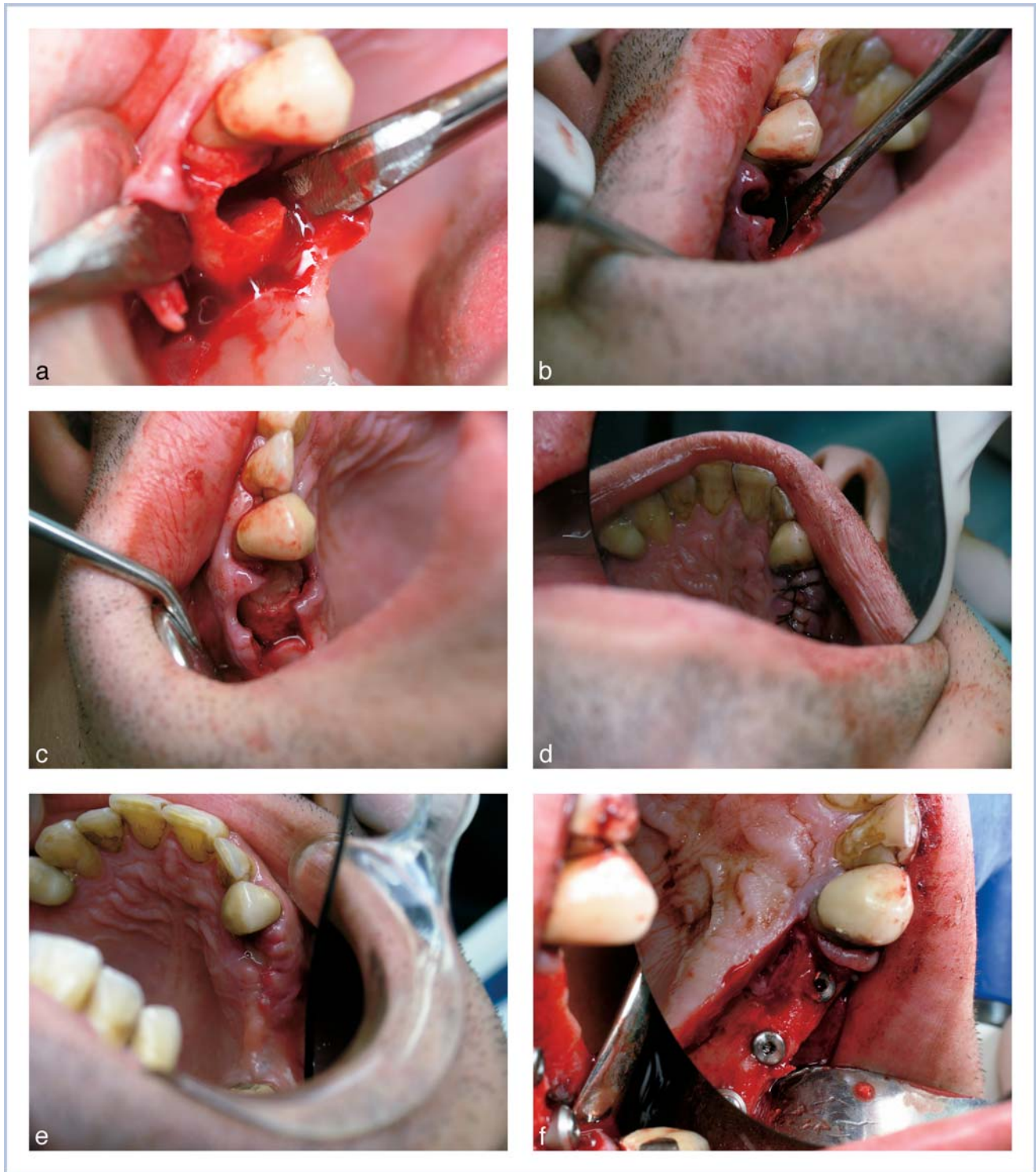


FIGURE 1. (a) Absence of lingual cortical plate after tooth extraction. (b) Membrane application after socket debridement. (c) Socket filling with platelet-rich fibrin. (d) Primary closure. (e) 1 Week after tooth extraction. (f) 8 Weeks after tooth extraction—implant fixation.

TABLE 1
Case descriptions

Case #	Tooth #	Reason for Tooth Extraction	Plate Affected*
1	25/26	Caries, sinus tract, and periapical lesion	B
2	45	Vertical fracture and sinus tract	B
3	25	Vertical fracture and sinus tract	B
4	14	Vertical fracture and sinus tract	P
5	24/26	Periodontal	B + P
6	11/21	Periradicular process and periodontal	M + B
7	15	Periodontal	B
8	36	Sinus tract and external resorption	B + L
9	13	Vertical fracture and sinus tract	B + P
10	14/15	Caries and periapical process	B
11	36	Vertical fracture and sinus tract	B + L
12	14	Vertical fracture and sinus tract	B
13	15	Periradicular process	B + P
14	24	Vertical fracture and sinus tract	B
15	25	Periapical process and sinus tract	B

*Plate affected: B indicates buccal; L, lingual; M, medial/mesial; P, palatal.

titanium membrane was trimmed ≥ 2 mm from each direction of the measurements obtained. It was then applied to the socket walls (Figure 1b) and the socket was filled (Figure 1c) with autologous platelet-rich fibrin (PRF). Primary closure was achieved by using 3/0 interrupted and horizontal sutures (Figure 1d). In case of tension, 2 vertical incisions and a coronally positioned flap were performed. Simple interrupted 5/0 sutures were applied to the vertical incision. The patient was instructed to rinse the mouth with chlorhexidine 0.2% twice daily, continue antibiotic therapy for 7 days, and not to wear any prosthesis, chew or brush on the affected area for at least 2 weeks. Seven days after surgery the patient was reapointed for wound inspection and suture re-

TABLE 2
Procedure description

Case #	Time to Membrane Exposure (wk)	Implant Time (wk)	Implant Diameter (mm)	Socket Fill*
1	None	8	4.2	PRF
2	5	12	3.75	PRF
3	2	16	4.2	PRF
4	None	13	3.75	PRF
5	None	11	4.2	PRF & Bo
6	3	n/a	n/a	PRF & Bo
7	1	18	4.2	PRF & Bo
8	5	10	4.1	PRF & Bo
9	6	n/a	n/a	PRF
9	2	10	4.2/4.2	PRF
11	None	n/a	n/a	PRF
12	None	n/a	n/a	PRF
13	None	n/a	n/a	PRF
14	None	n/a	n/a	PRF
15	None	n/a	n/a	PRF

*Socket fill: Bo indicates Bi-Ostetic synthetic bone graft; PRF, platelet-rich fibrin.

moval (Figure 1e). Eight weeks later, membrane removal and implant placement were performed (Figure 1f).

RESULTS

Tables 1 and 2 summarize the results of immediate bone augmentation employing titanium membranes (Figures 2a through 3d). Patients ranged in age between 28 and 63 years (mean age was 38). Eight patients (53%) were female and 7 (47%) were male. Seven patients (47%) experienced early membrane exposure (between weeks 2 and 6), which was treated conservatively by plaque control and oral hygiene. There were no infections warranting early membrane

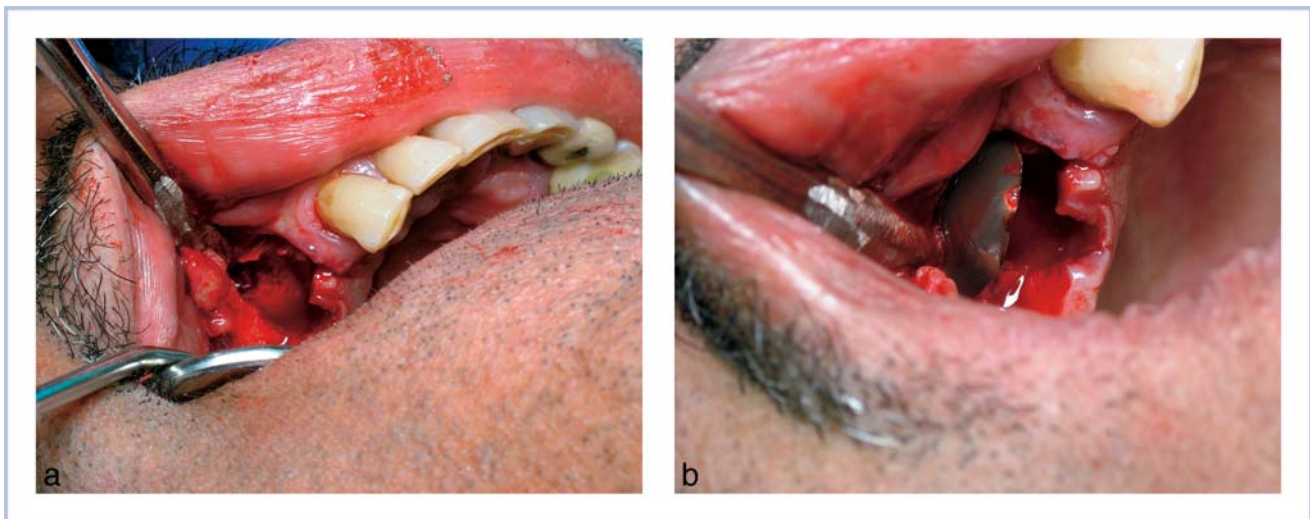


FIGURE 2. (a) Extensive loss of buccal and cortical plate. (b) Membrane application after socket debridement.

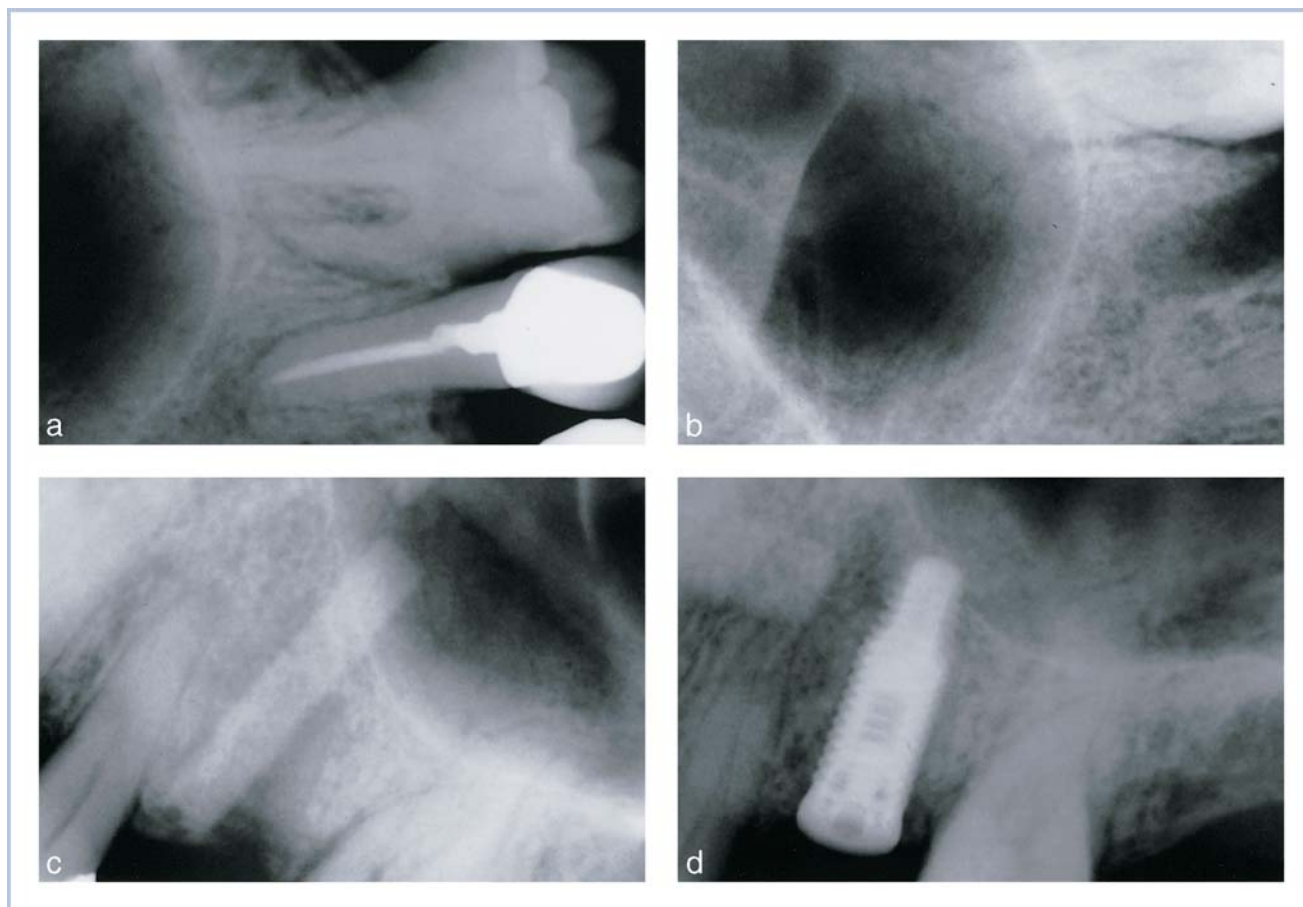


FIGURE 3. (a) Pre-extraction—after vertical fracture. (b) Immediately postextraction of tooth #25 and titanium membrane application with socket filling using platelet-rich fibrin. (c) 16 Weeks postextraction. (d) Implant fixation.

removal. In all patients, sufficient bone augmentation was documented and 8 patients were subsequently treated with implants without any additional guided bone regeneration.

DISCUSSION

In this study early bone augmentation after extraction of infected teeth and extensive bone loss was executed safely using a titanium barrier membrane accompanied by socket filling with PRF or occasionally with synthetic bone graft material. Although early membrane exposure occurred in 47% of these patients, it was not associated with any apparent infection or problem, and did not jeopardize bone augmentation. Some of these patients underwent uneventful implant placement 10 to 18 weeks after the initial surgical procedure. Whether the membrane material affected the quality and extent of GBR could not be determined by the present study. Some researchers suggested that polytetrafluoroethylene (PTFE) membranes are superior to resorbable mem-

branes (human study),¹⁶ or titanium membranes (limited dog study),¹⁷ while other investigators found collagen membranes to be as effective as PTFE membranes.¹⁸

Based on previous reports employing titanium foil¹⁹ or micromesh, either alone²⁰ or in conjunction with PTFE membrane,²¹ and the limited results of the present study, we believe that the titanium membranes serve as an excellent barrier membrane for GBR. Large-scale randomized clinical trials need to confirm these initial encouraging observations and to determine if titanium membranes are less susceptible to infection than PTFE membranes. Whether any additional bone augmentation material adds to IBA is also an open question as some canine models suggest that no filling material enhances implant osseointegration.²²

CONCLUSION

Immediate bone augmentation after infected tooth extraction employing titanium membrane, PRF, and

occasional synthetic bone graft material, yielded adequate bone fill to support implant placement at approximately 8 weeks. Further studies need to investigate whether titanium membranes are more resistant to plaque accumulation and infection than other membrane materials subjected to early membrane exposure.

NOTE

The authors of this manuscript have no financial association that might pose a conflict of interest in connection with the submitted proposal.

REFERENCES

1. Nevins M, Mellonig JT. The advantages of localized ridge augmentation prior to implant placement: a staged event. *Int J Periodontics Restorative Dent*. 1994;14:96–111.
2. Becker W, Dahlin C, Becker BE, et al. The use of e-PTFE barrier membranes for bone promotion around titanium implants placed into extraction sockets: a prospective multicenter study. *Int J Oral Maxillofac Implants*. 1994;9:31–40.
3. Lekholm U, Becker W, Dahlin C, Becker B, Donath K, Morrison E. The role of early versus late removal of GTAM membranes on bone formation at oral implants placed into immediate extraction sockets. An experimental study in dogs. *Clin Oral Implants Res*. 1993;4:121–129.
4. Becker W, Dahlin C, Lekholm U, et al. Five-year evaluation of implants placed at extraction and with dehiscences and fenestration defects augmented with ePTFE membranes: results from a prospective multicenter study. *Clin Implant Dent Relat Res*. 1999;1:27–32.
5. Schropp L, Kostopoulos L, Wenzel A. Bone healing following immediate versus delayed placement of titanium implants into extraction sockets: a prospective clinical study. *Int J Oral Maxillofac Implants*. 2003;18:189–199.
6. Mensdorff-Pouilly N, Haas R, Mailath G, Watzek G. The immediate implant: a retrospective study comparing the different types of immediate implantation. *Int J Oral Maxillofac Implants*. 1994;9:571–578.
7. Gotfredsen K, Nimb L, Buser D, Hjorting-Hansen E. Evaluation of guided bone generation around implants placed into fresh extraction sockets: an experimental study in dogs. *J Oral Maxillofac Surg*. 1993;51:879–884.
8. Jovanovic S, Buser D. Guided tissue regeneration in dehiscence defects and delayed extraction sockets. In: Buser D, Dahlin C, Schenk RK, eds. *Guided Bone Regeneration in Implant Dentistry*. Chicago: Quintessence; 1994:155–188.
9. Paolantonio M, Dolci M, Scarano A, et al. Immediate implantation in fresh extraction sockets. A controlled clinical and histological study in man. *J Periodontol*. 2001;72:1560–1571.
10. Becker W, Sennerby L, Bedrossian E, Becker BE, Lucchini JP. Implant stability measurements for implants placed at the time of extraction: a cohort, prospective clinical trial. *J Periodontol*. 2005;76:391–397.
11. Nemcovsky CE, Artzi Z, Moses O, Gelernter I. Healing of marginal defects at implants placed in fresh extraction sockets or after 4–6 weeks of healing. A comparative study. *Clin Oral Implants Res*. 2002;13:410–419.
12. Buser D, Dula K, Hirt HP, Schenk RK. Lateral ridge augmentation using autografts and barrier membranes: a clinical study with 40 partially edentulous patients. *J Oral Maxillofac Surg*. 1996;54:420–432.
13. Esposito M, Grusovin MG, Worthington HV, Coulthard P. Interventions for replacing missing teeth: bone augmentation techniques for dental implant treatment. *Cochrane Database Syst Rev*. 2006;1:1–22.
14. Block MS, Kent JN. Placement of endosseous implants into tooth extraction sites. *J Oral Maxillofac Surg*. 1991;49:1269–1276.
15. Augthun M, Yildirim M, Spiekermann H, et al. healing of bone defects in combination with immediate implants using membrane technique. *Int J Oral Maxillofac Implants*. 1995;10:421–428.
16. Simion M, Scarano A, Gionso L, Piattelli A. Guided bone regeneration using resorbable and nonresorbable membranes: a comparative histologic study in humans. *Int J Oral Maxillofac Implants*. 1996;11:735–742.
17. Celletti R, Davarpanah M, Etienne D, et al. Guided tissue regeneration around dental implants in immediate extraction sockets: comparison of e-PTFE and a new titanium membrane. *Int J Periodontics Restorative Dent*. 1994;14:242–253.
18. Mao C, Sato J, Matsuura M, Seto K. Guided tissue regeneration around dental implants in immediate extraction sockets: comparison of resorbable and nonresorbable membranes. *Chin Med Sci J*. 1997;12:170–174.
19. Gaggl A, Schultes G. Titanium foil-guided tissue regeneration in the treatment of periimplant bone defects. *Implant Dent*. 1999;8:368–375.
20. Degidi M, Scarano A, Piattelli A. Regeneration of the alveolar crest using titanium micromesh with autologous bone and a resorbable membrane. *J Oral Implantol*. 2003;29:86–90.
21. Assenza B, Piattelli M, Scarano A, Lezzi G, Petrone G, Piattelli A. Localized ridge augmentation using titanium micro-mesh. *J Oral Implantol*. 2001;27:287–292.
22. Kohal RJ, Mellas P, Hurzeler MB, Trejo PM, Morrison E, Caffesse RG. The effects of guided bone regeneration and grafting on implants placed into immediate extraction sockets. An experimental study in dogs. *J Periodontol*. 1998;69:927–937.