

A SURVEY OF RADIOGRAPHIC MEASUREMENT ESTIMATION IN ASSESSMENT OF DENTAL IMPLANT LENGTH

Juliana Aparecida Najarro Dearo de Moraes, DDS; Celso Eduardo Sakakura, DDS, PhD; Leonor de Castro Monteiro Loffredo, PhD; Gulnara Scaf, DDS, PhD

The aim of this study is to survey radiographic measurement estimation in the assessment of dental implant length according to dentists' confidence. A 19-point questionnaire with closed-ended questions was used by two graduate students to interview 69 dentists during a dental implant meeting. Included were 12 questions related to over- and underestimation in three radiographic modalities: panoramic (P), conventional tomography (T), and computerized tomography (CT). The database was analyzed by Epi-Info 6.04 software and the values from two radiographic modalities, P and T, were compared using a χ^2 test. The results showed that 38.24% of the dentists' confidence was in the overestimation of measurements in P, 30.56% in T, and 0% in CT. On the other hand, considering the underestimated measurements, the percentages were 47.06% in P, 33.33% in T, and 1.92% in CT. The frequency of under- and overestimation were statistically significant ($\chi^2 = 6.32$; $P = .0425$) between P and T. CT was the radiographic modality with higher measurement precision according to dentists' confidence. In conclusion, the interviewed dentists felt that CT was the best radiographic modality when considering the measurement estimation precision in preoperative dental implant assessment.

Key Words: dental radiography, panoramic radiography, computerized tomography, radiological measurements, dental implants, survey

INTRODUCTION

Osseointegrated implants are indicated in the rehabilitation of edentulous jaws. Long-term clinical success is based on careful diagnosis and treatment planning.¹⁻³ Preoperative planning for implant surgery includes the radiographic examination that provides information related to the localization of anatomical landmarks and the quality and quantity of bone available for implant placement in the potential areas.⁴⁻⁵

Presurgical radiographic examination in dental implants is an important aspect when selecting sites for an ideal number, an optimal size, and a correct position of implants.⁶ The American Academy of Oral and Maxillofacial Radiology (AAOMR)⁷ recommends

Juliana Aparecida Najarro Dearo de Moraes, DDS, Celso Eduardo Sakakura, DDS, PhD, and Gulnara Scaf, DDS, PhD, are at the Department of Diagnosis and Surgery, and Leonor de Castro Monteiro Loffredo, PhD, is an associate professor at the Department of Social Dentistry, Araraquara Dental School, UNESP, São Paulo State University, Araraquara, São Paulo, Brazil. Dr. Dearo de Moraes is pursuing her doctoral degree. Dr. Sakakura is an associate professor and Dr. Scaf is a professor. Address correspondence to Dr. Scaf at Departamento de Diagnóstico e Cirurgia, Faculdade de Odontologia de Araraquara, UNESP, Rua Humaitá, 1680, Araraquara, São Paulo, Brazil (e-mail address: scaf@foar.unesp.br).

TABLE 1

Questionnaire used in this study

1. Which radiographic examination is most prescribed in the dental implant assessment?
 - Panoramic radiography
 - Computed tomography
 - Conventional tomography
 - Periapical radiography
 - Periapical and panoramic radiographs
 - Panoramic radiography and computed tomography
 - Panoramic radiography and conventional tomography
 - Panoramic radiography, computed tomography, and periapical radiography
 - Panoramic radiography, conventional tomography, and periapical radiography
 - Other radiographs
 - I don't know
2. What are the motivating factors when you choose the radiographic examination?
 - Cost
 - Measurement precision
 - Availability
 - Low radiation dose
 - Broad coverage
 - Cost + measurement precision
 - Cost + availability
 - Cost + low radiation dose
 - Cost + broad coverage
 - Other reasons
 - I don't know
3. Do you have problems with overestimated measurements in panoramic radiography?
 - Yes
 - No
 - I don't know
 - Not applicable
4. If the above answer was "yes", what is the frequency of overestimated measurements?
 - High
 - Medium
 - Low
 - Minimal
 - I don't know
 - Not applicable
5. Do you have problems with underestimated measurements in panoramic radiography?
 - Yes
 - No
 - I don't know
 - Not applicable
6. If the above answer was "yes", what is the frequency of the underestimated measurements?
 - High
 - Medium
 - Low
 - Minimal
 - I don't know
 - Not applicable
7. Have you ever used computed tomography for dental implant planning?
 - Yes
 - No
 - I don't know

TABLE 1

Continued.

8. If the above answer was "yes", how frequently do you use computed tomography in clinical cases?
 - High
 - Medium
 - Low
 - Minimal
 - I don't know
 - Not applicable
9. Do you have problems with overestimated measurements in computed tomography?
 - Yes
 - No
 - I don't know
 - Not applicable
10. If the above answer was "yes", what is the frequency of the overestimated measurements?
 - High
 - Medium
 - Low
 - Minimal
 - I don't know
 - Not applicable
11. Do you have problems with underestimated measurements in computed tomography?
 - Yes
 - No
 - I don't know
 - Not applicable
12. If the above answer was "yes", what is the frequency of the underestimated measurements?
 - High
 - Medium
 - Low
 - Minimal
 - I don't know
 - Not applicable
13. Have you ever used conventional tomography for dental implant planning?
 - Yes
 - No
 - I don't know
14. If the above answer was "yes", how frequently do you use conventional tomography in clinical cases?
 - High
 - Medium
 - Low
 - Minimal
 - I don't know
 - Not applicable
15. Do you have problems with overestimated measurements in conventional tomography?
 - Yes
 - No
 - I don't know
 - Not applicable
16. If the above answer was "yes", what is the frequency of the overestimated measurements?
 - High
 - Medium
 - Low
 - Minimal
 - I don't know
 - Not applicable

TABLE 1
Continued.

17. Do you have problems with underestimated measurements in conventional tomography?
 Yes
 No
 I don't know
 Not applicable
18. If the above answer was "yes", what is the frequency of the underestimated measurements?
 High
 Medium
 Low
 Minimal
 I don't know
 Not applicable
19. In what clinical conditions do you use periapical radiography?
 Treatment planning
 During surgery
 Post-surgical
 Follow-up
 Second surgical procedure
 I don't know
 Not applicable

the use of cross-sectional images for the implant site evaluation, such as conventional tomography (T) or computerized tomography (CT). Cross-sectional images have been reported in several studies^{6,8-11} to be more accurate about bone height dimension than panoramic radiography. The main advantages of the T and CT are uniform magnification, the possibility of having a reproducible image, and images that are free from the superimposition of other bone structures.⁶⁻¹¹ In addition, studies have shown higher accuracy and precision of CT imaging in implant planning^{6,8} and in vertical linear measurements.⁹⁻¹¹

In relation to panoramic radiography, over-⁶ or underestimation⁸ of vertical linear measurements can be found. These can be explained by imaging magnification in the horizontal and vertical planes. Also, errors in patient positioning during the radiographic examination can contribute to distortion and magnification leading to incorrect measurements. The other disadvantage in panoramic radiography is the lack of cross-sectional information. This explains the difficulty in the evaluation of thickness and contour of the bone in the recipient site.⁴⁻⁸ Although panoramic imaging limitations are present, this radiographic modality is considered the standard in the initial presurgical radiographic evaluation because is easily available and provides a view of many structures of maxilla and mandible at a low cost.¹² Thus, panoramic or periapical radiographs are also indicated in association with cross-sectional images.

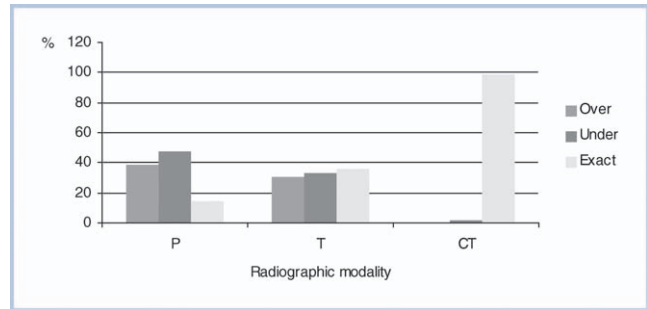


FIGURE. Measurement estimations according to radiographic modalities (P indicates panoramic; T, conventional tomography; CT, computerized tomography).

The aim of this study was to survey the radiographic measurement estimation in assessment of dental implant length according to dentists' confidence.

MATERIALS AND METHODS

At a dental implant meeting, a total of 69 dentists were interviewed by two graduate students (CES and JANDM) previously trained and calibrated in the use of the questionnaire. All the interviewed dentists are familiar with surgical planning for implant treatment.

A 19-point closed-ended questionnaire with single answers was prepared to collect data regarding dentists' opinions about radiographic prescriptions in dental implant assessment.¹² Twelve questions related to over- and underestimated measurements in three radiographic modalities: panoramic radiography (P), T, and CT (Table 1). To be sure that the questions were suitable before the interview began, a pilot study of the questionnaire was performed with a group of dentists that prescribe radiographic examinations for implant site assessment. The database was analyzed by Epi - Info 6.04 software, and the values from two radiographic modalities P and T were compared using a χ^2 test.

The answers to questions 4, 6, 10, 12, 16, and 18 were classified in a dichotomous way with only values "yes" or "no." When the answers were high and medium, the classification was "yes" and for the low and minimal the classification was "no."

RESULTS

The Figure shows the distribution of measurement estimations when different procedures in imaging are used. The use of CT promotes high precision, and we have verified only 1.92% of underestimation in

measurements related to its application. Table 2 shows the comparison between the two types of radiographs (P, T) with high occurrence of over- and underestimation. The association between two radiographic modalities (P and T) and over, under, and exact measurement estimations was statistically significant ($\chi^2 = 6.32$; $P = .0425$).

DISCUSSION

The aim of this study was to survey dentists' confidence related to over- and underestimated measurements in three radiographic modalities concerning dental implant treatment planning.

Functional and aesthetic restoration is the main objective of rehabilitation using dental implants.¹⁻³ Thus, the imaging of potential recipient sites should provide accurate information for precise placement of implants in correct three-dimensional position.⁷ Our study showed that CT is the most precise imaging examination reported by the interviewed dentists. Only one dentist answered about the occurrence of underestimated measurements. This result is in accordance with several studies^{6,8-11} that showed the high precision of measurements in preoperative assessment using CT images because cross-sectional images exhibit uniform magnification.⁷

However, the frequency of cross-sectional imaging prescription related by interviewed dentists is low. Sakakura et al (2003)¹² showed that the majority of the dentists prescribed panoramic radiographs alone (63.8%) or associated with other radiographic methods (28.9%). Beason and Brooks¹³ also found similar results—more than 95% of the dentists took panoramic radiographs on at least 80% of their patients.

In relation to T examination, the occurrence of over- and underestimation measurements was higher than CT in preoperative assessment. Factors related to the acquisition of images, such as blurring of the image or movement of the patient during the examination and the difficulty of the dentists' radiographic interpretation, can explain the occurrence of over- and underestimated measurements.^{7,11} The comparison between the frequency of over- and underestimated measurements in T was lower than in P. That phenomenon can be explained by the presence of cross-sectional imaging in T. However, our results showed that interviewed dentists have prescribed less conventional tomography than P, probably because they are unfamiliar with this radiographic modality in dental implant assessment (Table 2).

Panoramic radiographs presented the highest

frequencies of over- and underestimation, 38.24% and 47.06%, respectively, in the preoperative radiography examination reported by the interviewed dentists. This fact can be explained by the presence of different levels of magnification and distortion related to anatomical regions and lack of cross-sectional images.^{6-8,10} Also, panoramic radiography presents a bidimensional image with no other information about buccal-lingual thickness. In this case, the installation of the implant with planned size cannot be possible.¹ The image magnification and the low reproducibility of alveolar canal diagnosis can increase the risks of anatomical structure damage to the inferior alveolar nerve.^{4-8,14}

On the basis of our implant surgery experience, we speculate that dentists correct the P image magnification in 25% by using the template made by the implant manufacturer in the dental implant treatment planning. On the other hand, shorter length implants have been installed in some edentulous jaws because the magnification is not the same as other areas of the jaw. This statement is in agreement with Schropp, Wenzel, and Kostopoulos (2001),¹⁵ which results show that in 67% of implant planned size cases in panoramic plus periapical radiographs were modified at surgery. The direction of the changes after the use of tomography was related to length (longer or shorter) and width (wider or narrower) of the implants.

The results of this study showed that the dentists' knowledge about radiographic measurement estimation in dental implant assessment is in accordance with published papers related to in vitro and clinical studies about over- and underestimated radiographic measurements.

In conclusion, this study has shown that the CT, based on the answers of the interviewed dentists, is the best radiographic modality when considering the measurement estimation in preoperative implant assessment.

TABLE 2
Distribution of frequency and percentage of measurement estimations according to two types of radiography (P indicates panoramic; T, conventional tomography)*

Type	Over		Under		Exact		Total	
	n	(%)	n	(%)	n	(%)	n	(%)
P	26	38.24	32	47.06	10	14.71	68	100.00
T	11	30.56	12	33.33	13	36.11	36	100.00
Total	37		44		23		104	100.00

* $\chi^2 = 6.32$; $P = .0425$.

ACKNOWLEDGMENT

The authors greatly appreciate the assistance of Mrs. Kim Kubitzka in the editing of the English version.

REFERENCES

1. Adell R, Lekholm U, Rockler B, Branemark PI. A 15-year study of osseointegrated implants in the treatment of the edentulous jaw. *Int J Oral Surg.* 1981;10:387–416.
2. Albrektsson T. A multicenter report on osseointegrated oral implants. *J Prosthet Dent.* 1988;60:75–84.
3. Andersson B, Odman P, Lindvall AM, Branemark PI. Five-year prospective study of prosthodontic and surgical single-tooth implant treatment in general practices and at a specialist clinic. *Int J Prosthodont.* 1998;11:351–355.
4. Stella JP, Tharanon W. A precise radiographic method to determine the location of the inferior alveolar canal in the posterior edentulous mandible: implications for dental implants. Part I: technique. *Int J Oral Maxillofac Implants.* 1990;5:15–22.
5. Klinge B, Petersson A, Malay P. Location of the mandibular canal: comparison of macroscopic findings, conventional radiography and computed tomography. *Int J Oral Maxillofac Implants.* 1989;4:327–332.
6. Bou Serhal C, Jacobs R, Flygare L, Quirynen M, van Steenberghe D. Perioperative validation of localisation of the mental foramen. *Dentomaxillofac Radiol.* 2002;31:39–43.
7. Tyndall DA, Brooks SL. Selection criteria for dental implant site imaging: a position paper of the American Academy of Oral and Maxillofacial Radiology. *Oral Surg Oral Med Oral Pathol Oral Radiol Endod.* 2000;89:630–637.
8. Reddy MS, Mayfield-Donahoo T, Vanderven FJ, Jeffcoat MK. A comparison of the diagnostic advantages of panoramic radiography and computed tomography scanning for placement of root form dental implants. *Clin Oral Implants Res.* 1994;5:229–238.
9. Lindh C, Petersson A, Klinge B. Measurements of distances related to the mandibular canal in radiographs. *Clin Oral Impl Res.* 1995;6:96–103.
10. Bolin A, Eliasson S, von Beetzen M, Jansson L. Radiographic evaluation of mandibular posterior implant sites: correlation between panoramic and tomographic determinations. *Clin Oral Impl Res.* 1996;7:354–359.
11. Kassebaum DK, Nummikoski PV, Triplett RG, Langlais RP. Cross-sectional radiography for implant site assessment. *Oral Surg Oral Med Oral Pathol.* 1990;70:674–678.
12. Sakakura CE, Morais JA, Loffredo LC, Scaf G. A survey of radiographic prescription in dental implant assessment. *Dentomaxillofac Radiol.* 2003;32:397–400.
13. Beason RC, Brooks SL. Preoperative implant site assessment in Southeast Michigan. [abstract] *J Dent Res.* 2001;80:137.
14. Sakakura CE, Loffredo LC, Scaf G. Diagnostic agreement of conventional and inverted scanned panoramic radiographs in the detection of the mandibular canal and the mental foramen. *J Oral Implantol.* 2004;30:2–6.
15. Schropp L, Wenzel A, Kostopoulos L. Impact of conventional tomography on prediction of the appropriate implant size. *Oral Surg Oral Med Oral Pathol Oral Radiol Endod.* 2001;92:458–463.