

# IMPLANT ZONES OF THE JAWS: IMPLANT LOCATION AND RELATED SUCCESS RATE

Len Tolstunov, DDS

The article demonstrates the factors of importance in the early and late failures of dental implants based on literature review. An implant location is one of many factors that can influence a success or failure of dental implants. The author identifies and describe four alveolar jaw regions—functional implant zones—with unique characteristics of anatomy, blood supply, pattern of bone resorption, bone quality and quantity, need for bone grafting and other supplemental surgical procedures, and a location-related implant success rate. The article discusses predisposing factors that can lead to early implant failures in different jaw zones. An implant location is investigated as one of these factors. A prior history of trauma to premaxillary region is described in the context of implant success in anterior maxilla. This zone is being referred by the author as the “traumatic zone.” The challenges of mandibular posterior implant reconstruction are presented in the context of blood supply to the mandible. A deficiency of vascularization in this region, especially in elderly and edentulous patients, lead the author to refer to this zone as the “ischemic zone.” The concept of relative ischemia of the posterior mandible that can develop with age and tooth loss is discussed. A thorough understanding of specifics of each functional implant zone should help to improve successes and prevent failures of dental implants.

**Key Words:** implant success, implant failure, jaw zones, jaw trauma, vascularization, ischemia, implant location

## INTRODUCTION

There are two commonly used periods to assess an implant failure that relates to the time when it occurred:<sup>1</sup> (1) early failures or failures during the osseointegration period (usually within the first year after an implant insertion, during the healing period and initial loading), and (2) late failures or failures after the osseointegration period (usually about a year after implant insertion, when an osseointegration process is complete and implant function is established).

On the basis of literature review, the causes of early implant failures during the osseointegration process include poor quality and quantity of bone and soft

tissue,<sup>1–8</sup> patient medical condition,<sup>2,6,8–10</sup> unfavorable patient habits (bruxism, heavy long-term smoking, poor oral hygiene, others),<sup>3,4,6,8,11</sup> inadequate surgical analysis and technique,<sup>3,7–9,11</sup> inadequate prosthetic analysis and technique,<sup>3,7,8,11–13</sup> suboptimal implant design and surface characteristics,<sup>6,9,13</sup> implant position or location,<sup>14</sup> and unknown factors.

This article attempts to further investigate implant location as one of many factors in early success or failure of dental implants during the osseointegration period. Predisposing factors to implant failures in different jaw regions are discussed.

## FUNCTIONAL IMPLANT ZONES

To better analyze implant failures based on the location, it seems prudent to examine the alveolar ridge of both maxilla and mandible as functional implant zones of the jaws. Functional implant zones (FIZ) are the alveolar jaw regions where dental implants can be inserted with or without supplement-

*Len Tolstunov, DDS, is a private practitioner of oral and maxillofacial surgery in San Francisco, Calif., and an assistant clinical professor in the Department of Oral and Maxillofacial Surgery, University of the Pacific School of Dentistry, San Francisco, Calif. Address correspondence to Dr. Tolstunov at 1 Daniel Burnham Court, Suite 366C, San Francisco, CA 94109 (e-mail: info@SForsurgeon.com)*

tal surgical procedures for the purpose of functional prosthetic rehabilitation of the stomatognathic system. Four functional implant zones are identified in this article: FIZ-1, FIZ-2, FIZ-3, and FIZ-4.

Zone 1 (FIZ-1), otherwise known as the traumatic zone, is a zone of the alveolar ridge of premaxilla, including eight anterior teeth: 4 incisors, 2 canines, and 2 first premolars. In addition to 6 anterior teeth, 2 first premolars are added to this group due to their solid bone support in front of maxillary sinuses. There are certain unifying features of replacement of missing tooth or teeth with implants in this zone. It often relates to the history of trauma to this region and will be discussed further.

Zone 2 (FIZ-2), otherwise known as the sinus zone, is a bilateral zone of the alveolar ridge of posterior maxilla located at the base of maxillary sinus from the second premolar to pterygoid plates. There are certain common features of replacement of missing tooth or teeth (2 premolars and 1 or 2 molars) with dental implants in this zone. It often relates to the degree of sinus pneumatization and vertical bone deficiency that may require supplemental surgical procedures in the subantral area in order to place endosseous implants.

Zone 3 (FIZ-3), otherwise known as the interforaminal zone, is a zone of the alveolar ridge of anterior mandible (symphyseal area), including 8 front teeth: 4 incisors, 2 canines, and 2 first premolars. In addition to 6 anterior teeth, 2 first premolars are added to this group due to being, in a majority of the cases, the last teeth in front of the mental foramen and the inferior alveolar canal bilaterally. There are certain common features of replacement of a missing tooth or teeth with implants in this zone that will be discussed further. This area is routinely utilized as a donor site for the chin (symphyseal) block bone graft.

Zone 4 (FIZ-4), otherwise known as the ischemic zone, is a bilateral zone of the alveolar ridge of posterior mandible from the second premolar to the retromolar pad. The mental foramen in front and the inferior alveolar canal below limit this functional implant zone. An implant's success in this area relates to the quality (density) of bone and quantity of preserved alveolar ridge, among other factors. The blood supply to this region is also an important parameter for success of implant osseointegration. The ramus block bone graft is often harvested in the proximity of this zone.

Although implant zones primarily involve the alveolar process of the jaws, in extreme cases of severe alveolar ridge atrophy to the basal bone, the FIZs can also include the basal bone, if an adequate oral prosthetic and occlusal implant rehabilitation of

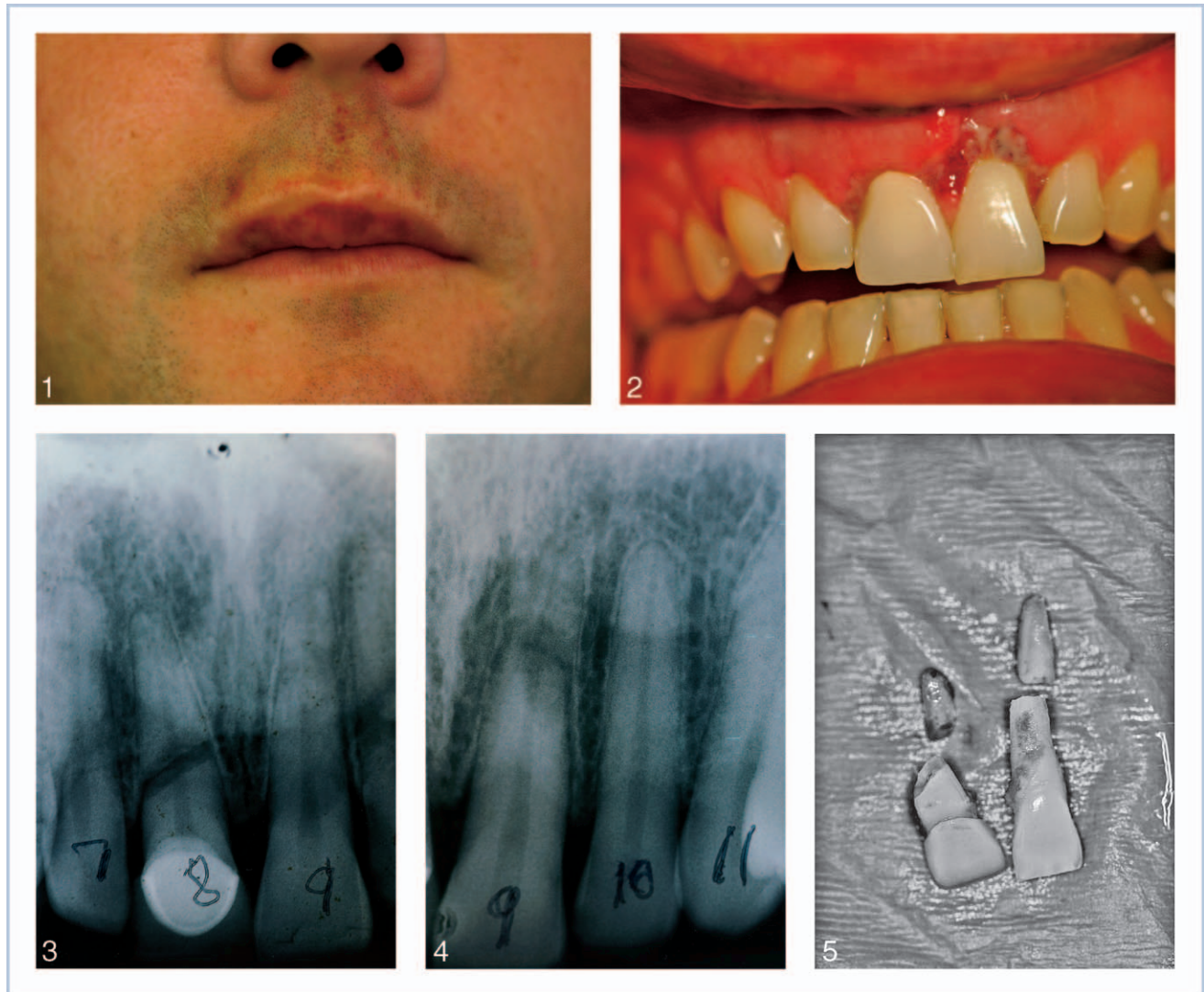the patient can be accomplished. This article will describe each functional implant zone in more detail, emphasizing Zones 1 and 4.

#### TRAUMATIC ZONE: FUNCTIONAL IMPLANT ZONE 1

Part of the anterior maxilla is a protruding alveolar process with thin labial and thick palatal cortical plates covering and protecting upper front teeth. A prominent position of anterior maxilla and upper front teeth in the face is responsible for bone and soft-tissue injuries of the facial skeleton in children and adults.<sup>15</sup> Direct trauma to both teeth and alveolar process often happens during falls (especially to children and the elderly), in motor-vehicle accidents, and in cases of domestic trauma. Fracture of crowns and roots, subluxation, and displacement and avulsion of teeth with associated soft tissue concussion are frequent in this zone (Figures 1 through 5). The most common reported dental injury is subluxation.<sup>15</sup> The complete avulsion of an intact tooth from its socket is also frequent. A thin buccal cortex (sometimes measuring to less than 1 mm) predisposes it to more severe forms of these injuries (Figure 6).

A comminuted nature of traumatic injuries to the premaxilla that may cause a vascular compromise of small-detached bone segments can lead to a three-dimensional bone loss over time. The main blood supply to anterior maxilla that can be damaged derives from the branches of the maxillary artery: the anterior superior alveolar artery (from the infraorbital artery), the greater palatine artery, and the nasopalatine artery. A middle superior alveolar artery is occasionally described as a branch of the infraorbital artery that supplies the region of the canine tooth. The anterior and middle superior alveolar arteries anastomose with the posterior superior alveolar artery to form an arterial network feeding both endosteal and periodontal plexuses.

Another traumatic event in the life of the alveolar ridge is a tooth loss. A tooth extraction due to caries, root resorption, or periodontal disease without the history of traumatic assault typically also leads to bone resorption. A combination of both factors, a history of trauma to the midfacial region and the periodontal or endodontal dental consequences that occur with time (internal or external root resorption, periapical lesion, marginal bone loss, etc.) that eventually lead to the tooth loss, cause the most advanced cases of bone resorption in the anterior maxillary region. A history of surgical endodontic procedures (apicoectomies) and bone and soft tissue scarring add to the complexity of an implant treatment in this area years later.



FIGURES 1-5. During an assault, a 35-year-old man sustained blunt trauma to soft tissue of the upper lip, nose, and premaxilla. Periapical radiographs of two upper central incisors show root fractures: No. 8, mid root fracture; No. 9, apical third root fracture. The alveolar process was intact. Teeth and fractured root fragments were removed atraumatically in anticipation of delayed implant placement.

The healing process following extraction of the tooth (nontraumatic origin) or avulsion of the tooth (traumatic origin) often leads to varying degrees of alveolar ridge atrophy. The progression of healing after a tooth extraction goes through certain resorptive stages of fibrin clot organization (first 4 weeks), immature (woven) bone formation (4–8 weeks), mature (lamellar) bone development (8–12 weeks), and bone stabilization stage (12–16 weeks or about 4 months).<sup>16–18</sup> Postextraction bone resorption is always three-dimensional, with the greatest loss of bone in the bucco-palatal or horizontal direction (the width) and occurring mainly on the buccal side of the alveolar ridge.<sup>18</sup> Schropp et al<sup>19</sup> reported that two-

thirds of the horizontal bone loss occurs within 3 months and one-third takes place within the remaining 9 months of the first year postextraction. A mean reduction of the width of the ridge has been reported to be 5 to 7 mm within a 6-month period<sup>19–22</sup> or 50% during the 12 months following tooth extraction.<sup>19</sup> The loss of bone height is smaller, reported to be about 1 mm within the first 6 months postextraction<sup>19,22</sup> (Table 1).

These data of healing and remodeling of the alveolar crest after the tooth loss are especially important in the premaxillary area due to esthetic considerations. Implant rehabilitation in these cases often entails staged hard and soft tissue procedures to rebuild

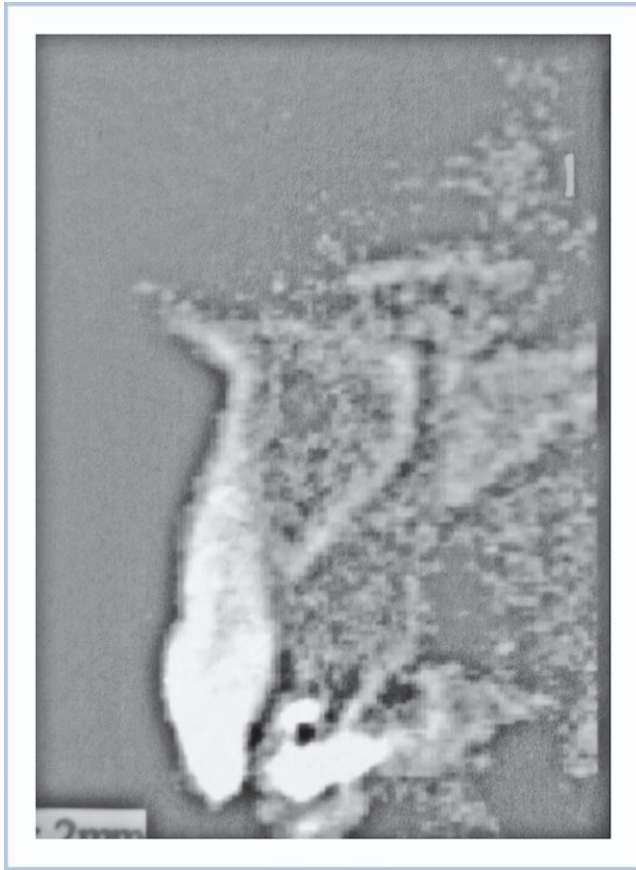


FIGURE 6. Dental tomographic sagittal image depicting frequent position of the maxillary central incisor in the alveolar process: thin (almost disappearing) labial cortical plate (“denuded” appearance of the tooth) and thick palatal bone.

collapsed tissue and achieve the original and natural esthetics, function, and phonetics.

If a bone grafting and implant treatment approach is not considered soon after trauma, the atrophy of the alveolar process of anterior maxilla continues with time. Resorption of the buccal plate compromises the

anatomy of the edentulous alveolar ridge and makes it difficult to place an implant in the prosthetically favorable position.<sup>23</sup> Even when a dental implant is placed, its strength is diminished without the presence of a buccal cortical plate. Using a two-dimensional finite-element model for stress analysis, Clelland and associates<sup>24</sup> demonstrated low stresses and high strains surrounded the implant for the all-cancellous (lack of cortical plate) bone model. When a layer of thick cortical bone was added to the model, it had a significant impact and improved stresses and strains on the implant.

A frequent history of trauma with a posttraumatic buccal bone resorption, among other factors, seems to be a significant event that leads to difficulties of implant treatment and possibly contributes to early implant failures in this zone. That’s why we prefer to call this region a “traumatic zone.”

Surgical and restorative implant practitioners who contemplate an implant treatment in the anterior maxilla should at least consider the following 10 dynamics:

- A detailed history of facial trauma or a tooth loss.
- A comprehensive clinical and radiographic examination of present surgical anatomy, including conventional (PA, occlusal, panoramic x-rays) and tomographic imaging, to accurately evaluate deficiency of hard and soft tissue structures.
- Consider early bone augmentation procedures, like onlay block bone graft, ridge-splitting procedure, distraction osteogenesis, and particulate bone grafting techniques to improve and reconstruct missing or deficient alveolar ridge and create an adequate foundation for an endosseous implant.
- Consider soft tissue grafting to increase or create a layer of attached gingiva, treat all patients as though they have a high smile line.
- Consider slightly more palatal implant placement to

TABLE 1

Timetable of the healing process following tooth extraction

Posttooth extraction	0 to 4 weeks (1 month)	4 to 8 weeks (2 months)	8 to 12 weeks (3 months)	12 to 16 weeks (4 months)	5 to 6 months to 1 year
Healing process	Fibrin clot organization	Woven bone formation	Lamellar bone formation	Bone stabilization stage	Residual remodeling process
Alveolar width reduction (mean)	Two thirds of horizontal bone loss		One third of horizontal bone loss		
Alveolar width reduction in mm (mean)	5 to 7 mm		Bone resorption continues		
Alveolar bone height reduction in mm	1 mm		Bone resorption continues		

engage the remaining palatal cortex with its strength needed for primary implant stability without compromising esthetics and function (it will also preserve thin buccal plate from early resorption); minimize flap extension to preserve blood supply; use precise surgical stent.

- Consider use of an anatomically tapered implant design with a good adaptation to the surrounding socket that can be more kind to the buccal plate. Consider a platform-switching concept that may contribute to a crestal bone preservation, as well as modern osteoconductive implant surface technology (roughened surface, like acid-etched or RBM, others) that can improve primary mechanical stability and bone-to-implant contact (BIC), allow an immediate provisional restoration, reduce healing time, and increase implant success rate.
- Consider two-stage surgery and avoid immediate load in many cases.
- If immediate provisionalization is utilized, take the prosthesis out of occlusion, use protective occlusal schemes; consider prosthetic remodeling techniques for an improvement of implant emergence profile.
- Wait sufficient amount of time before fully loading of an implant with a history of alveolar crest grafting (at least 6 months).
- Instruct patient to avoid heavy biting for at least one year after delivery of the final prosthesis, avoid any front facial trauma or contact sport, and maintain meticulous oral hygiene.

#### **SINUS ZONE: FUNCTIONAL IMPLANT ZONE 2**

This bilateral maxillary posterior zone that extends from the second premolar to the pterygoid plates is located at the base of maxillary sinuses (antra of Highmore). Embryologically, the hard palate and the alveolar process of maxilla form the barrier between the maxillary sinus and the oral cavity. The bone height between the floor of the maxillary sinus and the alveolar crest is routinely analyzed in oral implantology when posterior maxillary implants are contemplated. An increase of sinus volume or sinus pneumatization after a loss of posterior tooth/teeth often necessitates vertical bone augmentation with a sinus lift procedure if dental implants are considered in this area. The bone of this region is also known to have compromised bone quality (types 3 and 4) that can increase an implant failure rate. The main blood supply to posterior maxilla derives from the posterior superior alveolar artery, the greater and lesser palatine arteries (all from the maxillary artery), the ascending

pharyngeal branch of the external carotid artery, and the ascending palatine branch of the facial artery. An injury to the posterior superior alveolar artery during the lateral approach for subantral augmentation can cause hemorrhage that may require coagulation.

#### **INTERFORAMINAL ZONE: FUNCTIONAL IMPLANT ZONE 3**

This zone of mandibular alveolar ridge is located between mental foramen on each side or from the first premolar tooth on one side to the first premolar tooth on the other side. A thin alveolar process in this area necessitates implants of a narrow-to-standard diameter (3–4 mm). A narrow alveolar ridge often requires an especially careful and skilled surgical implant insertion. Based on many case reports, a penetration of the thin lingual mandibular cortex during an implant insertion in this area on occasion can lead to serious bleeding with formation of expanding sublingual hematomas.<sup>25–33</sup> Hemorrhage from a branch of the sublingual artery (a branch of the lingual artery), the submental artery (from the facial artery), or the mylohyoid artery (from the inferior alveolar artery, a branch of the maxillary artery) or their anastomoses can in some cases cause a life-threatening airway compromise.<sup>28,31</sup> Tepper et al<sup>30</sup> demonstrated the presence of at least one (sometimes multiple) lingual perforating vascular bone canal and suggested a routine CT examination prior to an implant procedure in this area. A similar report of serious hemorrhage from an implant insertion in the first mandibular premolar position<sup>25</sup> also suggests a common arterial supply of all 8 mandibular front teeth and one more reason for including first premolars in this zone.

A successful placement of 2 to 6 implants in this zone in many edentulous arch cases offer a stable foundation for a variety of implant-retained and implant-supported removable and fixed mandibular prostheses. A symphyseal (chin) monocortical block bone graft harvested in this area is often used for the horizontal augmentation of bone in other regions, especially in the traumatic zone of premaxilla (FIZ-1).

#### **ISCHEMIC ZONE: FUNCTIONAL IMPLANT ZONE 4**

This zone of the alveolar process of posterior mandible is located behind the mental foramen on each side and extends from the second premolar to the retromolar pad. Embryologically, this bilateral mandibular alveolar zone develops above the inferior alveolar canal. The alveolar height between the

inferior alveolar canal and the alveolar crest is routinely analyzed in oral implantology when posterior mandibular implants are considered. A heavy masticatory demand during function, especially for people with parafunctional habits, necessitates an insertion of two to three implants into this region for replacement of missing second premolar, first molar, and occasionally the second molar. There are several factors that influence success of endosseous implants in this zone. One of them, not often expressed in the literature, is an arterial blood supply to the region.

**Blood Supply to the Mandible**

The major arterial blood supply to the mandible (the primary source) comes from the inferior alveolar artery (IAA), a branch of the maxillary artery that is a branch of the external carotid artery (ECA). The second source of blood supply, mainly to the distal part of the mandible, comes from anastomoses of the sublingual branch of the lingual artery (from ECA), the submental branch of the facial artery (from ECA), and from the mylohyoid branch of IAA (from the maxillary artery, a branch of ECA). The third source of arterial blood supply, mostly to the basal bone and the proximal part of the mandible, derives from the surrounding muscles (small arteries within attached musculature) and periosteum (musculo-periosteal source). The second and the third sources of mandibular vascularization are the collateral ones (see Tables 2 and 3).

The inferior alveolar artery with its small dental arteries is responsible for the endosteal or centrifugal (from inside to outside) arterial supply to the mandibular dentition and alveolar bone. It seems that the quality and direction of mandibular blood flow depends on four major factors: the presence of teeth, the age of the patient, the degree of resorption of the

alveolar bone, and the presence of systemic disorders.<sup>34,35</sup> Vascularization to the alveolar ridge and teeth diminishes with loss of teeth, in elderly patients, with alveolar crest resorption, and in cases of a partial or complete blockage of the inferior alveolar, maxillary, or external carotid arteries. In elderly patients, this obstruction comes from atherosclerosis of main feeding arteries leading to a decrease of blood flow (with its oxygen and nutrients) to the alveolar process that can possibly cause ischemic bone atrophy.<sup>35</sup> When it happens, arterial flow becomes more periosteal or centripetal (from outside to inside), coming from the periosteum and muscles towards the bone.

When a major source of blood supply to the mandible, IAA, is compromised for different reasons, a network of internal (inferior alveolar) and external (facial, sublingual, submental, mylohyoid) arteries jointly provides vascularization to the anterior and posterior mandible.<sup>36,37</sup> Castelli and coauthors<sup>38</sup> documented that after the interruption of IAA flow, the retrograde or reverse blood flow develops through the formation of the collateral arterial conduit of the submental, sublingual, and mental arteries.

In another experimental and comparative study of blood supply to the mandible,<sup>39</sup> Saka et al came to the conclusion that three different types of blood supply are evident in the mandibular cortex in both minipigs and man. In the cranial part of the mandible (including condyle), the endosteal blood supply prevails; in the caudal part of the mandible (the body), the periosteal blood supply predominates; and in the central section (angle and ascending ramus) the patterns are in balance. Also, if a central vascularization through the IAA (internal) is predominant in the centromedullary area of the mandible, the periosteal (external) vascularization is prevalent in the cortical bone.<sup>34</sup>

TABLE 2

Blood supply to anterior mandible\*

Anterior mandible	Basal bone (symphysis) sources of blood supply	Alveolar process Zone 3 (FIZ-3) sources of blood supply
Young with functional dentition	Musculo- periosteal (predominant)‡ SSM branches	IAA and its branch-incisive artery (predominant) SSM Musculo- periosteal (minor)
Elderly and edentuloust	Musculo- periosteal (predominant) SSM	SSM Musculo- periosteal

\*IAA indicates the inferior alveolar artery; SSM refers to anastomoses of the sublingual (from the lingual artery), the submental (from the facial artery), and the mylohyoid (from IAA, a branch of the maxillary artery) branches (all branches of the external carotid artery).

†Elderly patients often develop a partial or complete IAA, maxillary, or ECA obstruction due to atherosclerosis. Edentulous patients often demonstrate a different degree of alveolar bone resorption.

‡Musculo-  
periosteal blood supply refers to small arteries within attached musculature of masseter, medial pterygoid muscles, and mentalis, plus the periosteal network feeding mostly the cortical bone.

TABLE 3

## Blood supply to posterior mandible\*

Posterior mandible	Basal bone (body and ramus) sources of blood supply	Alveolar process Zone 4 (FIZ-4) sources of blood supply
Young with functional dentition	Musculoperiosteal†	IAA (predominant) Musculoperiosteal (minor)
Elderly and edentulous‡	Musculoperiosteal	Musculoperiosteal IAA and SSM branches; shared, depends on patency of central blood supply (zone of relative ischemia)

\*IAA indicates the inferior alveolar artery; SSM refers to anastomoses of the sublingual (from the lingual artery), the submental (from the facial artery), and the mylohyoid (from IAA, a branch of the maxillary artery) branches (all branches of the external carotid artery).

†Elderly patients often develop a partial or complete IAA, maxillary, or ECA obstruction due to atherosclerosis. Edentulous patients often demonstrate a different degree of alveolar bone resorption.

‡Musculoperiosteal blood supply refers to small arteries within attached musculature of masseter, medial pterygoid muscles, and mentalis, plus the periosteal network feeding mostly the cortical bone.

### Concept of Relative Ischemia of the Posterior Mandible

In many cases, due to presence of abounded collateral anastomoses of endosteal and periosteal arterial network, mandibular ischemia is rare. When the central blood supply is compromised (especially, in elderly and edentulous patients), the posterior mandible depends mostly on the musculo-periosteal small arteries from the attached muscles and the periosteal membrane. A violation of this collateral source of arterial supply during surgical procedures on posterior mandible and ramus due to a poor surgical technique may cause an ischemic condition that can affect the bone and soft tissue healing in the area. A process of osseointegration of dental implants (bone healing) placed in the posterior mandible under these circumstances can be seriously affected. Knowledge of surgical anatomy can help to design the surgical incisions that will spare the conduits of arterial blood supply and thus prevent potentially dangerous complications of ischemic necrosis. This careful surgical approach is especially important in elderly and edentulous patients who often develop an insufficient central or endosteal blood flow and rely mostly on the collateral vascularization. The blood supply to the anterior and posterior mandible, the basal bone, and the alveolar process is summarized in the Tables 2 and 3.

There are many times when a clinician may observe the signs and symptoms of delayed healing that occur particularly in the posterior mandible (body, ramus). These clinical situations include an odontogenic chronic osteomyelitis commonly seen in the posterior mandible,<sup>40</sup> an osteoradionecrosis following tooth extraction after radiation therapy for a head and neck cancer,<sup>41,42</sup> a chronic pericoronitis prior to and acute alveolar osteitis (dry socket) after the extraction of mandibular third molars,<sup>43</sup> marginal results of GBR

and a bone graft vascularization prior to implant insertion,<sup>44</sup> poor bone fill around ailing implants (GBR) for peri-implantitis,<sup>45</sup> an equivocal result of the lower third molar socket grafting,<sup>46</sup> among others. Bras et al,<sup>42</sup> studying osteoradionecrosis of the mandible, noticed that the most vulnerable part of the mandible is the buccal cortex of the premolar, molar, and retromolar regions.

These chronic clinical conditions (and many others) of poor or delayed healing in the posterior mandible are likely caused, among other factors, by the decreased vascularization to the area. It seems practical then to call the compromised vascular state of a tissue or an organ a "relative ischemia" due to a possibility of worsening to a complete (absolute) ischemia if, for example, the operative principles are not followed during many surgical procedures on the posterior mandible, ramus, and condyle. That's why it also appears logical to call the mandibular region of the jaws behind the mental foramen (from the second premolar area) an ischemic zone.

In summary, 5 main dynamics can be described in relations to the blood supply of the posterior mandible: (1) the arterial blood supply in this functional zone appears to be essentially periosteal (centripetal) in origin and depends mainly on the external musculo-periosteal source, (2) with age the atherosclerotic obstruction of IAA, maxillary, or ECA may cause deficiency of an overall vascularization that may be partially responsible for bone atrophy in this region, (3) it can be postulated that a loss of posterior mandibular teeth and a resulting alveolar ridge resorption from a lack of function may lead to a degree of central arterial pull back, (4) combination of age- and tooth loss-related arterial insufficiency may cause a relative ischemia of posterior mandible and its alveolar process, (5) decrease of blood supply to the

bone and soft tissue can compromise bone growth, repair, and maintenance and may increase failures of bone grafting and implant integration, amplifying rate of early implant failures in this zone.

**IMPLANT-RELATED COMPARISON OF FUNCTIONAL IMPLANT ZONES**

Zone 1 (anterior maxilla) and Zone 3 (anterior mandible) often show horizontal bone deficiency requiring an alveolar width correction with different bone augmentation procedures such as monocortical bone blocks. Zone 2 (posterior maxilla) and Zone 4 (posterior mandible) often display vertical bone deficiency necessitating an alveolar height improvement through a variety of bone augmentation methods, such as subantral bone augmentation and distraction osteogenesis.

An implant treatment in the anterior maxilla (Traumatic Zone) and posterior mandible (Ischemic Zone) can be potentially challenging for many clinicians for different reasons. For the functional implant Zone 1, these reasons seem to point to frequent history of trauma to anterior teeth and supporting alveolar ridge at an early age with resultant three-dimensional bone and a soft tissue collapse and scarring. For the functional implant Zone 4, these difficulties are usually observed in the area of vertical bone deficiency, proximity to the inferior alveolar canal, and insufficiency of the arterial blood flow and related poor wound healing. In both regions, these factors can contribute to failure of dental implants. Table 4 demonstrates the comparison of Traumatic and Ischemic zones of the jaws and related bone grafting and implant treatment challenges.

Among many other factors, innovative implant designs (platform-switching concept for a crestal bone preservation, others) and osteoconductive roughened implant surface topography (acid-etched, RBM, others) can significantly improve an implant success rate in any zone of the jaws by enhancing primary mechanical implant stability and BIC, allowing an immediate

provisional restoration and, in some cases, an immediate load, reducing healing time, maintaining a crestal bone level, and facilitating an implant hygiene.

**IMPLANT LOCATION AND SUCCESS OF DENTAL IMPLANTS: LITERATURE REVIEW**

There are few literature reports that attempt to study implant location, among a multitude of other factors, to determine its influence on the success or failure of dental implant treatment. Becker et al<sup>47</sup> in a prospective study evaluated 282 implants placed in the maxillary and mandibular molar positions. The 6-year cumulative success rate (CSR) for maxillary posterior implants was 82.9%, for mandibular posterior, 91.5%. He concluded that CSR in the posterior regions is lower than usually reported for anterior regions of the maxilla and mandible due to differences in bone quality and quantity. Eckert et al<sup>48</sup> in a retrospective study assessed 1170 endosseous implants placed in partially edentulous jaws: anterior maxilla, posterior maxilla, anterior mandible, and posterior mandible. In his report, location of implants did not appear to have any effect on implant survival, implant fracture rates, screw loosening, or screw fracture. Parein et al<sup>49</sup> in a long-term retrospective study analyzed 392 consecutively placed Branemark implants that were inserted in 152 partially edentulous posterior mandibles and restored with 56 crown and 168 bridge restorations. The CSR of all implants in the posterior mandible was 89.0% at 6 years. Fewer complications were found in implant prostheses located exclusively in the premolar region versus molar and mixed molar-premolar implant restorations. Drago<sup>14</sup> investigated the location-related osseointegration of 673 implants placed in 169 patients that were observed from 7 months to 8 years following occlusal loading. An implant osseointegration was 89.1% in the anterior maxilla, 71.4% in the posterior maxilla, 96.7% in the anterior mandible, and 98.7% in the posterior mandible. Moy et al,<sup>50</sup> analyzing implant failure rates and associated risk

TABLE 4

Comparison of two functional implant zones and related bone grafting and implant treatment challenges

Comparison of functional implant zones (FIZ) 1 and 4	Zone	Local challenge (common occurrence)	Alveolar ridge collapse	Pattern of bone atrophy	Implant insertion	Bone grafting	Main challenges of implant treatment
Anterior maxilla (FIZ-1)	Traumatic zone	History of trauma	Horizontal collapse of bone	Resorption of buccal cortical plate	Parallel to the buccal cortex	To improve width	Osseointegration, esthetics
Posterior mandible (FIZ-4)	Ischemic zone	Poor blood supply	Vertical collapse of bone	Resorption of medullary bone	Perpendicular to the alveolar crest	To improve height	Osseointegration, function



TABLE 5  
Dental implant success–failure analysis based on implant location: literature review of 6 reports

Author	Anterior maxilla (%)	Posterior maxilla (%)	Anterior mandible (%)	Posterior mandible (%)
Becker	NA	82.8	NA	91.5
Eckert	No difference	No difference	No difference	No difference
Parein	NA	NA	NA	89.0
Drago	89.1	71.4	96.7	98.7
Moy	← 91.8 →	← 91.8 →	← 95.1 →	← 95.1 →
Bass	← 93.4 →	← 93.4 →	← 97.2 →	← 97.2 →
Average cumulative success rate	89	77	97	93

factors, observed implant failure of 8.16% in the maxilla and 4.93% in the mandible. Increased age (over 60) was strongly associated with the risk of implant failure. Bass et al,<sup>51</sup> evaluating 303 patients with 1097 implants over 3-year period, assessed the success rate of implants in the maxilla at 93.4% and 97.2% in the mandible. Poor bone quality played the major role in implant failure rate with bone quantity demonstrating less importance. The summary of these reports is illustrated in the Table 5.

All presented reports appear to agree that the CSR of dental implants is generally high and that implant location plays an important role in implant success. CSR of implants in the mandible seems to be slightly higher than in maxilla—about a 4% difference. The success rate of implants in the anterior regions seems to be higher than in the posterior regions of the jaws, mostly due to the quality of bone: about 12% difference between anterior maxilla and posterior maxilla, and about 4% difference between anterior mandible and posterior mandible. On the basis of reviewed literature reports, an implant treatment in the anterior mandible appears to be the most successful. The posterior maxilla appears to be the least successful region of the jaws for implant rehabilitation.

### CONCLUSION

An overwhelming clinical experience and literature data confirm that dental implant reconstruction is a very successful treatment modality that can be offered to our patients with missing or failing teeth. Like with any medical, surgical, or dental treatment there are always risks and benefits of any treatment and no procedure is foolproof. The fact that implants are not successful in a small percentage of cases challenges dental researchers and clinicians to investigate risks associated with failures. Among many other factors, implant location appears to be a significant factor in a success-failure analysis of dental implants. It seems to indicate that dental implant success in the particular

zone of the jaws is influenced by a combination of factors that include a quality and quantity of bone, history of trauma to the region, proximity of important structures (sinus, IAN, etc.), need for bone grafting and other supplemental surgical procedures, degree of arterial blood supply, and rate of tissue healing. Knowledge of specifics of each functional implant zone can help implant practitioners to reduce occasional failures of this otherwise very successful dental treatment.

### REFERENCES

1. Tolstunov L. Dental implant success-failure analysis: a concept of implant vulnerability. *Implant Dent.* 2006;15(4):341–346.
2. Albrektsson T, Lekholm U. Osseointegration: current state of the art. *Dent Clin North Am.* 1989;33(4):537–554.
3. El Askary AS, Meffert RM, Griffin T. Why do dental implants fail? Part II. *Implant Dent.* 1999;8(3):265–277.
4. Lemmerman KJ, Lemmerman NE. Osseointegrated dental implants in private practice: a long-term case series study. *J Periodontol.* 2005;76(2):310–319.
5. Iezzi G, Degidi M, Scarano A, et al. Bone response to submerged, unloaded implants inserted in poor bone sites: a histological and histomorphometrical study of 8 titanium implants retrieved from man. *J Oral Implantol.* 2005;31(5):225–233.
6. Rosenberg ES, Cho SC, Elian N, et al. A comparison of characteristics of implant failure and survival in periodontally compromised and periodontally healthy patients: a clinical report. *Int J Oral Maxillofac Implants.* 2004;19(6):873–879.
7. Degidi M, Piattelli A. 7-year follow-up of 93 immediately loaded titanium dental implants. *J Oral Implantol.* 2005;31(1):25–31.
8. Kourtis SG, Sotiriadou S, Voliotis S, et al. Private practice results of dental implants. Part I: survival and evaluation of risk factors; Part II: surgical and prosthetic complications. *Implant Dent.* 2004;13(4):373–385.
9. El Askary AS, Meffert RM, Griffin T. Why do dental implants fail? Part I. *Implant Dent.* 1999;8(2):173–185.
10. Ruggiero SL, Mehrotka B, Rosenberg TJ, et al. Osteonecrosis of the jaws associated with the use of bisphosphonates: a review of 63 cases. *J Oral Maxillofac Surg.* 2004;62:527–534.
11. Ashley ET, Covington LL, Bishop BG, et al. Ailing and failing endosseous dental implants: a literature review. *J Contemp Dent Pract.* 2003;4(2):35–50.
12. Kitamura E, Stegaroiu R, Nomura S, et al. Biomechanical aspects of marginal bone resorption around osseointegrated

implants: considerations based on a three-dimensional finite element analysis. *Clin Oral Implants Res.* 2004;15(4):401–412.

13. Steigenda JT, Al-Shammari KF, Nociti FH, et al. Dental implant design and its relationship to long-term implant success. *Implant Dent.* 2003;12(4):306–317.

14. Drago CJ. Rates of osseointegration of dental implants with regard to anatomic location. *J Prosthodont.* 1992;1(1):29–31.

15. Rowe NL, Williams JL, (eds). Localized injuries of the teeth and alveolar process. In: Williams JL, ed. *Maxillofacial Injuries. 2nd edition.* England: Churchill Livingstone; 1994:257–281.

16. Devlin H, Ferguson MW. Alveolar ridge resorption and mandibular atrophy. A review of the role and systemic factors. *Br Dent J.* 1991;170(3):101–104.

17. Pietrokovski J. The bony residual ridge in man. *J Prosthet Dent.* 1975;34(4):456–462.

18. Evian CI, Rosenberg ES, Coslet JG, et al. The osteogenic activity of bone removed from healing extraction sockets in humans. *J Periodontol.* 1982;53(2):81–85.

19. Schropp L, Wenzel A, Kostopoulos L, et al. Bone healing and soft tissue contour changes following single tooth extraction: a clinical and radiographic 12-month prosthetic study. *Int J Periodont Restor Dent.* 2003;23(4):313–323.

20. Pietrokovski J, Masslaer M. Alveolar ridge resorption following tooth extraction. *J Prosthet Dent.* 1967;17(1):21–27.

21. Johnson K. A study of the dimensional changes occurring in the maxilla following tooth extraction. *Aust Dent J.* 1969;14(4):241–244.

22. Saldanha JB, Casati MZ, Neto FH, et al. Smoking may affect the alveolar process dimensions and radiographic bone density in maxillary extraction sites: a prospective study in humans. *J Oral Maxillofac Surg.* 2006;64(9):1359–1365.

23. Nevins M, Camelo M, De Paoli S, et al. A study of the fate of the buccal wall of extraction sockets of teeth with prominent roots. *Int J Periodontics Restorative Dent.* 2006;26(1):19–29.

24. Clelland NL, Lee JK, Bimbenet OC, et al. Use of an axisymmetric finite element method to compare maxillary bone variables for a loaded implant. *J Prosthodont.* 1993;2(3):183–189.

25. Kalpidis CD, Konstantinidis AB. Critical hemorrhage in the floor of the mouth during implant placement in the first mandibular premolar position: a case report. *Implant Dent.* 2005;14(2):117–124.

26. Kalpidis CD, Setayesh RM. Hemorrhaging associated with endosseous implant placement in the anterior mandible: a review of the literature. *J Periodontol.* 2004;75(5):631–645.

27. Isaacson TJ. Sublingual hematoma formation during immediate implant placement of mandibular endosseous implants. *J Am Dent Assoc.* 2004;135(5):566.

28. Flanagan D. Important arterial supply of the mandible, control of an arterial hemorrhage, and report of a hemorrhagic incident. *J Oral Implantol.* 2003;29(4):165–173.

29. Boyes-Varley JG, Lownie JF. Hematoma of the floor of the mouth following implant placement. *SADJ.* 2002;57(7):257.

30. Tepper G, Hofschneider UB, Gahleitner A, et al. Computed tomographic diagnosis and localization of bone canals in the mandibular interforaminal region for prevention of bleeding complications during implant surgery. *Int J Oral Maxillofac Implants.* 2001;16(1):68–72.

31. Givol N, Chaushu G, Halamish-Shani T, et al. Emergency tracheostomy following life-threatening hemorrhage in the floor of the mouth during immediate implant placement in the mandibular canine region. *J Periodontol.* 2000;71(12):1893–1895.

32. Hofschneider U, Tepper G, Gahleitner A, et al. Assessment

of the blood supply to the mental region for reduction of bleeding complications during implant surgery in the interforaminal region. *Int J Oral Maxillofac Implants.* 1999;14(3):379–383.

33. Mordenfeld A, Andersson L, Bergstrom B. Hemorrhage in the floor of the mouth during implant placement in the edentulous mandible: a case report. *Int J Oral Maxillofac Implants.* 1997;12(4):558–561.

34. Chanavaz M. Anatomy and histophysiology of the periosteum: quantification of the periosteal blood supply to the adjacent bone with 85Sr and gamma spectrometry. *J Oral Implantol.* 1995;21(3):214–219.

35. Eiseman B, Johnson LR, Coll JR. Ultrasound measurement of mandibular arterial blood supply: techniques for defining ischemia in the pathogenesis of alveolar ridge atrophy and tooth loss in the elderly. *Oral Maxillofac Surg.* 2005;63:28–35.

36. Bradley JC. A radiological investigation into the age changes of the inferior dental artery. *Br J Oral Surg.* 1975;13:82–90.

37. Bradley JC. Age changes in the vascular supply of the mandible. *Br Dent J.* 1972;132:142–144.

38. Castelli WA, Najlet CE, Diaz-Perez R. Interruption of the arterial inferior alveolar flow and its effect on mandible collateral circulation and distal tissue. *J Dent Res.* 1975;54:708.

39. Saka B, Wree A, Anders L, et al. Experimental and comparative study of the blood supply to the mandibular cortex in Gottingen minipigs and in man. *J Craniomaxillofac Surg.* 2002;30(4):219–225.

40. Sasaki J, Nameta K. Chronic osteomyelitis of mandible. *Nippon Rinsho.* 1994;52(2):507–511.

41. Curri MM, Dib LL. Osteoradionecrosis of the jaws: a retrospective study of the background factors and treatment in 104 cases. *J Oral Maxillofac Surg.* 1997;55(6):540–544.

42. Bras J, de Jonge HK, van Merkesteyn JP. Osteoradionecrosis of the mandible: pathogenesis. *Am J Otolaryngol.* 1990;11(4):244–250.

43. Chiapasco M, De Cicco L, Marrone G. Side effects and complications associated with third molar surgery. *Oral Surg Oral Med Oral Pathol.* 1993;76(4):412–420.

44. Ersanli S, Olgac V, Leblebicioglu B. Histologic analysis of alveolar bone following guided bone regeneration. *J Periodontol.* 2004;75(5):750–756.

45. Zitzman NU, Scharer P, Marinello CP. Factors influencing the success of GBR. Smoking, timing of implant placement, implant location, bone quality and provisional restoration. *J Clin Periodontol.* 1999;26(10):673–682.

46. Dodson TB. Is there a role for reconstructive techniques to prevent periodontal defects after third molar surgery? *J Oral Maxillofac Surg.* 2005;63(7):891–896.

47. Becker W, Becker BE, Alsuwyed A, et al. Long-term evaluation of 282 implants in maxillary and mandibular molar positions: a prospective study. *J Periodontol.* 1999;70(8):896–901.

48. Eckert SE, Wollan PC. Retrospective review of 1170 endosseous implants placed in partially edentulous jaws. *J Prosthet Dent.* 1998;79(4):415–421.

49. Parein AM, Eckert SE, Wollan PC, et al. Implant reconstruction in the posterior mandible: a long-term retrospective study. *J Prosthet Dent.* 1997;78(1):34–42.

50. Moy PK, Medina D, Shetty V, et al. Dental implant failure rates and associated risk factors. *Int J Oral Maxillofac Implants.* 2005;20(4):569–577.

51. Bass SL, Triplett RG. The effect of preoperative resorption and jaw anatomy on implant success: a report of 303 cases. *Clin Oral Implants Res.* 1991;2(4):193–198.