

IMPLANT SUCCESS IN DISTRACTED BONE VERSUS AUTOGENOUS BONE-GRAFTED SITES

Jeffrey A. Elo, DDS, MS; Alan S. Herford, DDS, MD; Philip J. Boyne, DMD, MS, DSc

Endosseous implants are the treatment of choice for restoring function and reconstructing most edentulous areas of the maxilla and mandible. In general, alveolar bone defects can be reconstructed by either distraction osteogenesis or autogenous bone grafting. After alveolar reconstruction, endosseous implants are used to support and retain the prosthesis for restoration of form and function. Eighty-two consecutive patients requiring alveolar augmentation prior to implant placement were evaluated. All patients were given treatment options for reconstructing their alveolar defects, which included autogenous bone grafting vs distraction osteogenesis. Sixty-five patients received autogenous grafts (anterior iliac crest: 44; retromolar: 17; tibia: 2; chin: 2), and 17 patients underwent distraction osteogenesis prior to implant placement. A total of 184 implants were placed in the autogenous bone-grafted sites and 56 implants in the distracted bone sites. Implants placed in sites restored with autogenous bone grafts had an implant success rate of 97% (178/184), whereas implants placed in distracted bone sites had a success rate of 98% (55/56). In the autogenous grafted group, 3 implants failed in the posterior mandible, one in the anterior maxilla, one in the anterior mandible, and one in the posterior maxilla. In the distraction group, one implant failed in the posterior mandible. Both techniques are associated with good success rates. There was no statistical difference between implant success in autogenous bone vs distracted bone sites in this group of patients.

Key Words: distraction osteogenesis, autogenous bone grafts, implants

INTRODUCTION

Endosseous implant placement is the treatment of choice for restoring function and reconstructing edentulous areas of the maxilla and mandible. Alveolar defects can be reconstructed by many techniques including distraction osteogenesis or autogenous bone grafting. After alveolar reconstruction, endosseous implants are used to support and retain the prosthesis for restoration of esthetic form and function. This study compares clinical success when

implants placed are in defects augmented by autogenous grafting, with those placed in distracted bone.

PATIENTS AND METHODS

We retrospectively analyzed the success rates of endosseous implant placement in distracted vs autogenous bone graft reconstruction sites in our patient population at Loma Linda University. Eighty-two consecutive patients requiring alveolar augmentation prior to implant placement were evaluated. All patients were given treatment options for reconstructing their alveolar defects, which included autogenous bone grafting vs distraction osteogenesis. Sixty-five patients received autogenous grafts (anterior iliac crest: 44; retromolar: 17; tibia: 2; chin: 2) (Table 1), and 17 patients underwent distraction osteogenesis prior to implant placement (Table 2). The type of bone graft harvested depended on the characteristics of the

Jeffrey A. Elo, DDS, MS, is assistant clinical professor, Alan S. Herford, DDS, MD, is chair and program director, and Philip J. Boyne, DMD, MS, DSc, is emeritus professor, Department of Oral and Maxillofacial Surgery, Loma Linda University Medical Center. Address correspondence to Dr. Herford at the Department of Oral and Maxillofacial Surgery, Loma Linda University School of Dentistry, 11092 Anderson Street, Loma Linda, CA 92350. (e-mail: aherford@llu.edu)

TABLE 1
Total number of bone grafts*

	Anterior Maxilla	Anterior Mandible	Posterior Maxilla	Posterior Mandible
AICBG	10	11	12	11
RMBG	6	2	4	5
Tibia	1			1
Chin	1		1	

*AICBG indicates anterior iliac crest bone graft; RMBG, retromolar bone graft.

TABLE 3
Total number of implants placed in autogenous bone

	Anterior Maxilla	Anterior Mandible	Posterior Maxilla	Posterior Mandible
AICBG	31	34	37	32
RMBG	18	4	8	12
Tibia	2			2
Chin	2		2	

*AICBG indicates anterior iliac crest bone graft; RMBG, retromolar bone graft.

defect and size of the graft needed. A total of 184 implants were placed in the autogenous bone-grafted sites (Table 3), and 56 implants were placed in the distracted bone sites (Table 4).

All patients were evaluated and analyzed after a minimum of 36 months follow-up (36–61 months) for implant success according to the criteria of Smith and Zarb¹ and Albrektsson et al.² The two groups were compared to determine if any statistical difference could be identified.

RESULTS

Implants placed in sites restored with autogenous bone grafts had an implant success rate of 97% (178/184), whereas implants placed in distracted bone sites had a success rate of 98% (55/56). In the autogenous grafted group, 3 implants failed in the posterior mandible, 1 in the anterior maxilla, 1 in the anterior mandible, and 1 in the posterior maxilla. In the distraction group, 1 implant failed in the posterior mandible.

Utilizing 2-sample binomial testing with the significance level at .05, no statistical difference in success rates between the autogenously grafted and distracted bone sites ($P = .5686$) was seen. With regard to the posterior mandible, no statistical difference in success rates between autogenously grafted and distracted bone ($P = .9282$) was seen.

Both techniques are associated with good success rates. There is no statistical difference between implant success in autogenous bone vs distracted bone graft sites in our patient series.

TABLE 2
Sites of distraction osteogenesis

Anterior Maxilla	Anterior Mandible	Posterior Maxilla	Posterior Mandible
4	5	3	5

TABLE 4
Number of implants placed in distracted bone

Anterior Maxilla	Anterior Mandible	Posterior Maxilla	Posterior Mandible
13	15	11	17

DISCUSSION

Endosseous implants are the treatment of choice for restoring function and reconstructing edentulous areas of the maxilla and mandible. Alveolar bone defects can be reconstructed by either distraction osteogenesis or autogenous bone grafting. After alveolar reconstruction, endosseous implants are placed to regain function.

Bone grafting techniques for alveolar ridge reconstruction prior to dental implant placement are well established. Autogenous bone grafting has many advantages over other techniques, but is not without risks and potential complications, including wound dehiscence, infection, partial or total loss of the bone graft, and donor site morbidity.³ The difficulties that can be encountered with vertical and horizontal ridge augmentation by means of bone grafting techniques are frequently limited to soft tissue tolerances and bone graft resorption.⁴ Alveolar distraction osteogenesis is a surgical technique that encourages creation of new bone and soft tissue through incremental lengthening of osseous segments.⁵

Alveolar distraction offers advantages over traditional bone grafting techniques. An increase in alveolar bone height and concomitant increase in vestibular alveolar mucosa is a result of gradual bone distraction. Minimal periosteal stripping is utilized, as the transport segment is small.

Onlay bone grafting techniques can present difficulties, mainly because of the soft tissue stretch required to cover block or particulate bone grafts. This factor becomes more complex when a scarred tissue bed is present. Wound dehiscence is a potentially

Downloaded from http://meridian.allenpress.com/journal/article-pdf/35/4/181/2035931/1548-1336-35_4_181.pdf by guest on 22 June 2024

serious complication resulting in exposure of the nonvital bone graft to oral microflora and potential infection. When such infection occurs, the result can be partial or total loss of the graft, which necessitates retreatment.⁶

Donor site complications of the ilium³ and tibia⁷ have been reported, including infection, peritonitis, persistent pain, hip or tibia fracture, permanent paresthesias, and permanent gait disturbance. Potential morbidity of cranial donor sites include scalp hematoma, intracranial hemorrhage and brain injury, while for rib donor sites complications may include pneumothorax and persistent chest wall pain.^{8,9} Potential complications associated with intraoral donor sites include pain, bleeding, infection, and temporary or permanent paresthesia or dysesthesia of the teeth, gingiva, lip, and chin.^{4,10}

Distraction osteogenesis also is not without its drawbacks. Adequate osseous volume is necessary for stabilization of the device and successful creation of the distraction regenerate. Devices placed on the outer cortical surface may cause slight buccal resorption of the cortex, requiring a bone graft at the time of device removal. Vector control may be an issue when distracting against the pull of masticatory muscles; however, new alveolar distraction devices incorporate hinges, allowing the surgeon to redirect the vector.^{11,12} Careful follow-up is mandatory during the entire distraction process, including the time of postdistraction ossification. The period of postdistraction ossification is the best time to easily mold the regenerate. Wound dehiscence problems can occur and are managed with local wound care, including antibiotics and antimicrobial mouth rinses. Also, while performing mandibular distraction, the location of the osteotomies is based on the position of the inferior alveolar nerve and the height of bone above the nerve canal.

In our distraction patient population, a 5-day latency period was allowed, and distraction was started on the fifth postoperative day. The latency period is important for resolution of inflammation from surgery. It also allows cellular induction and differentiation of fibroblasts, formation of collagen, and subsequent induction of osteoblasts during the early stages of new bone formation.¹³ The distraction rate for all of our patients was 1 mm/day, performed in 3 activations (KLS Martin, Jacksonville, Fla). It has been reported that the greater the frequency of activation, the more favorable the distraction regenerate.¹⁴ Therefore, patient cooperation becomes an important consideration in distraction osteogenesis.

Adequate consolidation time is required for maturation of the distraction regenerate so that it

can support dental implant placement. Our work on implants in the maxilla of *Papio anubis* baboons demonstrated complete bone repair with or without bone morphogenetic protein 2 after 1½ years of function.¹⁵ The distraction osteogenesis animals had accelerated healing during the first 2 postoperative months. Typically, 3 to 4 months is adequate for consolidation.⁵ In all of our cases, the implants (Nobel Biocare Replace Select, Yorba Linda, Calif) were placed at the time of distraction device removal, which was usually at 4 months. The implants were placed utilizing a 2-stage technique. Primary implant stability was achieved at all implant fixture sites.

Our study shows no statistical difference in success rates between implants placed in autogenous bone-grafted sites vs distracted bone sites. However, a theoretical difference is present. Compared with bone grafting neovascularity, the distraction regenerate has neovascularity that is more resistant to infection¹⁶ than is the case with bone grafting. Also, by utilizing distraction osteogenesis, the surgeon performs less periosteal stripping, which could further compromise the blood supply to the regenerate. Despite these theoretical advantages of distraction osteogenesis, autogenous bone grafting has shown, in our study, to be an equally successful preprosthetic alveolar bone augmentation procedure.

REFERENCES

1. Smith DE, Zarb GA. Criteria for success of osseointegrated endosseous implants. *J Prosthet Dent*. 1989;62:567–572.
2. Albrektsson T, Zarb GA, Worthington P, Eriksson AR. The long-term efficacy of currently used dental implants: a review and proposed criteria for success. *Int J Oral Maxillofac Implants*. 1986;1: 11–25.
3. Cricchio G, Lundgren S. Donor site morbidity in two different approaches to anterior iliac crest bone harvesting. *Clin Implant Dent Relat Res*. 2003;5:161–169.
4. Clavero J, Lundgren S. Ramus or chin grafts for maxillary sinus inlay and local onlay augmentation: comparison of donor site morbidity and complications. *Clin Implant Dent Relat Res*. 2003;5: 154–160.
5. Clarizio L. Vertical alveolar distraction versus bone grafting for implant cases. In: Jensen O, ed. *Alveolar Distraction Osteogenesis*. Chicago: Quintessence Publishing; 2002:59–68.
6. Walker DA. Mandibular distraction osteogenesis for endosseous dental implants. *J Can Dent Assoc*. 2005;71:171–175.
7. Marchena JM, Block MS, Stover JD. Tibial bone harvesting under intravenous sedation: morbidity and patient experiences. *J Oral Maxillofac Surg*. 2002;60:1151–1154.
8. Sawin PD, Traynelis VC, Menezes AH. A comparative analysis of fusion rates and donor-site morbidity for autogenic rib and iliac crest bone grafts in posterior cervical fusions. *J Neurosurg*. 1998;88: 255–265.
9. Bolger WE, McLaughlin K. Cranial bone grafts in cerebrospinal fluid leak and encephalocele repair: a preliminary report. *Am J Rhinol*. 2003;17:153–158.

10. Nkenke E, Radspiel-Troger M, Wiltfang J, Shultze-Mosgau S, Winkler G, Newkam FW. Morbidity of harvesting retromolar bone grafts: a prospective study. *Clin Oral Implants Res.* 2002;13:514-521.

11. Zechner W, Bernhart T, Zauza K, et al. Multi-dimensional osteodistraction for correction of implant malposition in edentulous segments. *Clin Oral Implants Res.* 2001;12:531-538.

12. Stucki-McCormick SU, Moses JJ, Robinson R, et al. Alveolar distraction devices. In: Jensen, ed. *Alveolar Distraction Osteogenesis.* Carol Stream, Ill: Quintessence Publishing Co, Inc; 2002:41-58.

13. Samchukov M, Cope J, Cherkashin A. Biological basis of new bone formation under the influence of tension stress. In: Samchukov M, Cope J, Cherkashin A, eds. *Craniofacial Distraction Osteogenesis.* St Louis, Mo: Mosby; 2001:21-36.

14. Ilizarov GA. The tension stress effect on the genesis and growth of tissues. Part II. The influence of rate and frequency of distraction. *Clin Orthop.* 1989;(239):263-285.

15. Boyne PJ, Herford AS. Effect of long-term implant function on BMP complemented distraction osteogenesis of the edentulous mandible in the Papio anubis baboons. Proceedings of the 4th International Congress on Maxillofacial and Craniofacial Distraction Osteogenesis, (Abstract #S01-16); July 2-5, 2003; Paris, France.

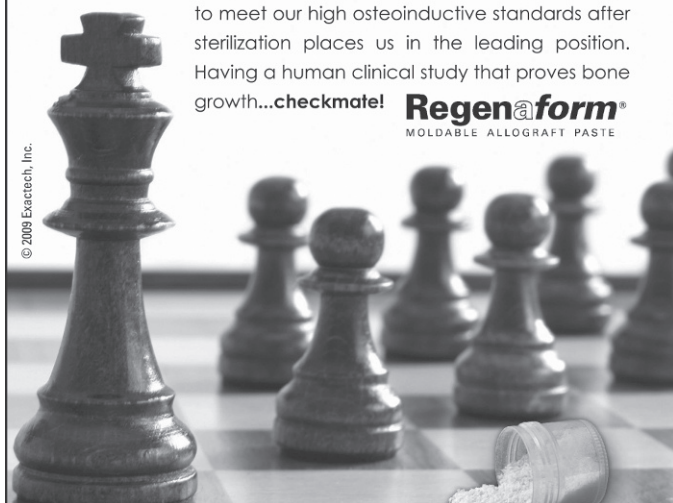16. Walker D. Buried bi-directional telescopic mandibular distraction. In: Samchukov M, Cope J, Cherkashin A, eds. *Craniofacial Distraction Osteogenesis.* St Louis, Mo: Mosby; 2001: 313-322.

Successful Bone Regeneration— Strategy Not Chance

Our *in vivo* testing and carrier technology are two strategic moves for improving patient outcomes. Offering only an optimum DBM concentration that is demonstrated by histology* to meet our high osteoinductive standards after sterilization places us in the leading position. Having a human clinical study that proves bone growth...**checkmate!**

Regen@form[®]
MOLDABLE ALLOGRAFT PASTE

© 2009 Exactech, Inc.



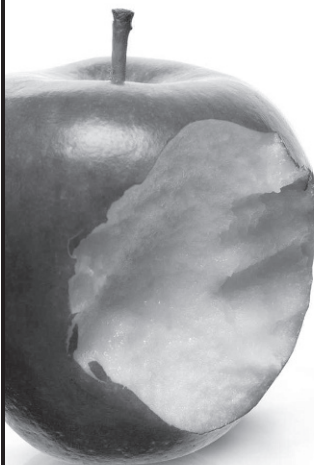
*Each lot of product is tested using the athymic nude rat assay to verify osteoinductive potential.

Regen@form[®] is processed by RTI Biologics, Inc. and distributed by Exactech, Inc.

Exactech[®]
DENTAL BIOLOGICS
www.exac.com/dental

DRILLS LOST THEIR BITE?

Finally a drill-sharpening service
for dental implant providers.



- Superior performance
- Improved care
- Extreme precision
- Exceptional longevity
- Unsurpassed quality
- Lower cost
- Increased ROI

contact@implantdrillpoint.com

ImplantDrillPoint.com