

Neurologic Withdrawal Symptoms Following Abrupt Discontinuation of a Prolonged Dexmedetomidine Infusion in a Child

Jamie L. Miller, PharmD,¹ Christine Allen, MD,² and Peter N. Johnson, PharmD¹

¹Department of Pharmacy, Clinical and Administrative Sciences, University of Oklahoma College of Pharmacy, and

²Department of Pediatrics, Section of Pediatric Critical Care, University of Oklahoma Health Sciences Center, Oklahoma City, Oklahoma

Dexmedetomidine is a α_2 -adrenergic agonist which possesses sedative, analgesic, and anxiolytic properties. It is approved for short-term use in adults to provide sedation while mechanically ventilated and for non-invasive procedural sedation. An increased number of anecdotal reports describe the use dexmedetomidine in children. Cardiovascular withdrawal symptoms have been reported in the literature. However, there have been few published reports of neurologic withdrawal symptoms following discontinuation of prolonged infusions of dexmedetomidine. We describe a 2 year-old child who received a prolonged continuous infusion (263 hours) of dexmedetomidine as an adjunctive sedative agent. Following abrupt discontinuation of dexmedetomidine, the patient presented with symptoms suggestive of neurological withdrawal. The symptoms gradually resolved over two days without further intervention, and the patient had full resolution of symptoms and was discharged home with no further neurologic sequelae.

KEYWORDS children, dexmedetomidine, sedation, withdrawal

J Pediatr Pharmacol Ther 2010;15:38–42

INTRODUCTION

Sedation and analgesia are important considerations for children admitted to the pediatric intensive care unit (PICU). There are numerous

see Editorial on page 4

agents available for sedation and analgesia in this patient population including opioids, benzodiazepines, ketamine, and dexmedetomidine. Dexmedetomidine is an α_2 -adrenergic agonist which possesses sedative, analgesic, and anxiolytic properties. The affinity of dexmedetomidine for the α_2 receptor is approximately 6–8 times that of clonidine.¹ Its highly-selective properties have shown promise as a means

to decrease opioid requirements for adequate sedation and to facilitate extubation because of its minimal effect on respiratory depression. It

ABBREVIATIONS PICU, pediatric intensive care unit; TOF, Tetrology of Fallot; VSD, ventricular septal defect

is approved by the Food and Drug Administration for short-term sedation in intubated adult patients requiring mechanical ventilation and for non-intubated adults undergoing procedural sedation/surgery.²

Limited case reports and studies have evaluated dexmedetomidine use in the pediatric patient population.^{3–11} These reports have described similar adverse effects (e.g., hypotension, hypertension, and bradycardia) to those reported in adults. Although use of dexmedetomidine is recommended only for a short duration (<24 hours) for sedation in patients requiring mechanical ventilation, a few reports describe its efficacy and safety following prolonged use.^{5–6,11} We report a 2-year-old male who received a dexmedetomidine infusion for 11 days (263 hours)

Address correspondence to Peter N. Johnson, PharmD, BCPS, Assistant Professor, Department of Pharmacy: Clinical and Administrative Sciences, University of Oklahoma College of Pharmacy, P.O. Box 26901, Oklahoma City, OK 73117, email: Peter-Johnson@ouhsc.edu
© 2010 Pediatric Pharmacy Advocacy Group

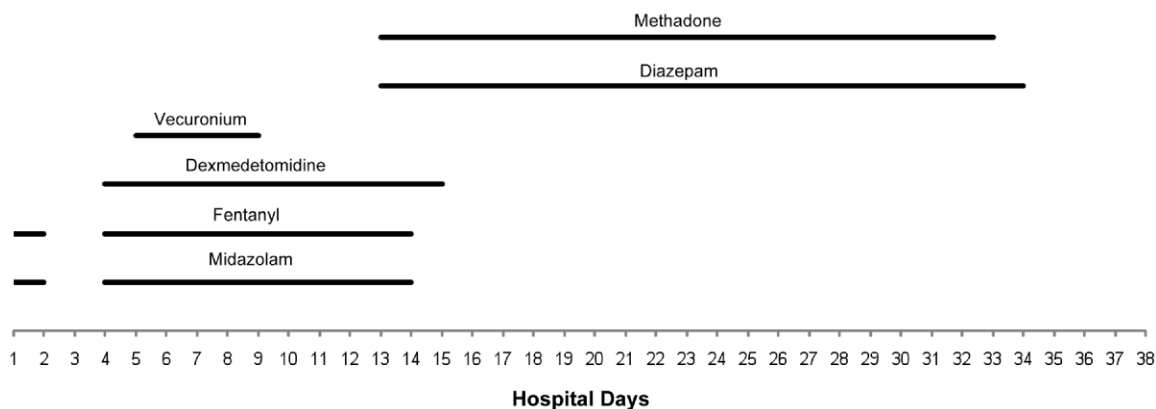


Figure. Overview of Sedation and Analgesic Agents per Hospital Days

and developed possible withdrawal symptoms following abrupt discontinuation of therapy.

CASE REPORT

A 2-year-old (12 kg) male with a history of pulmonary atresia, ventricular septal defect (VSD), and Tetralogy of Fallot (TOF) was admitted for surgical repair of his TOF and VSD patch closure. Following the surgical procedure, the patient remained intubated. Continuous infusions of fentanyl (3 mcg/kg/hr) and midazolam (0.05 mg/kg/hr) were initiated and quickly titrated to 5 mcg/kg/hr and 0.1 mg/kg/hr, respectively. The patient also required dopamine and milrinone postoperatively for treatment of low cardiac output syndrome. Both cardiac and ventilator support were weaned and discontinued on hospital day 3.

The following day, the patient required re-intubation due to increased work of breathing and hypoxia. Chest tubes were placed to manage bilateral pleural effusions, one of which was thought to be chylous in nature. Continuous infusions of fentanyl (2 mcg/kg/hr) and midazolam (0.05 mg/kg/hr) were again initiated for sedation and analgesia. Dexmedetomidine (Precedex; Hospira, Lake Forest, IL) was initiated on day 4 in an effort to decrease opioid requirements and provide additional sedation. The patient was given a 9 mcg (0.75 mcg/kg) loading dose followed by a continuous infusion of 0.7 mcg/kg/hr. Despite the addition of dexmedetomidine, the patient required an upward titration of both fentanyl (5 mcg/kg/hr) and midazolam (0.2 mg/kg/hr) in order to maintain adequate sedation.

Due to increased ventilatory peak pressures on hospital day 5, a vecuronium continuous infusion (0.1 mg/kg/hr) was initiated and the patient was paralyzed for a total of four days.

Enteral methadone (0.4 mg/kg q 6 hours) and diazepam (0.2 mg/kg q 6 hours) were initiated on hospital day 13 for prevention of opioid and benzodiazepine withdrawal following weaning of the continuous infusions and discontinuation of fentanyl and midazolam (Figure). On hospital day 14, fentanyl and midazolam were discontinued after 11 total days of therapy. The following day, the dexmedetomidine (0.7 mcg/kg/min) infusion was abruptly discontinued. At this time, the child had been treated with dexmedetomidine for a total of 263 hours and had been given a cumulative dose of 193.7 mcg/kg. The child remained normotensive throughout the duration of the infusion. There was no evidence of rebound hypertension at discontinuation of dexmedetomidine as evidenced by a blood pressure of 107/48 at the end of the infusion and a blood pressure 12 hours later of 106/39. The patient was extubated on hospital day 15.

On hospital day 16, approximately five hours following discontinuation of dexmedetomidine, the PICU attending noted that the patient began demonstrating neurological symptoms such as episodes of blank staring, agitation, and decreased verbal communication. Although the patient's pupils remained equal and reactive throughout the infusions of fentanyl, midazolam, and dexmedetomidine, they were now asymmetric. Opioid and benzodiazepine withdrawal were not suspected since the patient continued on his initial dose of both methadone and diazepam. He

also received intermittent doses of lorazepam and morphine, which produced a modest reduction in agitation. There were no significant changes in his staring episodes, pupil changes, and verbal communication. On hospital day 18, his parents noted that his verbal communication returned to baseline and that the staring episodes had resolved. Additionally, at this time, the pupils were again equal in reactivity upon examination. Because the patient was noted to have significant improvement, no further neurological workup was obtained.

On hospital day 24, he was transferred to the floor. Methadone and diazepam were gradually tapered by approximately 10% daily, and were discontinued on hospital days 33 and 34, respectively. He had full resolution of neurologic sequelae and was discharged on hospital day 38 in stable condition.

DISCUSSION

Dexmedetomidine is approved by the Food and Drug Administration for non-intubated patients undergoing procedural sedation/surgery and short-term (< 24 hours) in adults who are intubated and receiving mechanical ventilation in the intensive care setting.² Although not labeled for use in children, a number of case reports,⁴⁻⁵ case series,^{3,6-8} and studies⁹⁻¹¹ describe the use of dexmedetomidine as an adjunct sedative agent to decrease opioid requirements, facilitate extubation, and treat opioid withdrawal. Doses used in these previous reports range from 0.1–2.5 mcg/kg/hr. Diaz et al reported that pharmacokinetic parameters in children >4 months of age are not significantly different from that of adults and suggested that children can be dosed according to the adult weight based recommendations of 0.2–0.7 mcg/kg/hr.³

The most commonly reported adverse effects of dexmedetomidine include bradycardia, hypotension, and hypertension, all of which appear to be dose related. A recent retrospective case series evaluated adverse effects associated with 74 infusions of dexmedetomidine in children.⁶ The authors reported an incidence rates of 9% for hypotension, 8% for hypertension, and 3% for bradycardia. These cardiovascular events resolved without treatment or responded to a decrease in the rate of infusion.⁶ A prospective observational study reported no statistically significant differ-

ences between baseline and ending mean arterial blood pressures or heart rates in 17 children receiving dexmedetomidine.¹¹ It is important to note that no patient received a loading dose in this study. Other studies have also reported no statistically significant increase in adverse effects or rebound hypertension with prolonged infusions;⁵⁻⁶ however, these reports failed to describe if dexmedetomidine was gradually tapered or if the infusion was abruptly discontinued.

The duration of dexmedetomidine use reported in pediatric patients range from 1–451 hours.³⁻¹¹ The patient described in this case received a continuous infusion of dexmedetomidine for a total of 263 hours. Our patient remained hemodynamically stable throughout the infusion and following completion of the infusion, but did experience adverse effects including blank staring episodes, asymmetric pupils, agitation, and decreased verbal communication approximately five hours following the abrupt discontinuation of dexmedetomidine. At this time, the patient was receiving methadone and diazepam for prevention of opioid and benzodiazepine withdrawal. He received intermittent doses of narcotics and benzodiazepines, but only had improvement in the level of his agitation. For this reason, the intensivist believed that these symptoms were related to dexmedetomidine withdrawal.

The onset of symptoms appeared to coincide with dexmedetomidine withdrawal, given that dexmedetomidine has a terminal half life of 2 hours.² In a prospective, open-label study involving adult patients receiving prolonged infusions (> 24 hours) of dexmedetomidine, Shehabi and colleagues¹² noted that adverse hemodynamic effects (e.g., increased heart rate and increased systolic blood pressure) occurred within 5 hours of abrupt discontinuation of dexmedetomidine. Our patient's symptoms continued to improve on hospital days 17 and 18, and he did not require any additional interventions.

The manufacturer product information states that the abrupt cessation of dexmedetomidine could potentially result in withdrawal symptoms similar to those seen with clonidine (i.e., agitation, irritability, rebound hypertension).² At least one case of neurological adverse events has been reported. Venn and colleagues report a case of an adult who developed dystonic movements while receiving a large dose of dexmedetomidine (1.5 mcg/kg/hr) for 24 hours.¹³ The authors at-

tributed this adverse event to the central actions of α_2 -adrenoceptor agonism. Others have suggested that clinicians could potentially avoid the development of withdrawal symptoms by using a gradual taper of dexmedetomidine in patients who received prolonged therapy (i.e., > 24 hours).¹⁴ It is unknown whether our patient's symptoms could have been avoided by gradually tapering the dexmedetomidine.

CONCLUSION

The use of dexmedetomidine in children is increasing. Although the manufacturer recommends that the medication be infused for < 24 hours, prolonged infusions are being used in the clinical setting. A limited number of published reports have noted adverse effects following the prolonged use of dexmedetomidine.^{5-6,11,12,14} Patients receiving prolonged continuous infusions of dexmedetomidine like our patient may be at risk for withdrawal symptoms following abrupt discontinuation. Clinicians should be aware of the potential for withdrawal symptoms, including rebound tachycardia and neurologic manifestations (e.g., agitation, speech abnormalities, irritability). Given that the half-life of dexmedetomidine is two hours, patients should be monitored for withdrawal symptoms for the first 12-24 hours following discontinuation. To prevent withdrawal, it may be prudent to taper dexmedetomidine in any patient who has received therapy > 24 hours. A reasonable approach is to taper dexmedetomidine by 0.1 mcg/kg/hr every 12-24 hours. Future prospective studies should be conducted to determine the incidence and severity of withdrawal symptoms associated with dexmedetomidine.

DISCLOSURE The authors declare no conflicts or financial interest in any product or service mentioned in the manuscript, including grants, equipment, medications, employment, gifts, and honoraria.

ACKNOWLEDGMENT The patient described in this case report was part of a patient cohort that was published as a clinical investigation.¹⁵

REFERENCES

1. Virtanen R, Savola JM, Saano V, Nyman L. Characterization of the selectivity, specificity, and potency of medetomidine as an alpha 2-adrenoceptor agonist. *Eur J Pharmacol* 1988;150:9-14
2. Precedex [package insert] Lake Forest, IL: Hospira, Inc.; October 2008.
3. Diaz SM, Rodarte A, Foley J, Capparelli EV. Pharmacokinetics of dexmedetomidine in postsurgical pediatric intensive care unit patients: Preliminary study. *Pediatr Crit Care Med* 2007;8:419-424.
4. Tobias JD. Dexmedetomidine to treat opioid withdrawal in infants following prolonged sedation in the pediatric ICU. *J Opioid Manag* 2006;2:201-205.
5. Hammer GB, Philip BM, Schroeder AR, et al. Prolonged infusion of dexmedetomidine for sedation following tracheal resection. *Paediatr Anaesth* 2005;15:616-620.
6. Carroll CL, Krieger D, Campbell M, et al. Use of dexmedetomidine for sedation of children hospitalized in the Intensive Care Unit. *J Hosp Med* 2008;3:142-147.
7. Finkel JC, Johnson YJ, Quezado ZMN. The use of dexmedetomidine to facilitate acute discontinuation of opioids after cardiac transplantation in children. *Crit Care Med* 2005;33:2110-2112.
8. Chrysostomou C, Filippo SD, Manrique A, et al. Use of dexmedetomidine in children after cardiac and thoracic surgery. *Pediatr Crit Care Med* 2006;7:126-131.
9. Tobias JD, Berkenboch JW. Sedation during mechanical ventilation in infants and children: Dexmedetomidine versus midazolam. *South Med J* 2004;97:451-455.
10. Petroz GC, Sikich N, James M, et al. A phase 1, two-center study of the pharmacokinetics and pharmacodynamics of dexmedetomidine in children. *Anesth* 2006;105:1098-1110.
11. Buck ML, Willson DF. Use of dexmedetomidine in the pediatric intensive care unit. *Pharmacotherapy* 2008;28:51-57.

12. Shehabi Y, Ruettimann U, Adamson H, et al. Dexmedetomidine infusion for more than 24 hours in critically ill patients: sedative and cardiovascular effects. *Intensive Care Med* 2004;30:2188-2196.
13. Venn RM, Newman PJ, Grounds RM. A phase II study to evaluate the efficacy of dexmedetomidine for sedation in the medical intensive care unit. *Intensive Care Med* 2003;29:201-207.
14. Weber MD, Thammasitboon S, Rosen DA. Acute discontinuation syndrome from dexmedetomidine after protracted use in a pediatric patient. *Paediatr Anaesth* 2008;18:87-88.
15. Honey BL, Harrison DL, Gormley AK, Johnson PN. Evaluation of adverse events noted in children receiving continuous infusions of dexmedetomidine in the intensive care unit. *J Pediatr Pharmacol Ther* 2010;15:30-37