

Comprehensive Review of Cardiovascular Involvement in COVID-19

Ruff Joseph Macale Cajanding, MSc (Lond), MBio, BSN, RN

ABSTRACT

COVID-19 has emerged as one of the most devastating and clinically significant infectious diseases of the last decade. It has reached global pandemic status at an unprecedented pace and has placed significant demands on health care systems worldwide. Although COVID-19 primarily affects the lungs, epidemiologic reports have shown that the disease affects other vital organs of the body, including the heart, vasculature, kidneys, brain, and the hematopoietic system. Of importance is the emerging awareness of the effects of COVID-19 on the cardiovascular system. The current state of knowledge regarding cardiac

involvement in COVID-19 is presented in this article, with particular focus on the cardiovascular manifestations and complications of COVID-19 infection. The mechanistic insights of disease causation and the relevant pathophysiology involved in COVID-19 as they affect the heart are explored and described. Relevant practice essentials and clinical management implications for patients with COVID-19 with a cardiac pathology are presented in light of recent evidence.

Key words: acute coronary syndrome, coronary artery disease, COVID-19, nursing, pathophysiology, SARS-CoV-2

In late 2019, clusters of patients presenting with atypical pneumonia of unknown etiology were reported in Wuhan in the Hubei Province of China.¹ These patients were epidemiologically linked to a shared exposure to the Huanan Seafood Wholesale Market in Wuhan's Jianghan District, where a number of exotic livestock and wild animals, including rabbits, civets, pangolins, and snakes, were sold and traded. On December 31, 2019, an epidemiologic alert was raised by the Wuhan Municipal Health Commission to the World Health Organization (WHO) China Country Office, and the market was immediately closed on January 1, 2020, for environmental sanitation and disinfection.²

Suspected patients were immediately transferred to a designated hospital in Wuhan

(Jinyintan Hospital) and were isolated using airborne precautions. Bronchoalveolar lavage samples were collected from symptomatic patients, and the initial specimens tested positive for the presence of a previously unreported respiratory virus.¹ Whole-genome sequencing, polymerase chain reaction, and viral cultures revealed that the causal agent of the outbreak is a novel coronavirus that is capable of infecting humans and shares close sequence similarity to other

Ruff Joseph Macale Cajanding is Charge Nurse, Adult Critical Care Unit, 6th Floor, King George V Building, St Bartholomew's Hospital, Barts Health NHS Trust, 2 King Edward Street, London EC1A 1HQ, United Kingdom (ruffcajanding@nhs.net).

The author declares no conflict of interest.

DOI: <https://doi.org/10.4037/aacnacc2021302>

pathogenic betacoronaviruses such as the severe acute respiratory syndrome coronavirus (SARS-CoV) and Middle East respiratory syndrome coronavirus (MERS-CoV).³ The virus was provisionally named “2019 novel coronavirus” and the disease it caused named “novel-coronavirus infected pneumonia.”⁴

In early January 2020, laboratory tests confirmed 41 patients admitted to Jinyintan Hospital positive for 2019 novel coronavirus, with 66% of them (n=27) having direct exposure to the Huanan Seafood Wholesale Market (as workers, handlers, or frequent visitors) and 32% (n=13) admitted to intensive care for ventilatory support and management of hypoxemia.¹ Soon after, cases of COVID-19 were reported in other parts of China, in Thailand, Japan, Singapore, South Korea, Australia, the United States, and the Philippines, all involving recent travel or exposure to individuals coming from Wuhan.

On January 20, 2020, the WHO confirmed evidence of human-to-human transmission in Wuhan. On January 30, 2020, the WHO Emergency Committee declared the COVID-19 outbreak a Public Health Emergency of International Concern, and on March 11, 2020, the WHO declared the outbreak of COVID-19 a global pandemic.

Virology and Characterization of SARS-CoV-2

The first complete genome of the novel coronavirus isolated from bronchoalveolar lavage fluid samples of patients initially infected in Wuhan were submitted by the Chinese National Institute of Viral Disease Control and Prevention to the Global Influenza Data Initiative on January 10, 2020.⁵ Using a combination of Sanger, Illumina, and Oxford Nanopore sequencing, 6 bronchoalveolar lavage samples all tested positive for the nearly identical, complete genome of the 2019 novel coronavirus. Phylogenetic analysis showed that the new coronavirus shares close sequence homology to bat-derived coronaviruses, namely bat-SL-CoVZC45 (87.6%) and bat-SL-CoVZXC21 (87.7%), both isolated from Chinese horseshoe bats (*Rhinolophus sinicus*) collected in 2018 in Zhoushan, and to Bat-nCoV RaTG13 (96.2%) detected from *R affinis* in Yunnan.³ This new coronavirus strain, however, was less genetically similar to SARS-CoV and MERS-CoV, sharing only 82.4% and 69.5% of its sequence

homology, respectively.⁴ Genomic sequence data confirmed that the novel coronavirus belonged to the Betacoronavirus-2b lineage of the *Sarbecovirus* subgenus of the Orthocoronavirinae. On February 11, 2020, the International Committee on Taxonomy of Viruses adopted the official nomenclature “severe acute respiratory syndrome coronavirus 2” (SARS-CoV-2) and “coronavirus disease 2019” (COVID-19) to name the virus and the disease it causes, respectively.⁶

SARS-CoV-2 is an enveloped virus with a nonsegmented, single-stranded, positive-sense RNA as its genetic material.⁷ Electron microscopy shows that SARS-CoV-2 has a spherical morphology with some pleomorphism, measures between 60 and 160 nm in diameter, and has spikes ranging from 9 to 12 nm long, giving the appearance of a solar corona, consistent with viruses in the Coronaviridae.⁸

The close homology of SARS-CoV-2 to other severe acute respiratory syndrome-like coronaviruses isolated from bats suggests SARS-CoV-2 has a zoonotic origin and that bats may have served as its natural host and reservoir. Phylogenetic studies show that RaTG13, a coronavirus isolated from bats, is SARS-CoV-2's closest ancestor, based on a remarkably high similarity of its full-length genome (96.2%), receptor-binding protein spike (S), and RNA-dependent RNA polymerase gene sequences.³ Although bats appear to be key natural hosts of the virus, recent evidence suggests that another live animal present in Huanan may have served as its intermediate reservoir, as in the case of SARS-CoV (the masked palm civet, *Paguma larvata*)⁹ and MERS-CoV (dromedary camels, *Camelus dromedarius*).¹⁰ This possibility is based on reports that no bats were sold or found in Huanan Seafood Wholesale Market during the environmental survey and that most bat species in Wuhan hibernate around that time of the year (late November to December). Furthermore, coronaviruses with high sequence similarities (85.5%-92.4%) to SARS-CoV-2 were identified in Malayan pangolins (*Manis javanica*) in Guangxi and Guanzhou, species that are commonly illegally trafficked in China for food and medicine, strongly suggesting the possibility of cross-species transmission through an intermediate host.¹¹ Environmental samples collected from the market were also found positive for SARS-CoV-2, but because the wild animals were

cleared soon after the outbreak started, determining the original animal source of virus remains elusive.¹²

SARS-CoV-2 Mode of Transmission

COVID-19 is primarily transmitted by person-to-person contact through inhalation of respiratory droplets generated when an infected individual coughs, sneezes, or speaks.¹³ Droplet transmission occurs when larger particles (>5 µm) containing the infective agent are released into the air and come into contact with the conjunctiva and mucous membranes of a susceptible host. It is possible, however, for some respiratory droplets to be converted into aerosol particles (called bio-aerosols) with smaller diameters and consequently become airborne, and such airborne particles can potentially infect individuals when they are inhaled.¹⁴ Airborne particles have smaller aerodynamic diameters (<5 µm), linger in the air longer, drift farther away than droplets, and reach the respirable fraction of the lungs deeper than droplets do, which are usually trapped in the upper airways.¹⁵ Given that some medical procedures can be both aerosol and droplet generating (eg, tracheal intubation, high-flow oxygen therapy, tracheostomy tube insertion, bronchoscopy, cough-assist therapy, transesophageal echocardiography), risk of nosocomial transmission of SARS-CoV-2 in hospitals can be potentially high, especially in areas where aerosol-generating procedures are commonly used (eg, intensive care units, respiratory wards, operating rooms).¹⁶

COVID-19 also is transmitted by direct contact with infected fomites (inanimate objects), followed by subsequent self-inoculation of the mucous membranes of the nose, mouth, or eyes.¹³ Given that SARS-CoV-2 can persist on inanimate surfaces for long periods (ie, ≤6 days), viral transmission through infected fomites and self-inoculation can occur as the result of poor hand hygiene, inappropriate use of personal protective equipment, and frequent touching of contaminated objects and surfaces.¹⁷ The measurable risk of fomite-mediated transmission in real-life conditions, however, is small and unlikely to occur, and it can be easily ameliorated with good environmental practices (ie, sanitation and decontamination of surfaces), meticulous

hand hygiene, and reasonable use of personal protective equipment.¹⁸

SARS-CoV-2 Mechanism of Cellular Entry and Invasion

The initial step of SARS-CoV-2 infection involves the specific binding of the coronavirus S protein to the host cellular entry receptor, which is the human angiotensin-converting enzyme-2 (ACE2) located on the cell surface.¹⁹ Both SARS-CoV and SARS-CoV-2 recognize and use human ACE2 as their receptor; however, according to *in vitro* studies, the SARS-CoV-2 receptor-binding domain has significantly higher ACE2 binding affinity (10- to 20-fold higher) than SARS-CoV does, and this accounts for SARS-CoV-2's higher rate of infectivity and spread.²⁰ After receptor binding, viral fusion is facilitated by proteolytic cleavage of coronavirus S protein into 2 domains (ie, the S1 domain responsible for receptor binding and the S2 domain, which mediates membrane fusion by host cell-derived protease at S1/S2 site) by the cell-surface serine protease type II transmembrane protease, serine 2.²¹ Inhibition of this protease's activity blocks viral entry, and serine protease inhibitors have been investigated as potential therapeutic options for preventing SARS-CoV-2 infection.²² Similar to other coronaviruses, SARS-CoV-2 contains furin-like protease recognition-pattern sequences in its S protein that act as furin cleavage sites.²³ Furin, a proprotein convertase located in the trans-Golgi network, is a proteolytic enzyme that plays an important role in the cleavage and activation of a wide variety of precursor proteins into their biologically active and mature forms. According to *in vivo* studies, furin cleavage of viral glycoproteins can enhance viral fusion with host-cell membranes, expand and widen cellular tropism, and increase viral pathogenicity. In addition, the presence of furin cleavage sites in SARS-CoV-2 accounts for its high rate of infectivity and pathogenicity.^{23,24}

After binding, the viral envelope proteins fuse to the host-cell membrane and enter the cytoplasm via the endosomal pathway. After endocytosis, viral RNA is released in the host cytoplasm, undergoes translation, and the virion proteins are assembled in the endoplasmic reticulum and Golgi complex before they are released out of the cells through vesicular transport.²⁵

Unique Role of ACE2 in COVID-19 Pathogenesis

The ACE2 receptor is located in several tissues and cell types in humans and is most abundantly expressed in type II alveolar epithelial cells of the lung parenchyma.²⁶ Angiotensin-converting enzyme-2 is similarly enriched on the surface of the epithelial cells lining the oronasal mucosa and the nasopharynx, indicating that the respiratory passages provide a rich and abundant target for SARS-CoV-2 attachment and binding.²⁷ Angiotensin-converting enzyme-2 is also highly expressed in cardiomyocytes and cardiac pericytes, and less so in fibroblasts, endothelial cells, and cardiac leukocytes.²⁸ Outside the heart and lungs, ACE2 receptors are found in the brush border of the enterocytes of the small intestines²⁶; in the brush border of kidney proximal tubular cells and podocytes²⁹; in the arterial and venous endothelium lining the lungs, kidneys, stomach, and brain²⁶; in the neurons of the cortex, striatum, hypothalamus, and brainstem; and in glia and astrocytes.³⁰

Angiotensin-converting enzyme-2 has extensive biological function in health and disease and plays an important role in the maintenance of blood pressure, regulation of circulating blood volume, electrolyte and fluid homeostasis, and maintenance of vascular tone and integrity.³¹ In the renin-angiotensin-aldosterone system, ACE cleaves the prohormone angiotensin I to produce angiotensin II, a potent vasoconstrictor. Angiotensin II increases sympathetic outflow in the brain, leading to increased epinephrine and norepinephrine release, and stimulates the sympathetic ganglia, which leads to inhibition of norepinephrine uptake in the sympathetic nerve terminals and vasoconstriction.³² Angiotensin II also stimulates vascular smooth muscle growth, enhances the expression of cytokines involved in mediating inflammation, activates gene transcription of some proto-oncogenes, triggers the synthesis of collagen type I and III in fibroblasts leading to the thickening of vascular wall and myocardium, and activates the neurohormonal responses involved in development of heart failure (HF).³³

Angiotensin II then binds to either angiotensin II receptor type 1, which causes increased sympathetic and noradrenergic activity, vasoconstriction, reduction in renal blood flow, smooth muscle cell proliferation, and stimulation of cardiac hypertrophy; or to angiotensin II receptor 2 type 2, which is more protective

and leads to vasodilation via increased nitric oxide production, lowering of blood pressure via enhanced natriuresis, downregulation of mediators involved in inflammation, and inhibition of cellular proliferation.³¹ Angiotensin-converting enzyme-2 converts angiotensin II to angiotensin₁₋₇, a potent vasodilator and important counter-regulatory mechanism for the pressor, proliferative, and stimulatory effect of angiotensin II. Angiotensin₁₋₇ opposes the action of angiotensin II through stimulation of prostaglandin and nitric oxide activity, suppression of aldosterone and vasopressin release, increased natriuresis, and inhibition of vascular growth, leading to relaxation of arterioles, vasodilation, and reduction in blood pressure.³⁴

SARS-CoV-2 binding to ACE2 causes the internalization of the virus-receptor complex, which leads to ACE2 downregulation and disruption of the normal angiotensin II-to-ACE2 ratio.^{21,35} Lower availability of ACE2 and loss of ACE2 activity result in a lower rate of angiotensin II degradation and a higher-than-normal level of circulating angiotensin II. Elevated angiotensin II level contributes to the development of arteriosclerosis and microvascular thrombosis by stimulating the release of tissue factor and platelet-derived growth factor, resulting in a prothrombotic endothelium and increased rate of platelet aggregation.³⁶ Unopposed angiotensin II also accelerates endothelial dysfunction through cyclooxygenase-2 activation and generation of prostaglandins and reactive oxygen species, increasing vascular permeability, promoting the secretion of vascular endothelial growth factor, and inducing the expression of endothelial adhesive molecules, including selectins.³⁷

Increased activity of angiotensin II also upregulates the inflammatory response by increasing the systemic and local levels of pro- and anti-inflammatory cytokines such as interleukin-6 (IL-6), interferon γ , tumor necrosis factor α , and IL-1 β .³⁸ This action allows immune cells to be recruited to sites of injury and accentuates the killing activity of macrophages by enhancing phagocytosis and increased production of reactive oxygen species, which is particularly useful in limiting pulmonary infection.³⁹ However, an unabated response can lead to dysregulated inflammatory process and tissue damage, which enhanced lung injury in mice in experimental studies.⁴⁰

SARS-CoV-2 Pathophysiology

The human respiratory passages are the main portal of entry for SARS-CoV-2. Upon inhalation of infected droplets, the viral particles attach and bind to the surface of the ciliated epithelial cells lining the upper respiratory airways.⁴¹ In *in vitro* studies, SARS-CoV infected nasal and tracheobronchial ciliated epithelium more effectively than it did the cells in the alveolar regions, demonstrating that SARS-CoV infection of the proximal airway is crucial for establishing infection.^{27,42} Inside the cells, the virus replicates and propagates, and the viral particles co-locate and accumulate in the microvilli, cilia shafts, and the airway surface microenvironment surrounding the apical surface of the ciliated cells. This is followed by subsequent release of large quantities of virus in the lumen of the conducting airways during viral replication.²⁷ At this stage, infected individuals, even those without any symptoms, may already be infectious, with actual viral shedding easily detectable by nasopharyngeal viral reverse transcription–polymerase chain reaction.⁴¹

A majority of patients may remain completely asymptomatic or may only exhibit constitutional symptoms such as cough, fever, myalgia, and fatigue as a result of the mild immune response elicited by a localized viral infection. In approximately 20% of patients, infection will progress to severe disease as the virus propagates and migrates down the lower respiratory tract, infects the endothelium, and leaks out into the bloodstream.⁴³

A considerable proportion of patients with severe disease will manifest pulmonary involvement characterized by hypoxemia, dyspnea, and development of bilateral infiltrates and diffused alveolar injury with exudative and interstitial inflammation, which explains the purpose of administering anti-inflammatory drugs in early COVID-19 to curb the hyperinflammatory response.^{44,45} Postmortem analysis of COVID-19 lungs reveals a wide range of pathologic findings ranging from an adult respiratory distress syndrome (ARDS)–like picture of profound capillary congestion, pneumocyte necrosis, hyaline membrane formation, and platelet-fibrin thrombi deposition⁴⁶ to a clinical picture that resembles deranged angiogenesis characterized by severe endothelial injury, disrupted endothelial membrane, widespread vascular thrombosis with microangiopathy,

and occlusion of alveolar capillaries.⁴⁷ COVID-19 lung autopsy results also indicate there is extensive complement involvement and activation of the membrane-attack complex and clotting pathway that lead to the development of thrombotic microvascular lung injury and alveolar capillary damage.⁴⁸

Moderate to severe COVID-19 can also trigger a widespread inflammation and immune response activation evidenced by high levels of expression of IL-6, IL-1 β , interferon γ , interferon- γ -inducible protein 10, and monocyte chemoattractant protein 1—pro-inflammatory cytokines associated with activated T-helper type-1 cell activation.⁴⁹ Accumulated evidence and clinical studies also show that individuals with severe COVID-19 generally experience cytokine-release syndrome or cytokine storm, which plays a crucial role in disease progression and is considered a major cause of COVID-19–associated ARDS and multiorgan dysfunction syndrome.⁵⁰ High levels of IL-6, the main mediator of inflammatory and immune response to viral challenge, are also seen in patients who have severe presentation and are being investigated as an important prognosticator for negative outcomes in COVID-19.⁵¹ Presently, agents blocking the IL-6 response (eg, tocilizumab, sarilumab) and the cytokine-release syndrome are being investigated as potential therapeutic strategies for COVID-19.⁵²

Cardiovascular Involvement in COVID-19

The main organ primarily affected by SARS-CoV-2 is the lungs; however, most hospitalized patients with COVID-19 present with some degree of cardiovascular involvement, which can range from mild nonspecific cardiac injury, acute elevation of troponin, acute myocardial infarction (AMI), myocarditis, arrhythmias, acute exacerbation of HF, and thrombotic derangement (Figure 1).^{53,54} Early reports in Wuhan suggested that myocardial involvement in COVID-19 was common, with 12% of those who presented early in the pandemic showing signs of acute cardiac injury.¹ In addition, a considerable proportion of patients with moderate to severe COVID-19 infection who are admitted to hospitals are older adults with preexisting morbid conditions, and accumulated evidence shows that the presence of cardiovascular risk factors or a preexisting


Cardiovascular Risk Factors	Cardiovascular Complications
Hypertension Obesity Coronary artery disease Heart failure Diabetes Arrhythmias COPD and asthma Advanced age Other age-related diseases	 Acute cardiac injury Myocarditis Heart failure Acute coronary syndrome and acute myocardial infarction Arrhythmias and conduction disturbances Thrombotic complications and deranged coagulation

Figure 1: Cardiovascular risk factors associated with poor outcomes in COVID-19 and the cardiovascular complications manifested in patients with COVID-19 infection. COPD indicates chronic obstructive pulmonary disease.

diagnosis of a cardiovascular disease (CVD) predispose patients to worse outcomes from COVID-19.⁵⁵ In a large Chinese study, of 44 672 patients diagnosed with COVID-19 during the first wave of the pandemic, 12.8% had hypertension, 5.3% had diabetes, and 4.2% had a CVD diagnosis.⁵⁶ Similar results were reported in a large New York study in which, of 5700 patients with COVID-19, a vast majority had a cardiovascular risk factor, including hypertension (56.6%), obesity (41.7%), diabetes (33.8%), coronary artery disease (11.1%), and congestive heart failure (CHF) (6.9%).⁵⁷ A recent meta-analysis of a total of 77317 patients showed that cardiovascular comorbidities in COVID-19 are common and include hypertension (36.1%), obesity (33.8%), diabetes (19.5%), coronary artery disease (11.7%), smoking (10.7%), and CHF (9.4%).⁵⁸ Several clinical features are associated with poorer short-term outcomes in COVID-19 infection, including obesity (body surface area >40 kg/m²), asthma, chronic obstructive pulmonary disease, hypertension, CHF, coronary artery disease, diabetes, and arrhythmias. In addition, a vast majority of these risk factors were confounded and complicated by age.⁵³

Cardiovascular complications are common in COVID-19 and include acute cardiac injury, myocarditis, acute coronary syndrome (ACS), HF, arrhythmias, thromboembolic events, and sudden cardiac death, the causes of which are thought to be the result of the complex interplay between several host and viral factors (Figure 2). Some patients may present with cardiac symptoms as the first clinical manifestations of COVID-19, and some patients

with an undiagnosed heart condition may present with symptoms that are unmasked by the existence of a viral infection.⁵³ A few patients may experience cardiac symptoms that mimic other cardiac conditions (eg, ACS) but without the pathologic lesions or findings (ie, plaques or changes in an electrocardiogram); a few may present with fulminant conditions that rapidly progress and can cause sudden cardiac death. Finally, cardiac symptoms may occur as a complication of the pulmonary insult (ie, consequences of hypoxia), the multisystem inflammatory response, viral sepsis, or as a side effect of medications or treatments given during hospitalization.

Interestingly, there is also increasing recognition that a COVID-19 diagnosis is, in itself, an important risk factor for the development of CVD, given that hypercoagulability, systemic inflammatory activity, and cardiac injury can persist for a long period after the acute phase of illness.⁵³ Although the long-term effects of COVID-19 are still being identified, continuous vigilance and surveillance of signs and symptoms of residual organ dysfunction and perturbation appear judicious in light of developing a more holistic and preventive approach in managing the short- and long-term impacts of a very complex and enigmatic disease.⁵⁹

Myocardial Injury and Myocarditis

Myocardial injury is common among patients with COVID-19 and was demonstrated in 12%¹ to 23%⁶⁰ of patients in early reports. Defined as a decline in ejection fraction and a marked increase in levels of troponin I above the 99th

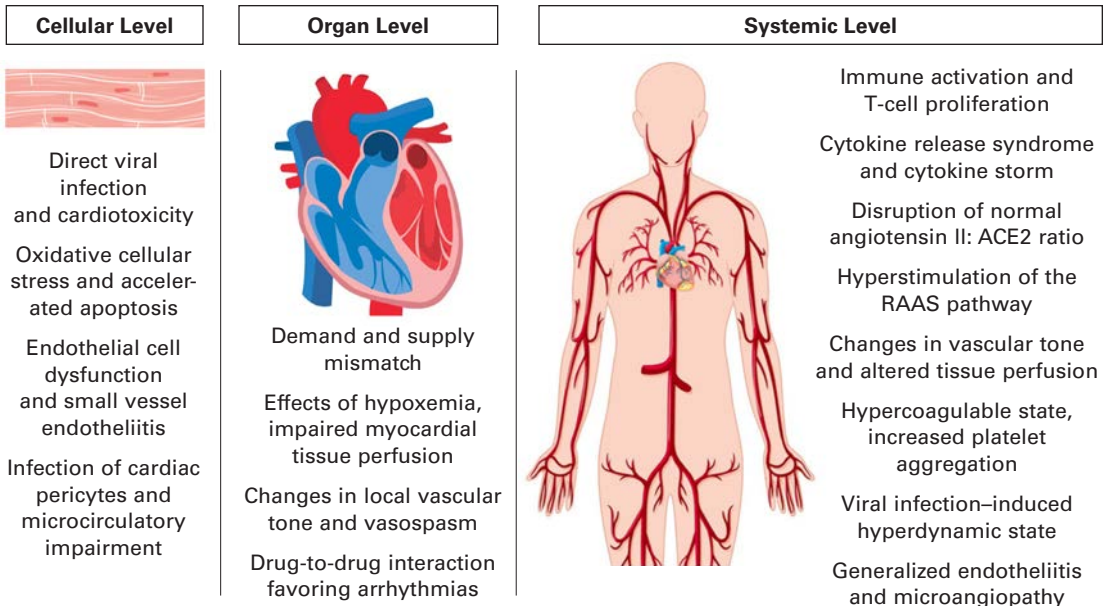


Figure 2: Putative pathophysiologic mechanisms explaining disease causation in COVID-19 infection as it affects the cardiovascular system. ACE2 indicates angiotensin-converting enzyme-2; RAAS, renin-angiotensin-aldosterone system.

percentile in the presence of normal epicardial coronary arteries, myocardial injury was first reported and identified in initial cases of COVID-19 in China, providing early evidence of cardiac involvement in COVID-19.¹ Indeed, in several prospective studies, researchers have identified a wide range of cardiac injuries associated with COVID-19 infection, ranging from a mild elevation in troponin I level to an impairment in left ventricular function as visualized in an echocardiogram.^{1,53,60,61}

According to a retrospective study conducted in China during the early stages of the COVID-19 pandemic, cardiac injury was prevalent in hospitalized patients (19.7%; n = 82), and these patients were more likely to be ill and to die, compared with those in whom cardiac injury did not develop.⁶¹ Elevated troponin levels also are associated with a higher mortality rate and higher frequency of arrhythmias, even among patients without underlying CVD.⁶²

Acute cardiac injury appears to be driven by the hyperinflammatory reaction and cytokine storm induced by COVID-19 infection, which, in the context of a developing ARDS and pulmonary hypertension, can cause right ventricular strain.⁶³ The development of acute cardiac injury is observed more frequently in individuals with hypertension and coronary

heart disease, indicating that a preexisting CVD is a risk factor for acute cardiac injury.⁶¹ The activation and hyperstimulation of the renin-angiotensin-aldosterone system pathway also appears to play a significant role in the uncontrolled vasoconstriction, inflammation, proliferation, and fibrosis that accelerate adverse myocardial remodeling, which can lead to an acute cardiac injury.⁵⁴

Myocarditis is a clinical syndrome characterized by inflammation of the myocardium in the absence of a predominant acute or chronic ischemia characteristic of coronary artery disease. The WHO and International Society and Federation of Cardiology Task Force on the Definition and Classification of Cardiomyopathies define myocarditis as the disease of the myocardium diagnosed by established histologic, immunologic, and immunohistologic criteria, which include the presence of inflammatory infiltrates associated with myocyte degeneration.⁶⁴

Several viruses have been implicated as major causes of myocarditis, the most common of which include the cardiotropic viruses adenovirus, enterovirus, Epstein-Barr virus, parvovirus B19, and cytomegalovirus.⁶⁵ The development of viral myocarditis largely depends on several host-pathogen factors,

which include successful viral entry into the host myocardial cell, replication of viruses that managed to evade the cellular immune response, the production of viral proteins that cause myocardial injury, the activation of adaptive immunity including the infiltration of T lymphocytes in the heart, and the remodeling that occurs in the myocytes as the disease develops and progresses.⁶⁶

Despite being a minor cause of all viral myocarditis cases, human coronaviruses have been shown to cause myocarditis.⁶⁷ SARS-CoV and MERS-CoV, respiratory betacoronaviruses that infect humans, have been detected in heart tissues of infected individuals,^{68,69} suggesting that coronaviruses may possess selective cardiotropism. One crucial component required in the infection of the myocardial cell is the availability of receptors to which the viruses can attach and interact. Angiotensin-converting enzyme-2, the SARS-CoV-2 receptor, is found in cardiomyocytes; in single-nuclei RNA sequencing studies, ACE2 was also expressed in cardiac pericytes, fibroblasts, endothelial cells, and leukocytes.²⁸ Furthermore, ACE2 expression is upregulated in patients with HF (namely, ischemic and dilated cardiomyopathy),⁷⁰ and patients treated with ACE inhibitors have higher-than-usual ACE2 cardiomyocyte expression.⁷¹ Given that cardiac cells are enriched with the attachment sites for SARS-CoV-2, direct viral entry into the heart cells was proposed to result in direct cell injury and that the resulting T-lymphocyte-mediated cytotoxicity drives development of myocarditis in patients with COVID-19 who have an existing cardiac injury.⁶⁵⁻⁶⁷

Tavazzi et al⁷² first reported the evidence of SARS-CoV-2's ability to directly invade myocardial cells when they detected viral particles in the inflamed interstitial myocardial tissues of a 69-year-old patient who presented with cardiogenic shock. In a more recent study, Dolhnikoff et al⁷³ reported SARS-CoV-2 viral particles in the cardiac myocyte biopsy specimen of a 11-year-old child who died of multisystem inflammatory syndrome associated with COVID-19 infection. Histopathologic examination revealed marked myocarditis, pericarditis, and endocarditis with inflammatory cell infiltration and cardiomyocyte necrosis, with viral particles present in various cardiac cell types (namely, cardiomyocytes, capillary endothelium, endocardium endothelium, fibroblasts, and macrophages), confirming that

SARS-CoV-2 infection of myocardial cells can lead to cellular necrosis and myocarditis.⁷³

Researchers also postulated that COVID-19 myocarditis could be a result of SARS-CoV-2 infection of cardiac pericytes, which can lead to capillary endothelial cell dysfunction and induction of microcirculatory disorders.⁷⁴ Last, the cytokine storm elicited during the initial infection and the associated exaggerated immune response can trigger direct myocardial tissue damage leading to cardiomyocyte necrosis, and this can predispose fulminant myocarditis development.^{35,75}

Acute Coronary Syndrome and Acute Myocardial Infarction

Acute coronary syndrome refers to a spectrum of clinical conditions characterized by myocardial ischemia and is manifested by acute angina (chest pain) or an anginal equivalent (ie, breathlessness, heartburn, diaphoresis) with accompanying characteristic changes on electrocardiogram. Albeit uncommon, acute infections, particularly respiratory tract infections like pneumonia, bronchitis, and influenza, are associated with increased risk of ACS, including an AMI. Reports of viral infections being implicated with increased incidence of AMI have been published since the 1930s and are based on epidemiologic studies showing that cardiovascular deaths are statistically increased during influenza season.⁷⁶ In a recent meta-analysis, authors showed that influenza infection is highly associated with AMI, flu vaccination is associated with lower incidence of AMI, and vaccination against respiratory viruses can reduce the risk of AMI even in patients with no preexisting heart disease.⁷⁷

Viral infections can trigger both type 1 AMI, characterized by thrombosis due to plaque rupture and plaque ulceration, and type 2 AMI, also called demand ischemia, whereby myocardial necrosis occurs as a result of demand-supply mismatch brought about by hypoxia, hyperthermia, tachycardia, hypotension, or anemia.⁵⁴ Severe viral infections can cause a systemic inflammatory response that can trigger a hypercoagulable state, which can accelerate thrombosis of the coronary arteries and result in either an ST-elevation myocardial infarction or a non-ST-elevation myocardial infarction. Viral infections can also induce coronary endothelial dysfunction, which can lead to thromboxane A2 overproduction,

platelet activation, vasoconstriction, and platelet aggregation.⁷⁸ Viral infections can also cause fever, tachycardia, hypoxia, and a hyperdynamic state, which can increase myocardial oxygen demand, predisposing patients to type 2 myocardial infarction. Excessive sympathetic stimulation and elevated catecholamine levels can trigger a hyperdynamic cardiovascular response, which can alter systemic and coronary vascular tone, promote vasoconstriction, and induce occlusion by pre-existing atherosclerotic plaques.⁷⁹ The changes in vascular tone, the hypercoagulable state, increased platelet aggregation, and accentuated frictional or shear stress can increase the biomechanical stress present on preexisting atherosclerotic coronary artery plaques and trigger a rupture.⁸⁰ A combination of these mechanisms may explain how SARS-CoV-2 infection can unmask symptoms of coronary ischemia or aggravate preexisting predisposing factors, leading to signs of an AMI.

Heart Failure

Acute HF complicates the clinical course of COVID-19 and a new diagnosis of acute HF in a patient with COVID-19 is associated with very high mortality rate.⁸¹ Development of HF is also common among patients with COVID-19. In a single-site study, HF developed in 23% of patients who were hospitalized with COVID-19 during the course of treatment.⁸² Patients with a history of CHF also have higher risk of acute decompensation after a COVID-19 diagnosis, and these patients are more likely to die in the course of hospitalization compared with those who do not have a HF diagnosis.⁸¹

Viral infections complicate HF and trigger HF events, because of a combination of factors that includes endothelial dysfunction, uncontrolled inflammation, increased coagulation, and increased blood viscosity during febrile illness.⁸³ In COVID-19, the associated systemic inflammation, elevated ischemic risk, and conduction disturbances can induce cardiac stress, which can trigger myocardial injury, cell death, and HF.⁸⁴ In addition, chronic inflammation can drive HF by various mechanisms.⁸³⁻⁸⁶ Ischemic-induced inflammation and myocyte necrosis can lead to immune-cell infiltration, activation of fibroblasts, collagen transformation, generation of scar tissue, and replacement of dead cardiac tissue with fibrotic scar.⁸³ In time, the fibrotic scar can impair the

structural integrity of the cardiac walls, and the increased stiffness can lead to diastolic dysfunction, which, in the presence of pressure overload, can lead to ventricular dilation and rupture, precipitating HF.^{85,86}

Other COVID-19–related factors that can precipitate HF include the respiratory failure and hypoxia that can aggravate the patient's low oxygen supply and increase myocardial energy demand; the use of high positive end-expiratory pressure during mechanical ventilation, which can increase right ventricular afterload and reduce cardiac output; recurrent arrhythmias; hypervolemia; fever; and a hyperdynamic state.^{83,84,86} COVID-19–induced cytokine storm can also predispose patients to stress cardiomyopathy and cytokine-related endothelial dysfunction, which, in turn, can precipitate acute decompensation in a failing heart.⁸⁴

Arrhythmias and Conduction Disturbances

Although arrhythmias are not uncommon events in viral infections, the causes of arrhythmias in COVID-19 are multifactorial and are a result of several host- and pathogen-related factors.⁸⁷ Early reports in Wuhan showed that 7.3% of patients diagnosed with COVID-19 experienced heart palpitations as the initial disease symptom.⁸⁸ Cardiac arrhythmias occur in an estimated 2% to 30% of patients with COVID-19; 5.9% of them are malignant arrhythmias, and they are more prevalent in critically ill patients admitted to intensive care.⁶² In a single-center study, admission to an intensive care unit was associated with greater than 10-fold odds of development of an arrhythmia independent of other risk factors or comorbidities, and cardiac arrhythmias were more likely to develop in patients with more severe systemic illnesses.⁸⁹ The most common pathologic arrhythmias reported among patients with COVID-19 include atrial fibrillation, atrial flutter, ventricular tachycardia, ventricular fibrillation, bradycardia with high degree atrioventricular block, and pulseless electrical activity.^{87,89}

Arrhythmias and disorders of the conduction system are seen in patients with viral infections, particularly with infections involving cardiotropic viruses (eg, influenza H1N1, Zika virus, Epstein-Barr virus, SARS-CoV), that can invade the conduction tissues of the heart or cause an inflammatory infiltration in

any part of the conduction pathway.⁸⁷ In COVID-19, the autonomic imbalance and sympathetic nervous system stimulation in the setting of a raging infection can contribute to arrhythmogenicity, and the systemic inflammatory response syndrome response predisposes patients to tachyarrhythmias.⁸⁹ Viral invasion of the dorsal vagal complex situated in the medulla oblongata has been proposed to contribute to the development of bradyarrhythmias, which may occur as a result of retrograde viral invasion of the neurons of the nasopharyngeal epithelium or by hematogenous spread, crossing, and viral invasion of the blood-brain barrier.⁹⁰

Arrhythmias may also occur in the context of acute myocardial injury, AMI, or myocarditis, in which ventricular arrhythmias seem to be the more predominant presentations. Other important triggers include hypoxia in the context of severe pulmonary involvement, fever, electrolyte imbalances, sepsis, hypovolemia, hypervolemia, preexisting or new renal dysfunction, and existence of other premorbid conditions.⁵³

Finally, several pharmacologic interventions, including both rare and common drug-drug interactions, have been implicated as major causes of arrhythmias in COVID-19. Of note, the use of chloroquine/hydroxychloroquine and azithromycin, pharmacologic agents initially investigated to treat COVID-19, predisposes patients to prolongation of the QT interval and development of polymorphic ventricular tachycardia (ie, torsades des pointes).⁹¹ Chloroquine, a quinoline antimalarial drug also used for the treatment of rheumatoid arthritis and autoimmune diseases, interacts and inhibits hERG potassium channels in a time- and concentration-dependent manner, leading to prolongation of action potential duration, an increase in the action potential dispersion, development of repolarization alternans, and initiation of polymorphic ventricular tachycardia.⁹² Macrolide antibiotics (eg, erythromycin, clarithromycin, azithromycin) have similar effects as class III antiarrhythmics and prolong the QT interval by induction of early-action depolarization and transmural dispersion. Some macrolides are CYP3A4 inhibitors and co-administration with other drugs that inhibit CYP3A4 activity or are metabolized by the CYP3A4 enzyme system can lead to significant toxicity and more potent pro-arrhythmic action.⁹³

Other agents tested for treatment of COVID-19 also are arrhythmogenic, including the antivirals lopinavir and ritonavir. Co-administration with chloroquine and azithromycin can put patients at higher risk for development of arrhythmia, which can occasionally be fatal.⁸⁸

Thrombosis and Clotting Derangement

Reports of unexpectedly high numbers of patients with COVID-19 who present with thrombotic pathologies such as pulmonary embolism, cerebrovascular complications, deep venous thrombosis, and massive disseminated intravascular coagulopathy (DIC) prompted clinicians to investigate whether disorders in clotting and thrombosis are associated with COVID-19 infection.⁹⁴ Early autopsy findings of patients with COVID-19 demonstrated presence of fibrin thrombi in capillaries and small vessels, leading to thrombotic microangiopathy and hemorrhage.⁹⁵ At 1 center, most of the deaths due to COVID-19 demonstrated significant pulmonary embolisms and deep venous thrombosis as the major causes of death.⁹⁶ In a retrospective study, DIC was a common occurrence in worsening COVID-19 infection, and abnormal coagulopathy was associated with more deaths and poorer prognosis.⁹⁷

Patients with COVID-19 have a disproportionately high thrombotic risk characterized by elevated levels of D-dimer, fibrinogen, and fibrin-degradation products, with modest reduction in platelet counts conferring small bleeding risks, suggesting that the coagulopathy associated with COVID-19 infection is not typical DIC.⁹⁴ The suggestion has been made that the systemic coagulopathy and hypercoagulability observed in patients with COVID-19 are a result of an endotheliopathy causing microcirculatory clots and macroangiopathic changes in small vessels.⁹⁸ Researchers reported that SARS-CoV-19 can directly infect endothelial cells via the ACE2 receptors in the cell surface, and this causes diffused endothelial inflammation, immune-mediated destruction, necrosis, and pyroptosis.⁹⁹ The resulting endotheliitis and endothelial dysfunction cause vasoconstriction with resultant organ ischemia, inflammation, and thrombosis.^{98,99} Thrombotic manifestations also may be a novel condition incited by SARS-CoV-2 infection, whereby the thrombotic macroangiopathy is triggered by complement mediation

similar to those seen in autoimmune disorders such as systemic lupus erythematosus or antiphospholipid antibody syndrome.⁹⁴ Viral invasion into epithelial cells triggers an innate immune response that includes activation of type-1 interferons and complement activation, and this incites a complement-initiated damage to vessels that promotes inflammation and additional release of cytokines, leading to a prothrombotic hypercoagulable state.^{94,100} Last, the activation of coagulation pathways as a sequela of cytokine-release syndrome may be contributory to the DIC-like picture seen in severe COVID-19 cases, given that sepsis is an established cause and initiator of DIC.¹⁰¹

Therapeutic Considerations, Practice Implications, and Management

The wide spectrum of cardiac involvement in COVID-19 poses unique challenges in terms of clinical management and decision-making. In the context of the COVID-19 pandemic, the treatment of patients with an existing or a risk factor for CVD should be focused on active prevention of infection and complications, establishing an accurate and prompt diagnosis, and selection of the best available treatment without compromising the safety of the patient and the health care professional.⁵³ The allocation of medical and human resources (eg, diagnostic equipment, treatment facilities, medical and nursing staff) should be based on a prudent and informed risk-versus-benefit approach, because clinical resources may be scarce and access to treatment can be particularly limited.

Patients with preexisting CV morbidities can be at increased risk for complications and more severe presentation of COVID-19⁵⁴; thus, at-risk individuals should meticulously observe and follow established guidelines to prevent inadvertent exposure and infection. It is recommended that patients at risk for cardiac conditions, including the elderly, diligently adhere to and continue protective measures such as shielding, self-isolation, social distancing, use of face masks in public spaces, and frequent and meticulous handwashing to prevent disease transmission and propagation. Individuals with a preexisting CVD should continue to maintain a healthy lifestyle even when self-isolating (eg, balanced diet, avoidance of smoking and alcohol, modest exercise, fluid and sodium restriction, if applicable)

and engage in physical activity, because physical restrictions can lead to inactivity and increased risk of deep venous thrombosis.⁵³ Patients with CVD must continue to adhere to their prescribed medication and monitoring regimens (eg, blood pressure, blood glucose monitoring) and seek advice when needed.

Medical help must be sought immediately when a person is experiencing chest pain, severe breathing difficulties, uncontrolled bleeding, or signs of stroke. Authors of a recent report from the United Kingdom found that patients with symptoms of an AMI ignored heart attack symptoms and delayed medical care because of fear of being exposed to COVID-19 and putting pressure on the already overburdened National Health Service.¹⁰² A massive decline in hospital admissions for ACS during the first wave of the pandemic and the government-implemented lockdown in the United Kingdom raised concerns regarding patients missing in-hospital assessment and rapid revascularization and early reperfusion therapies, particularly for those with signs of ST-elevation myocardial infarction. Delaying or missing treatment puts these patients at increased risk for out-of-hospital cardiac deaths and long-term complications of AMI.¹⁰³ Public campaigns and reminders for patients with heart attack symptoms to go to the hospital early can be useful in facilitating early assessment and instituting prompt interventions, including timely reperfusion if indicated.

Symptomatic patients presenting to clinics or being admitted to hospitals should undergo routine clinical investigations (ie, physical assessment, 12-lead electrocardiogram, chest radiographs, and biochemical tests), similar to those who are being admitted for any other reasons. Given, however, that hospital transmission of COVID-19 is high, patients with CVD should be protected from inadvertent exposure and infection by having their diagnostic procedures done in a clean, COVID-19-free area. Measures should be implemented to keep cardiac outpatient visits as short as possible, encourage and facilitate the use of telemedicine for follow-up checks, and delay elective procedures to minimize the risk of disease propagation and avoid overloading the health system.⁵³ The Table summarizes the list of diagnostic tools and modalities that are commonly used to investigate cardiovascular involvement in patients with COVID-19.

Table: Summary of Diagnostic Tools and Modalities Used in the Assessment and Evaluation of Cardiovascular Involvement in COVID-19

Modality	Indication	Nursing Implications
Chest imaging		
Chest radiograph	Useful for rapid evaluation of thoracic involvement in COVID-19 Aids in triaging and risk-stratification of patients, especially those awaiting or without swab results Can help detect pulmonary edema, effusions, and cardiomegaly	Radiologic imaging findings should be correlated with clinical and laboratory parameters. Risk of exposure, complications, and cross-infection should be balanced with benefits obtained from imaging findings.
Computed tomography	Useful in detection of early parenchymal disease Aids in screening and accelerates providing a diagnosis, especially with shortage or long waiting times for a polymerase chain reaction assay Useful in assessing severity of disease and enables surveillance of the disease time course Can aid in diagnosis of complications such as pulmonary embolus and ruling out other pathologies such as pulmonary nodules and other COVID-19 mimics	Less invasive measures should be used first.
Lung ultrasound	Useful in diagnosing pleural effusions, alveolar consolidation, and interstitial syndromes, because of its higher sensitivity, specificity, and diagnostic accuracy	
12-lead electrocardiogram		
	Useful for detection of myocardial injury, ischemia, and infarction Aids in diagnosis of conduction abnormalities and other aberrant cardiac rhythms (pre-excitation syndromes) Aids in diagnosing pericarditis, myocarditis, ventricular hypertrophy, and other chamber enlargement Aids in diagnosing electrolyte imbalances, other metabolic disorders, and drug toxicities Aids in evaluation of syncope and other vasovagal-related pathologies Can guide decision-making regarding selection and initiation of drug therapies for COVID-19 (eg, avoidance of QT-prolonging drugs in those with higher risks of arrhythmias) Aids in evaluation of effectiveness of pharmacotherapy (eg, use of β -blockers, antiarrhythmics)	Minimally invasive, almost no contraindications, cheap and easily accessible Electrocardiogram findings suggestive of myocardial ischemia should be investigated and all possible causes ruled out.
Laboratory tests		
Cardiac biomarkers	B-type natriuretic peptide and troponin I levels aid in diagnosing suspected acute cardiac injury, ACS, or AMI. Serial determination of high-sensitive troponin I level can be useful in ruling out cardiac causes of ischemia or chest pain.	Troponin is the recommended biomarker to identify myocardial injury, ACS, or AMI. Elevated troponin level can be used as a biomarker of disease severity and as a predictor of adverse outcomes in COVID-19.
Complete blood cell count	CBC can be used to provide a general picture of the patient's hematopoietic state, including presence of infection, inflammation, or anemia, and for monitoring response to treatment.	Common CBC count findings in COVID-19 include increased neutrophil count, reduced lymphocyte count, and anemia. CBC count results are poor prognostic indicators for COVID-19.
C-reactive protein	C-reactive protein determination is useful in identifying the presence of inflammation, determining its degree or severity, and monitoring response to treatment.	LDH is released during tissue damage; thus, serum LDH level reflects organ injury due to decreased oxygenation and can be used as a useful predictor of worse outcomes in COVID-19.
Lactate dehydrogenase	Serum LDH level is a nonspecific indicator of cellular death in many diseases and can be used as a useful marker of COVID-19 severity and risk for death.	

Continued

Table: Continued

Modality	Indication	Nursing Implications
Cardiac imaging studies		
Transthoracic and/or transe-sophageal echocardiogram	Useful in detecting and investigating the causes of left (myocardial infarction, myocarditis, Takotsubo cardiomyopathy) and right (right ventricular dilation, elevated pulmonary pressures) ventricular dysfunctions Useful in detecting valvular problems, heart failure, and pericardial effusion Aids in diagnosing endocarditis, myxoma, cardiac tamponade, and intracardiac thrombi Aids in investigating the causes of elevated cardiac biomarker levels in the absence of symptoms or electrocardiogram changes Facilitates guided titration of hemodynamic support, institution and adjustment of disease-specific therapies (heart failure, AMI), optimization of treatment (endocarditis), and admission to intensive care.	Nonurgent or elective cardiac imaging should not be routinely performed in the absence of a clinical indication. Imaging studies should be performed if the clinical management is likely to be affected by imaging results. Patients undergoing transesophageal echocardiogram should be tested for SARS-CoV-2, because the procedure is highly aerosol generating. Scanning time for an echocardiogram should be shortened to avoid prolonged exposure but should attempt to achieve high-quality recording.
Cardiac computed tomography	Useful for selected patients who have elevated levels of cardiac biomarkers (acute cardiac injury), inconclusive echocardiograms, and signs and symptoms of an ACS to rule out coronary artery disease Remains the preferred modality for diagnosis and ruling out the presence of an intracardiac thrombus Useful adjunct for evaluating patients who are planning to have urgent cardiac procedures, including transcatheter aortic valve replacement, cardioversion, or ablation Useful for diagnosing coronary artery stenosis, valve dysfunctions, coronary dissection, and intracardiac device dysfunction Calcium-score screening heart scan can be used to detect calcium deposits in atherosclerotic plaques to evaluate risks of coronary artery disease Aids in determining extracardiac causes of chest pain (eg, aortic dissection, hiatal hernia) and in detecting other pathologies (eg, pulmonary embolism) in high-risk patients with COVID-19	Risks involved in transport of critically ill patients, direct contamination from scans, and cross-infection to nurses, operators, and technicians should be balanced with the benefits of doing the procedure.

Abbreviations: ACS, acute coronary syndrome; AMI, acute myocardial infarction; CBC, complete blood cell; LDH, lactate dehydrogenase.

The British Society of Thoracic Imaging recommends that during the pandemic, patients with respiratory symptoms and high degree of clinical suspicion should have a chest radiograph done as the first-line imaging intervention.¹⁰⁴ Imaging findings can be useful in facilitating quick triaging of patients, particularly of those presenting to the emergency department with unknown COVID-19 status or who are awaiting a definitive diagnosis (ie, a polymerase chain reaction assay result). The American College of Radiology, in line with the Centers for Disease Control and Prevention, however, does not recommend chest radiographs or computed tomography (CT) to diagnose COVID-19 and only recommends CT imaging

be used sparingly and reservedly for hospitalized, symptomatic patients with specific clinical indications.¹⁰⁵ The use of chest imaging for diagnosis is complicated because COVID-19-related pneumonia may not be easily visible on chest radiograph, even in those presenting with respiratory symptoms. In a large, single-center US study, 58.3% of patients with COVID-19 had normal chest radiographs, suggesting that chest radiography, as a lone modality, may not be specific enough to either diagnose COVID-19 or rule out COVID-19.¹⁰⁶

In China, where patients are encouraged to seek care early in the course of disease, chest radiographs are of little diagnostic value, and chest CT remains the more preferred initial

imaging modality.¹⁰⁴ Chest CT scans are more sensitive for detecting early parenchymal disease and is more useful for tracking disease progression and excluding alternate diagnosis, including myocardial pathologies.¹⁰⁷ Its routine utility, however, is limited by cost, availability, expertise in interpretation, time required to clean and disinfect the equipment, and exposure to contrast or radiation.¹⁰⁸ The recommended use of chest radiography and CT varies regionally; thus, clinicians should follow established guidelines within their area of practice. The choice of imaging should be guided by the clinical utility of the procedure and the risk of cross-infection involved; for instance, the risks of aerosol generation and additional support required in transporting intubated patients to a CT facility are significantly higher than when a portable chest radiograph is done at the patient's bedside.¹⁰⁴

Routine 12-lead electrocardiography is an extremely valuable diagnostic tool for assessing and diagnosing the extent of cardiac involvement in COVID-19 and has the advantage of cost, accessibility, noninvasiveness, and high specificity in ruling out cardiac pathologies. All patients presenting with angina, chest discomfort, or other symptoms presumptive of an ACS or an acute cardiac injury should have a 12-lead electrocardiogram reading at the initial onset of symptoms, and all ST-segment changes (depression or elevation), T-wave inversions, and presence of Q waves be investigated further to rule out ACS or evolving myocardial infarction. Appropriate and timely recognition of electrocardiogram changes indicative of myocardial ischemia is essential because immediate management and treatment (ie, early revascularization and reperfusion) is lifesaving and crucial to prevent long-term, disabling complications.¹⁰³ Patients with myocarditis may present with ST-segment changes, tachyarrhythmias, T-wave abnormalities, bradyarrhythmias, and conduction defects such as intraventricular conduction delays and branch blocks.¹⁰⁹ These electrocardiogram abnormalities, however, lack sensitivity and specificity for diagnosing myocarditis and, therefore, must be correlated with clinical symptoms, because there is a potential overlap in symptoms of primary COVID-19 infection and COVID-19 myocarditis.⁶⁰ Patients with COVID-19 receiving QT-prolonging medications should be monitored closely and preemptive discontinuation of proarrhythmic

drugs may be beneficial to prevent precipitating fatal arrhythmias and cardiac death.^{89,93}

Laboratory tests and biomarkers play an important role in the detection, diagnosis, and management of COVID-19, and certain cardiac, inflammatory, thrombotic, and immunologic blood tests can be helpful in predicting the course, severity, and outcome of the disease.¹¹⁰ Early in the pandemic, levels of HF biomarkers, including troponin and B-type natriuretic peptide, were noted to be elevated in severely ill patients, strongly suggesting that the extent of myocardial injury can be predictive of poor disease outcomes.¹¹¹ Indeed, in a recent meta-analysis, authors reported that higher troponin levels, which are more commonly observed in severely ill patients and in those who died, can be used as an important tool in predicting the risk of death due to COVID-19.¹¹² Some other hematologic parameters commonly abnormal in COVID-19 include elevated levels of C-reactive protein, lactate dehydrogenase (LDH) and transaminases, and a low white blood cell count.^{110,113} Serum LDH level is a sensitive indicator of the cellular metabolic state (ie, aerobic and anaerobic direction of glycolysis) and is a non-specific indicator of cellular death and turnover in many diseases, because it is released in the bloodstream when there is actual tissue damage.¹¹⁴ Serum LDH levels may be useful as a marker for evaluating COVID-19 severity and for monitoring treatment response in COVID-19 pneumonia. In addition, measurement of serum LDH levels potentially may be useful for risk stratification and predicting in-hospital outcomes.¹¹⁵ It appears prudent that all patients with COVID-19 undergo a battery of laboratory examinations that include a complete blood cell count with differentials; measurement of levels of serum electrolytes, serum LDH, and troponin I; liver function tests; and kidney function tests to aid diagnosis, management, and treatment of the disease.

Cardiac imaging (eg, echocardiography, cardiac CT scans, cardiac ultrasound) of patients with COVID-19 should be performed if there is clinical benefit and only if it is likely to substantially change patient treatment or be lifesaving.^{116,117} Echocardiography has been helpful in studying hemodynamics in patients with AMI, myocarditis, and cardiogenic shock, and can be useful for quantifying systolic and diastolic function, wall-motion abnormality, ventricular performance, ejection fraction,

wall thickness, and presence of pericardial effusion. Hemodynamic surrogate information derived from imaging data can aid disease management and decision-making at the bedside, including selection of appropriate pharmacologic options, or as an adjunct to other invasive therapies (eg, quantification of pericardial effusion for drainage, or a revascularization procedure in the presence of regional wall-motion abnormality).¹¹⁸ Cardiac CT imaging is useful for investigating the causes of elevated biomarker levels, diagnosing valvular and cardiac device problems, and detecting or ruling out the presence of an intracardiac thrombus.¹¹⁷ The benefits of imaging studies for patient with confirmed or suspected COVID-19 should be balanced with the risk of inadvertent exposure to the operator (eg, aerosolization can occur in transesophageal echocardiography), misuse of resources, and contamination risks to patients.¹¹⁷ In the presence of a clinical indication, patients should undergo the least invasive imaging modality available, using facilities and equipment that are properly disinfected, in a dedicated facility or a room where the risk of spread is minimal, and using proper personal protective equipment throughout the procedure.

Nursing Management Implications

The treatment and care of patients with COVID-19 who have cardiac involvement is a major challenge for all health care professionals, because a vast majority of these patients require critical care services and intensive care beds. According to a recent report from the United Kingdom, two-thirds of patients with COVID-19 who required critical care admission received mechanical ventilatory support within 24 hours of admission, and a considerable percentage of these patients presented with cardiovascular symptoms.¹¹⁹ This observation has specific implications for nursing care, because nurses must deal with more than the usual number of medically complex patients with multiple organ involvement requiring specialist care and interventions. With increased demand for beds, increasing volumes of cases, limited numbers of qualified critical care staff, and high sickness rates among health care professionals, delivery of high-quality intensive nursing care will require practical and creative efforts, strategies, and solutions.

The nurse's main role in the management and care of a patient with a cardiac condition and COVID-19 is to ensure safe and timely delivery of care even when the ideal staffing ratio needs to be temporarily set aside.¹²⁰ Because these patients usually are the sickest patient subset during this pandemic, meticulous, individualized patient assessment and prompt institution of life-saving interventions are paramount; the risks of deterioration in these patients can lead to catastrophic outcomes.

All patients with cardiac conditions and COVID-19 ideally should be placed in a monitored bed with facilities for continuous 5- or 12-lead electrocardiogram, and blood pressure and pulse oximetry monitoring. Intravenous access should always be available, and for patients requiring inotropes, vasopressors, inodilators, antiarrhythmics, and other cardiac medications, a central venous access device with multiple lumens or ports for simultaneous infusions and access for blood sampling is recommended. Patients who are hemodynamically unstable or require significant pharmacologic or mechanical support to maintain cardiovascular stability may benefit from a cardiac-output monitoring device (eg, pulmonary artery catheter, pulse contour cardiac output, lithium dilution cardiac output) to guide management and evaluate effectiveness of interventions. Access to and availability of facilities to provide more invasive cardiorespiratory support (eg, cardiac catheterization, pacing, intra-aortic balloon counterpulsation, extracorporeal membrane oxygenation, ventricular assist devices, operating rooms) should be included in the care planning, because these interventions may be required in patients who are in cardiogenic shock, decompensated HF, or severe myocardial ischemia.

Most patients with COVID-19 with cardiac involvement are at higher-than-usual risk of deteriorating clinically; therefore, drugs and equipment for resuscitation, including for establishing an artificial airway and mechanical ventilatory support, should be readily accessible at the bedside. Identifying the "sickest" patients in the unit should be a part of the daily handover to ensure safe allocation of skill mix and allow increased frequency of monitoring. The goals and plan of care should be reviewed regularly with the medical team and communicated to the rest of the staff to ensure care is delivered within agreed time frames and

unexpected deviances are promptly addressed. Effective care planning with collaboration and active involvement of the multidisciplinary team is crucial because it facilitates continuity of care, teamwork, accountability, and better outcomes for patients.¹²¹

Conclusion

Our current understanding of the pathophysiology of COVID-19 infection is rapidly evolving, and although more is learned and discovered every day, there is still a lot that is unknown about the disease and the virus that causes it. SARS-CoV-2 can invade various cell types, resulting in organ-specific impairment; similarly, the virus can elicit a whole-body response mediated by an uncontrolled inflammatory process.⁴⁹⁻⁵⁰ In vivo and in vitro studies have been helpful in furthering our understanding of the molecular and cellular mechanisms of disease causation, and epidemiologic studies have been beneficial in discovering novel signs and symptoms that are unique to the disease and may have important diagnostic significance.

Despite being a disease that primarily targets the respiratory system, there is increasing recognition that COVID-19 also affects the cardiovascular system, and this has important implications for patient care and treatment. Cardiovascular diseases rank as the number 1 cause of death globally, with an estimate of 17.9 million people dying each year—an estimated 31% of all deaths worldwide.¹²² The risk factors for CVD are also increasing worldwide, and the economic burden, societal cost, and health care demands of a CVD diagnosis remain substantial, particularly in poorer countries where medical and human resources are scarce.¹²³ Given that the complications and outcomes of COVID-19 in patients with CVD are catastrophic, efforts should be made to develop safe, timely, effective, and evidence-based interventions aimed at improving patient outcomes. Collaboration among researchers and clinicians in all disciplines is crucial if we are to further our understanding of COVID-19 pathways and causation, and use this knowledge to develop treatments, interventions, and preventive actions to address this complex disease.

ACKNOWLEDGMENTS

The author acknowledges the valiant and selfless efforts of all nurses and frontline workers worldwide

who are battling the COVID-19 pandemic. The author also acknowledges his colleagues at Barts Heart Centre, Adult Critical Care Unit, St Bartholomew's Hospital, for their invaluable support. This manuscript is dedicated to all the amazing nurses, including those who have died during this pandemic.

REFERENCES

- Huang C, Wang Y, Li X, et al. Clinical features of patients infected with 2019 novel coronavirus in Wuhan, China. *Lancet*. 2020;395(10223):497-506.
- World Health Organization. Pneumonia of unknown cause—China. January 5, 2020. Accessed October 1, 2020. <https://www.who.int/csr/don/05-january-2020-pneumonia-of-unknown-cause-china/en>
- Zhou P, Yang X, Wang X, et al. A pneumonia outbreak associated with a new coronavirus of probable bat origin. *Nature*. 2020;579:270-273.
- Kaur N, Singh R, Dar Z, et al. Genetic comparison among various coronavirus strains for the identification of potential vaccine targets of SARS-CoV2. *Infect Genet Evol*. 2020;104490.
- Lu R, Zhao X, Li J, et al. Genomic characterisation and epidemiology of 2019 novel coronavirus: implications for virus origins and receptor binding. *Lancet*. 2020;395(10224):565-574.
- Coronaviridae Study Group of the International Committee on Taxonomy of Viruses. The species severe acute respiratory syndrome-related coronavirus: classifying 2019-nCoV and naming it SARS-CoV-2. *Nat Microbiol*. 2020;5(4):536-544.
- Pal M, Berhanu G, Desalegn C, et al. Severe acute respiratory syndrome coronavirus-2 (SARS-CoV-2): an update. *Cureus*. 2020;12(3):e7423.
- Zhu N, Wang W, Liu Z, et al. Morphogenesis and cytopathic effect of SARS-CoV-2 infection in human airway epithelial cells. *Nat Commun*. 2020;11(1):3910.
- Wang LF, Shi Z, Zhang S, et al. Review of bats and SARS. *Emerg Infect Dis*. 2006;12(12):1834-1840.
- Mohd HA, Al-Tawfiq JA, Memish ZA. Middle East respiratory syndrome coronavirus (MERS-CoV) origin and animal reservoir. *Virology*. 2016;13:87.
- Lam TT, Jia N, Zhang YW, et al. Identifying SARS-CoV-2-related coronaviruses in Malayan pangolins. *Nature*. 2020;583(7815):282-285.
- Cohen J. Mining coronavirus genomes for clues to the outbreak's origins. *Science*. Accessed October 1, 2020. <https://www.sciencemag.org/news/2020/01/mining-coronavirus-genomes-clues-outbreak-s-origins>
- Kampf G, Todt G, Pfaender S, Steinmann E. Persistence of coronaviruses on inanimate surfaces and their inactivation with biocidal agents. *J Hosp Infect*. 2020;104(3):246-251.
- Jayaweera M, Perera H, Gunawardana B, Manatunge J. Transmission of COVID-19 virus by droplets and aerosols: a critical review on the unresolved dichotomy. *Environ Res*. 2020;188:109819.
- Thomas R. Particle size and pathogenicity in the respiratory tract. *Virulence*. 2013;4(8):847-858.
- Judson SD, Munster VJ. Nosocomial transmission of emerging viruses via aerosol-generating medical procedures. *Viruses*. 2019;11(10):940.
- Rabenau HF, Cinatl J, Morgenstern B, et al. Stability and inactivation of SARS coronavirus. *Med Microbiol Immunol*. 2005;194(1-2):1-6.
- Goldman E. Exaggerated risk of transmission of COVID-19 by fomites. *Lancet Infect Dis*. 2020;20(8):892-893.
- Shang J, Ye G, Shi K, et al. Structural basis of receptor recognition by SARS-CoV-2. *Nature*. 2020;581:221-224.
- Ortega JT, Serrano ML, Pujol FH, Rangel HR. Role of changes in SARS-CoV-2 spike protein in the interaction with the human ACE2 receptor: an in silico analysis. *EXCLI J*. 2020;19:410-417.

21. Hoffmann M, Kleine-Weber H, Schroeder S, et al. SARS-CoV-2 cell entry depends on ACE2 and TMPRSS2 and is blocked by a clinically proven protease inhibitor. *Cell*. 2020;181(2):271-280.e8.
22. McKee DL, Sternberg A, Stange U, et al. Candidate drugs against SARS-CoV-2 and COVID-19. *Pharmacol Res*. 2020;157:104859.
23. Coutard B, Valle C, de Lamballerie X, et al. The spike glycoprotein of the new coronavirus 2019-nCoV contains a furin-like cleavage site absent in CoV of the same clade. *Antiviral Res*. 2020;176:104742.
24. Izaguirre G. The proteolytic regulation of virus cell entry by furin and other proprotein convertases. *Viruses*. 2019;11(9):837.
25. Kumar S, Zhi K, Mukherji A, Gerth K. Repurposing antiviral protease inhibitors using extracellular vesicles for potential therapy of COVID-19. *Viruses*. 2020;12(5):486.
26. Hamming I, Timens W, Bulthuis ML, et al. Tissue distribution of ACE2 protein, the functional receptor for SARS coronavirus. A first step in understanding SARS pathogenesis. *J Pathol*. 2004;203(2):631-637.
27. Sims AC, Baric RS, Yount B, et al. Severe acute respiratory syndrome coronavirus infection of human ciliated airway epithelia: role of ciliated cells in viral spread in the conducting airways of the lungs. *J Virol*. 2005;79(24):15511-15524.
28. Nicin L, Abplanalp WT, Mellentin H, et al. Cell type-specific expression of the putative SARS-CoV-2 receptor ACE2 in human hearts. *Eur Heart J*. 2020;41(19):1804-1806.
29. Perico L, Benigni A, Remuzzi G. Should COVID-19 concern nephrologists? Why and to what extent? The emerging impasse of angiotensin blockade. *Nephron*. 2020;144(5):213-221.
30. Kabbani N, Olds JL. Does COVID-19 infect the brain? If so, smokers might be at a higher risk. *Mol Pharmacol*. 2020;97(5):351-353.
31. Carey R. AT2 Receptors: potential therapeutic targets for hypertension. *Am J Hypertension*. 2017;30(4):339-347.
32. Dendorfer A, Thornagel A, Raasch W, et al. Angiotensin II induces catecholamine release by direct ganglionic excitation. *Hypertension*. 2002;40(3):348-354.
33. Berk BC, Corson MA. Angiotensin II signal transduction in vascular smooth muscle: role of tyrosine kinases. *Circ Res*. 1997;80(5):607-616.
34. Ferrario C, Chappell M, Tallant E, et al. Counter-regulatory actions of angiotensin-(1-7). *Hypertension*. 1997;30(3 pt 2):535-541.
35. Kuba K, Imai Y, Penninger JM. Multiple functions of angiotensin-converting enzyme 2 and its relevance in cardiovascular diseases. *Circ J*. 2013;77:301-308.
36. Silva GM, França-Falcão MS, Calzerra NTM, et al. Role of renin-angiotensin system components in atherosclerosis: focus on Ang-II, ACE2, and Ang-1-7. *Front Physiol*. 2020;11:1067.
37. Benigni A, Cassis P, Remuzzi G. Angiotensin II revisited: new roles in inflammation, immunology and aging. *EMBO Mol Med*. 2010;2(7):247-257.
38. Satou R, Penrose H, Navar LG. Inflammation as a regulator of the renin-angiotensin system and blood pressure. *Curr Hypertens Rep*. 2018;20(12):100.
39. Bernstein KE, Khan Z, Gianì JF, et al. Angiotensin-converting enzyme in innate and adaptive immunity. *Nat Rev Nephrol*. 2018;14(5):325-336.
40. Kuba K, Imai Y, Rao S, et al. A crucial role of angiotensin converting enzyme 2 (ACE2) in SARS coronavirus-induced lung injury. *Nat Med*. 2005;11(8):875-879.
41. Mason RJ. Pathogenesis of COVID-19 from a cell biology perspective. *Eur Respir J*. 2020;55(4):2000607.
42. Jia HP, Look DC, Shi L, et al. ACE2 receptor expression and severe acute respiratory syndrome coronavirus infection depend on differentiation of human airway epithelia. *J Virol*. 2005;79(23):14614-14621.
43. Guan WJ, Ni ZY, Hu Y, et al. Clinical characteristics of coronavirus disease 2019 in China. *N Engl J Med*. 2020;382(18):1708-1720.
44. Gallelli L, Zhang L, Wang T, et al. Severe acute lung injury related to COVID-19 infection: a review and the possible role for Escin. *J Clin Pharmacol*. 2020;60(7):815-825.
45. Grasselli G, Tonetti T, Protti A, et al. Pathophysiology of COVID-19-associated acute respiratory distress syndrome: a multicentre prospective observational study. *Lancet Respir Med*. 2020;8(12):1201-1208.
46. Carsana L, Sonzogni A, Nasr A, et al. Pulmonary post-mortem findings in a series of COVID-19 cases from northern Italy: a two-centre descriptive study. *Lancet Infect Dis*. 2020;20(10):1135-1140.
47. Ackermann M, Verleden SE, Kuehnel M, et al. Pulmonary vascular endothelialitis, thrombosis, and angiogenesis in COVID-19. *N Engl J Med*. 2020;383(2):120-128.
48. Magro C, Mulvey JJ, Berlin D, et al. Complement associated microvascular injury and thrombosis in the pathogenesis of severe COVID-19 infection: a report of five cases. *Transl Res*. 2020;220:1-13.
49. Huang L, Zhao X, Qi Y, et al. Sepsis-associated severe interleukin-6 storm in critical coronavirus disease 2019. *Cell Mol Immunol*. 2020;17(10):1092-1094.
50. Ye Q, Wang B, Mao J. The pathogenesis and treatment of the 'cytokine storm' in COVID-19. *J Infect*. 2020;80(6):607-613.
51. Grifoni E, Valoriani A, Cei F, et al. Interleukin-6 as prognosticator in patients with COVID-19. *J Infect*. 2020;81(3):452-482.
52. Zhang C, Wu Z, Li JW, et al. Cytokine release syndrome in severe COVID-19: interleukin-6 receptor antagonist tocilizumab may be the key to reduce mortality. *Int J Antimicrob Agents*. 2020;55(5):105954.
53. The European Society for Cardiology. ESC guidance for the diagnosis and management of CV disease during the COVID-19 pandemic. Updated June 10, 2020. Accessed January 15, 2021. <https://www.escardio.org/Education/COVID-19-and-Cardiology/ESC-COVID-19-Guidance>
54. Shaha KB, Manandhar DN, Cho JR, et al. COVID-19 and the heart: what we have learnt so far. *Postgrad Med J*. Published September 17, 2020. doi:10.1136/postgradmedj-2020-138284
55. Garg S, Kim L, Whitaker M, et al. Hospitalization rates and characteristics of patients hospitalized with laboratory-confirmed coronavirus disease 2019— COVID-NET, 14 states, March 1-30, 2020. *MMWR Morb Mortal Wkly Rep*. 2020;69(15):458-464.
56. Wu Z, McGoogan JM. Characteristics of and important lessons from the coronavirus disease 2019 (COVID-19) outbreak in China: summary of a report of 72 314 cases from the Chinese Center for Disease Control and Prevention. *JAMA*. 2020;323(13):1239-1242.
57. Richardson S, Hirsch JS, Narasimhan M, et al. Presenting characteristics, comorbidities, and outcomes among 5700 patients hospitalized with COVID-19 in the New York City area. *JAMA*. 2020;323(20):2052-2059.
58. Sabatino J, De Rosa S, Di Salvo G, Indolfi C. Impact of cardiovascular risk profile on COVID-19 outcome. A meta-analysis. *PLoS One*. 2020;15(8):e0237131.
59. Basu-Ray I, Almaddah Nk, Adebayo A, et al. Cardiac manifestations of coronavirus. StatPearls Publishing; 2020. Updated August 8, 2020. Accessed January 15, 2021. <https://www.ncbi.nlm.nih.gov/books/NBK556152>
60. Pirzada A, Mokhtar AT, Moeller AD. COVID-19 and myocarditis: what do we know so far? *CJC Open*. 2020;2(4):278-285.
61. Shi S, Qin M, Shen B, et al. Association of cardiac injury with mortality in hospitalized patients with COVID-19 in Wuhan, China. *JAMA Cardiol*. 2020;5(7):802-810.

62. Guo T, Fan Y, Chen M, et al. Cardiovascular implications of fatal outcomes of patients with coronavirus disease 2019 (COVID-19). *JAMA Cardiol.* 2020;5(7):811-818.
63. Ammirati E, Wang DW. SARS-CoV-2 inflames the heart. The importance of awareness of myocardial injury in COVID-19 patients. *Int J Cardiol.* 2020;311:122-123.
64. Caforio A, Pankuweit S, Arbustini E, et al. Current state of knowledge on aetiology, diagnosis, management, and therapy of myocarditis: a position statement of the European Society of Cardiology Working Group on Myocardial and Pericardial Diseases. *Eur Heart J.* 2013;34(33):2636-2648.
65. Dennert R, Crijns HJ, Heymans S. Acute viral myocarditis. *Eur Heart J.* 2008;29(17):2073-2082.
66. Yajima T, Knowlton KU. Viral myocarditis: from the perspective of the virus. *Circulation.* 2009;119(19):2615-2624.
67. Siripanthong B, Nazarian S, Muser D, et al. Recognizing COVID-19-related myocarditis: the possible pathophysiology and proposed guideline for diagnosis and management. *Heart Rhythm.* 2020;17(9):1463-1471.
68. Farcas GA, Poutanen SM, Mazzulli T, et al. Fatal severe acute respiratory syndrome is associated with multiorgan involvement by coronavirus. *J Infect Dis.* 2005;191(2):193-197.
69. Tao X, Garron T, Agrawal AS, et al. Characterization and demonstration of the value of a lethal mouse model of Middle East respiratory syndrome coronavirus infection and disease. *J Virol.* 2015;90(1):57-67.
70. Goulter AB, Goddard MJ, Allen JC, Clark KL. ACE2 gene expression is up-regulated in the human failing heart. *BMC Med.* 2004;2:19.
71. Kai H, Kai M. Interactions of coronaviruses with ACE2, angiotensin II, and RAS inhibitors—lessons from available evidence and insights into COVID-19. *Hypertens Res.* 2020;43(7):648-654.
72. Tavazzi G, Pellegrini C, Maurelli M, et al. Myocardial localization of coronavirus in COVID-19 cardiogenic shock. *Eur J Heart Fail.* 2020;22(5):911-915.
73. Dolhnikoff M, Ferreira Ferranti J, de Almeida Monteiro RA, et al. SARS-CoV-2 in cardiac tissue of a child with COVID-19-related multisystem inflammatory syndrome. *Lancet Child Adolesc Health.* 2020;4(10):790-794.
74. Chen L, Li X, Chen M, et al. The ACE2 expression in human heart indicates new potential mechanism of heart injury among patients infected with SARS-CoV-2. *Cardiovasc Res.* 2020;116(6):1097-1100.
75. Zhu H, Rhee JW, Cheng P, et al. Cardiovascular complications in patients with COVID-19: consequences of viral toxicities and host immune response. *Curr Cardiol Rep.* 2020;22(5):32.
76. Collins SD. Excess mortality from causes other than influenza and pneumonia during influenza epidemics. *Public Health Rep.* 1932;47(46):2159-2180.
77. Barnes M, Heywood AE, Mahimbo A, et al. Acute myocardial infarction and influenza: a meta-analysis of case-control studies. *Heart.* 2015;101(21):1738-1747.
78. Putot A, Chague F, Manckoundia P, et al. Post-infectious myocardial infarction: new insights for improved screening. *J Clin Med.* 2019;8(6):827.
79. Muscente F, De Caterina R. Causal relationship between influenza infection and risk of acute myocardial infarction: pathophysiological hypothesis and clinical implications. *Eur Heart J Suppl.* 2020;22(suppl E):E68-E72.
80. Virmani R, Burke AP, Farb A, et al. Pathology of the vulnerable plaque. *J Am Coll Cardiol.* 2006;47(8 suppl):C13-C18.
81. Rey JR, Caro-Codón J, Rosillo SO, et al. Heart failure in COVID-19 patients: prevalence, incidence and prognostic implications. *Eur J Heart Fail.* 2020;22(12):2205-2215.
82. Zhou F, Yu T, Du R, et al., Clinical course and risk factors for mortality of adult inpatients with COVID-19 in Wuhan, China: a retrospective cohort study. *Lancet.* 2020;395(10229):1054-1062.
83. Mehra MR, Ruschitzka F. COVID-19 illness and heart failure: a missing link? *JACC Heart Fail.* 2020;8(6):512-514.
84. Sisti N, Valente S, Mandoli GE, et al. COVID-19 in patients with heart failure: the new and the old epidemic. *Postgrad Med J.* 2021;97(1145):175-179.
85. van den Borne SW, Diez J, Blankestijn WM, Verjans J, Hofstra L, Narula J. Myocardial remodeling after infarction: the role of myofibroblasts. *Nat Rev Cardiol.* 2010;7(1):30-37.
86. Unudurthi SD, Luthra P, Bose RJC, McCarthy JR, Kontraris MI. Cardiac inflammation in COVID-19: lessons from heart failure. *Life Sci.* 2020;260:118482.
87. Babapoor-Farrokhran S, Rasekhi RT, Gill D, Babapoor S, Amanullah A. Arrhythmia in COVID-19. *SN Compr Clin Med.* 2020;2:1430-1435.
88. Liu K, Fang YY, Deng Y, et al. Clinical characteristics of novel coronavirus cases in tertiary hospitals in Hubei Province. *Chin Med J (Engl).* 2020;133(9):1025-1031.
89. Bhatla A, Mayer MM, Adusumalli S, et al. COVID-19 and cardiac arrhythmias. *Heart Rhythm.* 2020;17(9):1439-1444.
90. Chigr F, Merzouki M, Najimi M. Comment on "The neuroinvasive potential of SARS-CoV-2 may play a role in the respiratory failure of COVID-19 patients." *J Med Virol.* 2020;92(7):703-704.
91. Saleh M, Gabriels J, Chang D, et al. Effect of chloroquine, hydroxychloroquine, and azithromycin on the corrected QT interval in patients with SARS-CoV-2 infection. *Circ Arrhythm Electrophysiol.* 2020;13(6):e008662.
92. van den Broek MPH, Möhlmann JE, Abeln BGS, et al. Chloroquine-induced QTc prolongation in COVID-19 patients. *Neth Heart J.* 2020;28(7-8):406-409.
93. Nachimuthu S, Assar MD, Schussler JM. Drug-induced QT interval prolongation: mechanisms and clinical management. *Ther Adv Drug Saf.* 2012;3(5):241-253.
94. Merrill JT, Erkan D, Winakur J, James JA. Emerging evidence of a COVID-19 thrombotic syndrome has treatment implications. *Nat Rev Rheumatol.* 2020;16(10):581-589.
95. Fox SE, Akmatbekov A, Harbert JL, et al. Pulmonary and cardiac pathology in African American patients with COVID-19: an autopsy series from New Orleans. *Lancet Respir Med.* 2020;8(7):681-686.
96. Wichmann D, Sperhake JP, Lütgehetmann M, et al. Autopsy findings and venous thromboembolism in patients with COVID-19: a prospective cohort study. *Ann Intern Med.* 2020;173(4):268-277.
97. Tang N, Bai H, Chen X, Gong J, Li D, Sun Z. Anticoagulant treatment is associated with decreased mortality in severe coronavirus disease 2019 patients with coagulopathy. *J Thromb Haemost.* 2020;18(5):1094-1099.
98. Connors JM, Levy JH. COVID-19 and its implications for thrombosis and anticoagulation. *Blood.* 2020;135(23):2033-2040.
99. Varga Z, Flammer AJ, Steiger P, et al. Endothelial cell infection and endotheliitis in COVID-19. *Lancet.* 2020;395(10234):1417-1418.
100. McGonagle D, Sharif K, O'Regan A, Bridgewood C. The role of cytokines including interleukin-6 in COVID-19 induced pneumonia and macrophage activation syndrome-like disease. *Autoimmun Rev.* 2020;19(6):102537.
101. Lillcrap D. Disseminated intravascular coagulation in patients with 2019-nCoV pneumonia. *J Thromb Haemost.* 2020;18(4):786-787.
102. Pessoa-Amorim G, Camm CF, Gajendragadkar P, et al. Admission of patients with STEMI since the outbreak of the COVID-19 pandemic: a survey by the European Society of Cardiology. *Eur Heart J Qual Care Clin Outcomes.* 2020;6(3):210-216.
103. Mafham MM, Spata E, Goldacre R, et al. COVID-19 pandemic and admission rates for and management of acute coronary syndromes in England. *Lancet.* 2020;396(10248):381-389.

104. Cleverley J, Piper J, Jones MM. The role of chest radiography in confirming COVID-19 pneumonia. *BMJ*. 2020;370:m2426.
105. Myers L, Balakrishnan S, Reddy S, Gholamrezanezhad A. Coronavirus outbreak: is radiology ready? Mass casualty incident planning. *J Am Coll Radiol*. 2020; 17(6):724-729.
106. Tsakok M, Shaw R, Murchison A, et al. Diagnostic accuracy of initial chest radiograph compared to SARS-CoV-2 PCR in patients with suspected COVID-19. *BJR Open*. 2020;2(1):20200034.
107. Rubin GD, Ryerson CJ, Haramati LB, et al. The role of chest imaging in patient management during the COVID-19 pandemic: a multinational consensus statement from the Fleischner Society. *Chest*. 2020;158(1): 106-116.
108. Borakati A, Perera A, Johnson J, et al. Diagnostic accuracy of X-ray versus CT in COVID-19: a propensity-matched database study. *BMJ Open*. 2020;10:e042946.
109. Haseeb S, Gul EE, Çinier G, et al. Value of electrocardiography in coronavirus disease 2019 (COVID-19). *J Electrocardiol*. 2020;62:39-45.
110. Lanini S, Montaldo C, Nicastrì E, et al. COVID-19 disease—temporal analyses of complete blood count parameters over course of illness, and relationship to patient demographics and management outcomes in survivors and non-survivors: a longitudinal descriptive cohort study. *PLoS ONE*. 2020;15(12):e0244129.
111. Pranata R, Huang I, Lukito AA, et al. Elevated N-terminal pro-brain natriuretic peptide is associated with increased mortality in patients with COVID-19: systematic review and meta-analysis. *Postgrad Med J*. 2020;96:387-391.
112. Dawson D, Dominic P, Sheth A, Modi M. Prognostic value of cardiac biomarkers in COVID-19 infection: a meta-analysis. Preprint. *Res Sq*. 2020;rs.3.rs-34729.
113. Jurisic V, Radenkovic S, Konjevic G. The actual role of LDH as tumor marker, biochemical and clinical aspects. In: Scatena R. (ed). *Advances in Cancer Biomarkers. Advances in Experimental Medicine and Biology*. Vol. 867. Springer, Dordrecht; 2015. https://doi.org/10.1007/978-94-017-7215-0_8
114. Henry BM, Aggarwal G, Wong J, et al. Lactate dehydrogenase levels predict coronavirus disease 2019 (COVID-19) severity and mortality: a pooled analysis. *Am J Emerg Med*. 2020;38(9):1722-1726.
115. Wu M, Yao L, Wang Y, et al. Clinical evaluation of potential usefulness of serum lactate dehydrogenase (LDH) in 2019 novel coronavirus (COVID-19) pneumonia. *Respir Res*. 2020;21(1):171.
116. Skulstad H, Cosyns B, Popescu BA, et al. COVID-19 pandemic and cardiac imaging: EACVI recommendations on precautions, indications, prioritization, and protection for patients and healthcare personnel. *Eur Heart J Cardiovasc Imaging*. 2020;21(6):592-598.
117. Singh V, Choi AD, Leipsic J, et al. Use of cardiac CT amidst the COVID-19 pandemic and beyond: North American perspective. *J Cardiovasc Comput Tomogr*. 2021;15(1):16-26.
118. Capotosto L, Nguyen BL, Ciardi MR, Mastroianni C, Vitarelli A. Heart, COVID-19, and echocardiography. *Echocardiography*. 2020;37(9):1454-1464.
119. Mahase E. Covid-19: most patients require mechanical ventilation in first 24 hours of critical care. *BMJ*. 2020; 368:m1201.
120. Carter C, Nottter J. COVID-19 disease: a critical care perspective. *Clinics in Integrated Care*. 2020;1:100003.
121. Rosen MA, DiazGranados D, Dietz AS, et al. Teamwork in healthcare: key discoveries enabling safer, high-quality care. *Am Psychol*. 2018;73(4):433-450.
122. Virani SS, Alonso A, Benjamin EJ, et al. Heart disease and stroke statistics-2020 update: a report from the American Heart Association. *Circulation*. 2020;141(9): e139-e596.
123. Mensah GA, Roth GA, Fuster V. The global burden of cardiovascular diseases and risk factors: 2020 and beyond. *J Am Coll Cardiol*. 2019;74(20):2529-2532.