

Differential Effects of *Helicobacter pylori* Eradication on Oxidative DNA Damage at the Gastroesophageal Junction and at the Gastric Antrum

Fabio Farinati,¹ Romilda Cardin,¹ Valentina M. Russo,² Graziella Busatto,³ Monica Franco,¹ Alessandra Falda,¹ Claudia Mescoli,¹ and Massimo Rugge²

¹Dipartimento di Scienze Chirurgiche e Gastroenterologiche, Sezione di Gastroenterologia and ²Dipartimento di Scienze Oncologiche & Chirurgiche, III^o Cattedra Anatomia Patologica, Università degli Studi di Padova and ³Unità Operativa di Anatomia Patologica, Azienda Ospedaliera Alta Padovana, Ospedale di Cittadella, Padova, Italy

Abstract

Background and Aim: *Helicobacter pylori*-associated gastritis causes accumulation of reactive oxygen species in the mucosal compartment. This prospective study evaluates DNA oxidative damage in biopsy samples obtained from both the antrum and the gastroesophageal junction (GEJ) before and after *H. pylori* eradication.

Patients and Methods: Thirty-two consecutive *H. pylori*-positive patients underwent endoscopy with multiple biopsy sampling (i.e., antrum, incisura angularis, fundus, and cardia at the GEJ). After *H. pylori* eradication, 32 patients underwent a checkup endoscopy (mean interval, 5.7 months); in a subgroup of 13 subjects, a third endoscopy procedure was also performed (mean interval, 18 months). Additional biopsy samples (two from the antrum and two from the GEJ) were used to assess 8-hydroxydeoxyguanosine (8OHdG) levels using both high-pressure liquid chromatography with electrochemical detector and ELISA.

Results: In the antral compartment, no significant modifications of 8OHdG levels were assessed after *H. pylori* eradication. Conversely, following eradication, 8OHdG levels significantly increased (high-pressure liquid chromatography with electrochemical detector, $P = 0.04$; ELISA method, $P = 0.05$) in biopsy samples taken from the GEJ, and a further increase was documented in the subgroup of patients who underwent a third endoscopy ($P = 0.01$). The increasing trend was more relevant in patients in whom *H. pylori-cagA*-positive strains were eradicated and in those affected by hiatal hernia.

Conclusions: The levels of DNA adducts in the antral mucosa are not modified by *H. pylori* eradication; conversely, *H. pylori* eradication significantly increases the oxidative adducts at the GEJ. The clinical and biological importance of this situation and whether and how it relates to a higher risk of precancerous lesions is open to debate. (Cancer Epidemiol Biomarkers Prev 2004;13(11):1722-8)

Introduction

Reactive oxygen species (ROS) are a group of highly reactive oxidative molecules implicated in the aging process, in several chronic inflammatory disorders, and in carcinogenic pathways in different epithelial districts (1-3). An increase in cell ROS, be it due to overproduction and/or scavenging inability, may result in severe damage to various cell components, including membranes, mitochondria, and nuclear as well as mitochondrial DNA. ROS accumulation is well documented in carcinogenesis and may result in proto-oncogene activation, development of chromosomal imbalances, and DNA mutations (4, 5).

8-Hydroxydeoxyguanosine (8OHdG) is considered the main DNA modification induced by ROS and may be per se responsible for DNA base mutation; the ad-

duct can accumulate and is only partially repaired through enzyme pathways that may in turn cause further DNA damage (6). In previous studies, we showed a significant correlation between 8OHdG accumulation and *Helicobacter pylori*-related chronic gastritis, particularly gastric mucosa atrophy and intestinal metaplasia (IM; refs. 7-9).

Several studies suggest that *H. pylori* chronic gastritis, particularly when associated with *H. pylori-cagA*-positive infection, correlates inversely with severe reflux esophagitis, Barrett's esophagus, and a higher risk of distal esophageal and cardia adenocarcinoma (10-13). Increased intragastric ammonia production, acid-inhibiting cytokine release, gastric atrophy, and IM (14), which all promote hypoacidity, are most likely the mechanisms underlying this effect. Conversely, in some susceptible subjects, *H. pylori* eradication may adversely affect the clinicobiological outcome of the spectrum of lesions related to gastroesophageal reflux disease (GERD; refs. 15, 16). Recent studies implicate GERD and ROS accumulation in the etiopathogenesis of both Barrett's esophagus and distal esophageal adenocarcinoma (17, 18).

Received 7/7/03; revised 5/24/04; accepted 5/28/04.

The costs of publication of this article were defrayed in part by the payment of page charges. This article must therefore be hereby marked advertisement in accordance with 18 U.S.C. Section 1734 solely to indicate this fact.

Requests for reprints: Fabio Farinati, Dipartimento di Scienze Chirurgiche e Gastroenterologiche, Sezione di Gastroenterologia, Policlinico Universitario, Via Giustiniani 2, 35128 Padova, Italy. Phone: 39-49-8211305; Fax: 39-49-8760820. E-mail: fabio.farinati@unipd.it

Copyright © 2004 American Association for Cancer Research.

The aim of this prospective follow-up study was to evaluate oxidative DNA damage in antral and gastroesophageal junction (GEJ) mucosa before and after *H. pylori* eradication.

Patients and Methods

Patients. All patients involved in this prospective study gave their written consent to undergo the initial and follow-up endoscopy procedures with multiple biopsy sampling for both therapeutic and research purposes. The study was approved by the Human Research Committee of the University of Padova.

The study involved 32 consecutive *H. pylori*-positive patients (14 males and 18 females; mean age, 52 ± 14 years) recruited at the outpatient clinic of the Gastroenterology Department of the Padova University Hospital where they presented for upper gastrointestinal tract symptoms (7 patients with heartburn, 11 patients with epigastric pain, 11 patients with dyspepsia, and 3 patients who reported a peptic ulcer history).

At enrollment, the *H. pylori* status had already been ascertained by the 13C breath test and confirmed by histology.

Patients who had been treated with antibiotics or taking drugs interfering with free radical production, such as nonsteroidal anti-inflammatory drugs or antioxidant supplements (including vitamins C, A, and E, selenium, and zinc) or similar nonprescription preparations, were excluded. The other exclusion criteria were any referred or clinically suspected alcohol abuse (defined as chronic consumption of ethanol exceeding 80 g/d in males and 40 g/d in females) and the assumption of proton pump inhibitors and/or anti-H2 receptor antagonists.

After the initial endoscopy (i.e., the first procedure), patients underwent *H. pylori* eradication administering a triple therapy consisting of omeprazole or derivatives (40 mg/d), clarithromycin (500 mg twice daily), and metronidazole (1 g/d) for 7 days. *H. pylori* clearance was consistently shown in all patients by the 13C breath test and biopsy samples obtained at the posteradication endoscopy (i.e., the second procedure), which was performed a mean (range) of 5.7 (3-17) months after the first procedure.

A subgroup of 13 of 32 patients accepted to undergo an additional endoscopy (i.e., the third procedure), performed according to the same protocol as the previous two. This third procedure was proposed at time 0 to all patients included, but only 13 accepted it. The mean (range) time elapsing from their enrollment to the third procedure was 18 (8-24) months. All the endoscopy procedure were performed by the same experienced endoscopist using Pentax endoscopes (Montvale, NJ). Esophagitis, when endoscopically detected, was classified according to the Los Angeles classification (19).

At endoscopy, after overall examination, at least two biopsy samples were taken for histologic assessment from each of the following mucosal areas: (a) antrum, (b) incisura angularis, (c) greater curvature, (d) cardia (i.e., the narrow mucosal strip that separates the most distal portion of the esophageal squamous mucosa from the

fundic mucosa; ref. 20), and (e) GEJ (i.e., the 2 cm of esophageal mucosa proximal to the cardia). To be more accurate in obtaining the cardia biopsy samples, the sampling procedure was performed with the endoscope in retroversion. For 8OHdG determination, two additional mucosal samples were obtained from both the antral and the GEJ mucosa.

Histology and *H. pylori* Genotyping. For histologic assessment, the biopsy samples were fixed in formalin, paraffin embedded, and cut into serial sections 5 μ m thick. Histologic specimens were stained with H&E and Alcian-periodic acid-Schiff. *H. pylori* was microscopically evaluated by modified Giemsa stain; in doubtful cases, the Warthin-Starry stain and/or immunostain (monoclonal antibodies applied according to the manufacturer's instructions; DAKO, Milan, Italy) were also used. All biopsies were simultaneously examined by two pathologists (V.M.R. and M.R.) in blind fashion, obtaining a consensus diagnosis and histologic score.

In accordance with international criteria, gastritis was basically classified as atrophic and nonatrophic, gastric atrophy being defined as loss of appropriate glands (21). Visual analogue scales (0, absent; 1, mild; 2, moderate; 3, severe) were used for reference in grading; (a) mononuclear cells infiltrate within the lamina propria; (b) activity (granulocyte infiltrate within and around glandular units); and (c) representation of IM (22).

Histologic specimens including squamous esophageal mucosa (i.e., biopsy samples taken from the area where columnar mucosa merges with or passes into the squamous esophageal epithelium, commonly identified as the GEJ) were evaluated separately. In these specimens, among the histologic features most frequently associated with GERD, the following morphologic alterations were considered: (a) squamous mucosal erosions, (b) mucosal papillary and/or proliferative zone (i.e., basal zone) expansion, and (c) leukocyte intraepithelial (i.e., intrasquamous) infiltrate (i.e., leukocyte exocytosis). Histology was considered consistent with reflux esophagitis when at least two of the above three features coexisted. Leukocyte exocytosis (mostly granulocytes) was histologically scored on a four-tiered scale (0, no intraepithelial leukocytes; 1, isolated leukocytes within the squamous epithelium; 2, occasional clusters of leukocytes within the squamous epithelium; 3, frequent clusters of leukocytes within and/or over the superficial layer of the squamous epithelium) (Fig. 1).

H. pylori genotyping (*cagA*-positive versus *cagA*-negative strains) was performed using a previously optimized molecular method, which has been described in detail elsewhere (23).

Gastrin, Pepsinogen A, Pepsinogen C, and Gastric Juice pH Determinations. To evaluate gastric mucosa function following eradication, in an attempt to confirm the histologic findings from the pathophysiologic point of view, we also decided to assess the behavior of pepsinogen A (PGA), pepsinogen C (PGC), gastrin, and gastric juice pH. Serum samples were also obtained at the patients' enrollment and at the time of their second and third (if any) endoscopies.

Serum gastrin (μ g/L) levels were determined using the standard technique optimized at our clinical chemistry laboratory, the reference range being 37 to 70 ng/L.

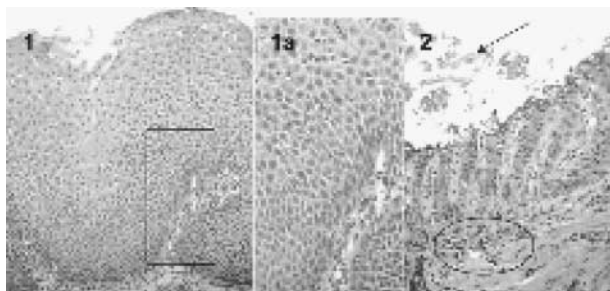


Figure 1. The histologic spectrum of GERD-related esophageal lesions (the most advanced stage of the esophageal ulcer is not shown). (1-1a) Mucosal proliferative zone (i.e., basal zone) expansion, coexisting with leukocyte intraepithelial (i.e., intrasquamous) infiltrate (see higher magnification in image 1a). Because of the presence of isolated leukocytes within the squamous epithelium, leukocyte exocytosis was scored as a grade 1 (see histologic methods). (2) Squamous mucosal erosion (i.e., erosive esophagitis) associated with expansion of the papillary zone of the esophageal mucosa. Necrotic debris are present over the surviving basal layer of the squamous epithelium (↑); within the submucosa, clusters of leukocytes are detectable (circle).

Serum PGA levels were determined by RIA (Sorin, Saluggia, Italy; reference range, 30-100 $\mu\text{g/L}$); serum PGC levels were determined by immunoenzymatic assay (reference range, 2.6-13 $\mu\text{g/L}$).

Gastric juice pH was determined using litmus paper on gastric preendoscopic aspirate, an approach that has been proven quite reliable in evaluating gastric secretory capacity in previous studies (24).

Quantification of 8OHdG from Gastric Mucosa Biopsies

High-Pressure Liquid Chromatography with Electrochemical Detector. Overall, 8OHdG levels were determined in 120 samples of gastric and esophageal mucosa. Gastric biopsy specimens obtained at endoscopy were stored at -80°C for no longer than 3 weeks. The optimized method of 8OHdG quantification used in the present experiment has already been extensively described elsewhere (7). In brief, following nuclease P1 and alkaline phosphatase hydrolysis, ~ 20 μg DNA per sample were injected in the high-pressure liquid chromatography (HPLC; Shimadzu, Kyoto, Japan). The 8OHdG was detected using an electrochemical detector (ED; ESA Coulochem II 5200A, Bedford, MA) equipped with a high-sensitivity analytic cell model 5011, with the oxidation potentials of electrodes 1 and 2 adjusted to 0.15 and 0.35 V, respectively. The levels of 8OHdG were referred to the amount of deoxyguanosine detected in the same sample by UV absorbency at 254 nm. The amount of DNA was determined according to a calibration curve versus known amounts of calf thymus DNA. The levels of 8OHdG were expressed as the number of 8OHdG adducts per 10^5 deoxyguanosine bases.

ELISA Assay. A part of extracted DNA was used to quantify oxidative DNA adduct 8OHdG with a competitive *in vitro* ELISA (8OHdG Check, Japan Institute for the Control of Aging, Fukuroi, Shizuoka, Japan).

The specificity of the assay has been established: 19 8OHdG analogues showed no cross-reactivity; only 8-sulfhydryl-G and 8OHG showed a minimal cross-reactivity (<1%). The range of the assay was from 0.5 to 200 ng/mL.

Statistics. Data were statistically examined using one-way ANOVA in examining the patients in whom three procedures had been performed, Student's paired *t* test, Kruskal-Wallis *H* test for nonparametric data, where appropriate (Kolmogorov-Smirnov), and χ^2 test.

Results

Characteristics of the Patients Undergoing Two and Three Procedures. No difference whatsoever was documented with respect to all the investigated variables (endoscopy, particularly presence or absence of hiatal hernia or esophagitis; histology, particularly presence of histologic esophagitis), age, or gender between the subgroup of patients accepted to undergo the third endoscopy and the subgroup of patients who did not undergo the third endoscopy.

Endoscopy and Pathology before and after *H. pylori* Eradication. The endoscopy score for esophagitis rose from the initial endoscopy procedure to those performed after *H. pylori* eradication, although not significantly (Los Angeles endoscopy score: 0.5 ± 0.6 versus 0.7 ± 0.4 versus 0.9 ± 0.8), whereas the prevalence of histologic esophagitis went from 43% at the first endoscopy to 59% at the second and 77% at the third ($P = 0.036$). Consistent with the endoscopic findings, the prevalence of histologic lesions consistent with reflux significantly increased in the esophageal mucosa from the baseline (obtained in *H. pylori*-positive patients) to the second and third endoscopies (referring to *H. pylori*-eradicated patients): histologic esophagitis in 19% versus 31.5% versus 46.5% ($P = 0.05$, χ^2 test for trend; Table 1). A rising score was also detected for intrasquamous leukocyte exocytosis between the initial *H. pylori*-positive endoscopy and the second and third samples (18% versus 28% versus 38%; $P = 0.1$, χ^2 test for trend). In three patients, biopsies taken at the third endoscopy showed previously undetected areas of columnar epithelium coexisting with foci of IM.

H. pylori eradication significantly reduced the inflammatory infiltrate in the lamina propria at the cardia [median score (variance), 2 (0.337) versus 1 (0.136) versus 1 (0.141); $P = 0.00001$, Kruskal-Wallis *H* test]. In samples taken from the oxyntic mucosa, the scores for both mononuclear infiltrate in the lamina propria and histologic activity significantly dropped after eradication [median score (variance), 2 (0.221) versus 1 (0.136) versus 1 (0.141) and 2 (0.434) versus 0 (0.03) versus 0 (0.358); both $P < 0.0001$, Kruskal-Wallis *H* test]. No significant modifications were detected before versus after eradication in the score for atrophy or IM.

At the antrum, the score for both mononuclear infiltrate in the lamina propria and histologic activity significantly decreased following eradication ($P < 0.0001$ and 0.0001, respectively, Kruskal-Wallis *H* test). No differences were detected in the prevalence of atrophy

Table 1. Endoscopic and histologic detection of reflux esophagitis and leukocyte exocytosis score at the GEJ before and after *H. pylori* eradication (mean \pm SD)

	Esophagitis at the endoscopy	Percentage of patients with histologically proven esophagitis (%) [*]	Leukocyte exocytosis
Initial (first) endoscopy (enrollment of 32 <i>H. pylori</i> -positive patients)	0.5 \pm 0.6	19	0.2 \pm 0.4
Second endoscopy (short-term follow-up in 32 <i>H. pylori</i> -eradicated patients)	0.7 \pm 0.6	31.5	0.28 \pm 0.4
Third endoscopy (long-term follow-up in 13 <i>H. pylori</i> -eradicated patients)	0.6 \pm 0.6	46.5	0.38 \pm 0.5

NOTE: Initial endoscopy: first endoscopy procedure with multiple biopsy sampling in *H. pylori*-positive patients (32 cases). Second endoscopy: second endoscopy procedure with multiple biopsy sampling performed a mean (range) of 5.7 (3-17) months after enrollment (30 patients; i.e., short-term follow-up). Third endoscopy: endoscopy procedure with multiple biopsy sampling performed a mean (range) of 18 (8-24) months after enrollment (13 patients; i.e., long-term follow-up).

^{*}*P* = 0.05.

before and after eradication (44% versus 44% versus 38%). At enrollment, IM was detected in 56% of the antral biopsy samples and its prevalence progressively declined to 40% and 30% in the antral samples obtained at the second and third biopsies (if any; *P* = 0.04; Table 2).

Laboratory Tests (PGA, PGC, Gastrin, and Gastric Juice pH). PGC levels dropped progressively from enrollment to the second and third endoscopy procedures (21.6 \pm 10.8 versus 14.1 \pm 7.9 versus 14.5 \pm 10.9; *P* = 0.01, one-way ANOVA), with a concomitant significant increase in PGA/PGC ratio (6.2 \pm 2.1 versus 9.3 \pm 3.1 versus 13.9 \pm 8; *P* = 0.0001, one-way ANOVA).

No statistical differences were detected with respect to gastrin and PGA levels, which remained substantially the same before and after eradication.

Gastric juice pH was lower after eradication (3.5 \pm 2.2 versus 2.4 \pm 1.4; *P* = 0.04, Student's *t* test).

Oxidative Genomic Damage Tested in Antral and GEJ Districts. Tested by HPLC-ED, 8OHdG levels were not significantly higher at the GEJ than in the antrum, whereas the difference was more evident with ELISA assay (*P* = 0.07). The results obtained with the two methods were significantly, albeit weakly, correlated (*r* = 0.28; *P* = 0.03).

8OHdG Levels in the Antrum. No significant differences in 8OHdG levels were documented in the antral tissue obtained after *H. pylori* eradication (second and

third endoscopies) by comparison with the *H. pylori*-positive biopsy samples (HPLC-ED: 45 \pm 23 versus 56.2 \pm 34.5 versus 62.6 \pm 32; *P* = NS; ELISA: 0.047 \pm 0.03 versus 0.046 \pm 0.03 versus 0.031 \pm 0.006; *P* = NS, one-way ANOVA). Overall, after eradication, increased 8OHdG levels were found in 43% of the patients.

8OHdG Levels in the GEJ. At the GEJ, a significant increase in the levels of oxidative adduct was consistently shown following eradication by both HPLC-ED (52.8 \pm 30 versus 66.1 \pm 39; *P* = 0.04, Student's *t* test) and ELISA (0.08 \pm 0.04 versus 0.1 \pm 0.05; *P* = 0.05, Student's *t* test). Indeed, when the tissue obtained at the third endoscopy was also considered [13 patients; mean (range) follow-up, 18 (8-24) months], 8OHdG levels had further increased (HPLC-ED method, *P* = 0.01; ELISA, *P* = 0.01, one-way ANOVA; Table 3). Overall, higher 8OHdG levels were found in 65% of the patients.

The 8OHdG levels were also evaluated by subgrouping the patients according to the *H. pylori* strains genotyped at the baseline. At the GEJ, the 19 patients enrolled as *H. pylori-cagA* positive had higher 8OHdG levels after eradication than the 13 *H. pylori-cagA*-negative patients (83.7 \pm 46.48 versus 57.9 \pm 31.4, number of 8OHdG per 10⁵ deoxyguanosine; *P* = 0.05, Student's *t* test). An increase in 8OHdG levels was observed in 86% of patients harboring *H. pylori-cagA*-positive infection. This was not the case for the 8OHdG levels in the antrum.

Table 2. Gastritis score, histologic activity, atrophy, and IM assessed in antral biopsy samples before and after *H. pylori* eradication (mean \pm SD)

	Gastritis score [*]	Histologic activity [†]	Atrophy [‡]	IM [§]
Initial (first) endoscopy (enrollment of 32 <i>H. pylori</i> -positive patients)	2.2 \pm 0.5	1.9 \pm 0.5	0.7 \pm 0.8	1.1 \pm 1.1
Second endoscopy (short-term follow-up in 32 <i>H. pylori</i> -eradicated patients)	1.2 \pm 0.5	0	0.7 \pm 0.6	0.84 \pm 1
Third endoscopy (long-term follow-up in 13 <i>H. pylori</i> -eradicated patients)	1.2 \pm 0.2	0.3 \pm 0.6	0.5 \pm 0.7	0.6 \pm 0.9

NOTE: Gastritis score: mononuclear infiltrate in the lamina propria. For details on initial, second, and third endoscopies, see Table 1. Before versus after *H. pylori* eradication by Kruskal-Wallis *H* test.

^{*}*P* < 0.0001.

[†]*P* < 0.0001.

[‡]*P* = NS.

[§]*P* = NS.

Table 3. Oxidative DNA damage in tissue samples obtained from the GEJ before and after *H. pylori* eradication (mean \pm SD) with both methods

	GEJ		Antrum	
	HPLC-ED* no. 8OHdG per 10 ⁵ deoxyguanosine	ELISA* (ng/mL)	HPLC-ED* no. 8OHdG per 10 ⁵ deoxyguanosine	ELISA* (ng/mL)
Initial (first) endoscopy (enrollment of 32 <i>H. pylori</i> -positive patients)	52.8 \pm 30	0.08 \pm 0.04	45 \pm 23	0.047 \pm 0.03
Second endoscopy (short-term follow-up in 32 <i>H. pylori</i> -eradicated patients)	66.1 \pm 39	0.11 \pm 0.05	56.2 \pm 34.5	0.046 \pm 0.03
Third endoscopy (long-term follow-up in 13 <i>H. pylori</i> -eradicated patients)	107.2 \pm 54.8	0.29 \pm 0.12	62.6 \pm 32	0.031 \pm 0.006

NOTE: For details on initial, second, and third endoscopies, see Table 1. 8OHdG levels were significantly higher after *H. pylori* eradication with both HPLC and ELISA.

**P* = 0.01, one-way ANOVA.

Finally, a significant increase in 8OHdG levels was documented at the GEJ in 80% of the 17 patients whose initial and follow-up endoscopies showed the presence of gastroesophageal hiatal hernia (50.8 \pm 27.6 versus 76 \pm 48.5; *P* = 0.011, Student's *t* test).

Discussion

H. pylori infection is an ubiquitous disease, with a prevalence in our area in the adult population of healthy controls of ~72%, with ~65% of them harboring infection by more virulent *cagA*-positive *H. pylori* strains (25, 26).

Oxidative damage is well documented in chronic gastric inflammatory diseases (7-9, 27). Recent published results showed that mucosal oxidative damage in *H. pylori* infection is associated with increased inflammatory cell infiltration, enhanced apoptosis, and cell proliferation (28, 29), whereas it has been postulated that the progressive accumulation of oxidative DNA damage in certain genes, such as *p53*, may contribute to gastric carcinogenesis (30). In particular, oxidative DNA damage, shown by 8OHdG levels, closely correlates with *H. pylori* infection, particularly when sustained by *H. pylori-cagA*-positive strains (7-9). Patients with *H. pylori-cagA*-positive infection develop gastric oxidative DNA damage earlier in life and more extensive gastric mucosal alterations, and this longer-standing DNA damage may help to explain the greater risk of gastric cancer of *H. pylori-cagA*-positive patients (31, 32). More recently, the debate has also involved the question of whether *H. pylori* eradication is somehow related to the higher incidence/prevalence of adenocarcinoma in the distal esophagus and GEJ (33). What happens after *H. pylori* eradication is being investigated in the proximal stomach, just below the GEJ, in the area usually called the cardia, and in the distal esophagus. Concerning proximal stomach (i.e., cardia), there is a consensus that inflammatory changes tend to disappear after eradication, following the same trend as elsewhere in the stomach (34). As for the distal esophagus, very few sound data have been published thus far and the overall feeling is that *H. pylori* eradication may trigger a more severe GERD, particularly in predisposed patients (35).

This prospective study investigates the effects of *H. pylori* eradication on (a) stomach mucosa histology (antrum, incisura angularis, corpus, cardia, and GEJ) and (b) oxidative DNA damage (expressed as 8OHdG accumulation) in the antral and GEJ mucosal districts.

H. pylori eradication was documented in all patients with both C13 urea breath test and endoscopy. During endoscopy, as described in Patients and Methods, multiple biopsies were taken in five different gastric sites and, in a subgroup of patients, in two different endoscopies; the possibility of false-negative results was null.

Like other studies, a significant reduction in gastritis score was documented at all sites tested, including the cardia, in the short term (<6 months) and longer term. A trend was also observed toward a reduction in the atrophic changes (both metaplastic and nonmetaplastic) in biopsies obtained from the antral mucosa. This is consistent with findings recently reported by several authors, all pointing to a regression of the precancerous lesions after *H. pylori* eradication (36-39).

At the GEJ, both endoscopy and histology documented a significant trend toward the onset (or increasing severity) of inflammatory changes. The above-mentioned changes were associated with a significant reduction in PGC serum levels and an increase in PGA/PGC ratio, whereas changes in serum gastrin and gastric juice pH did not prove significant.

The most interesting finding is the effect of *H. pylori* eradication on the extent of DNA oxidative damage, as assessed by two different methods, in the antral and GEJ. Indeed, among the techniques used to determine 8OHdG levels, the high sensitivity and specificity of HPLC-ED has made it the most widely used assay in fluid samples as well as in solid tissue samples. An ELISA kit has been developed recently; this commercial assay facilitates the evaluation of the oxidative DNA damage even in many samples (with a sensitivity comparable with HPLC-ED). Only few authors have reported the correlation between the two methods in a methodologic study (40); however, the correlation between HPLC-ED and ELISA has been proven weak but significant. What is probably more relevant is that a significant consistency was shown in the trends after eradication in most cases.

With both methods, the present study showed that *H. pylori* eradication results into a significant increase

in oxidative DNA damage at the GEJ, quantifiable as ~2-fold by HPLC and ~3-fold by ELISA. The trend is particularly evident in patients who had been infected by *H. pylori-cagA*-positive strains, a subgroup of patients that can be assumed as the most depressed acid secretors (41). This condition has been recently proven particularly unfavorable as concerns GERD (12, 42, 43). The trend became more evident in patients in whom the *H. pylori* was eradicated for a longer period and when they had predisposing factors such as hiatal hernia.

Is this increase in oxidative DNA damage at the GEJ relevant in both biological and clinical terms? Recent studies implicate ROS production as a result of chronic inflammation due to GERD in the pathogenesis of Barrett's esophagus and esophageal cancer (16, 17). Although there is no direct evidence linking ROS accumulation with esophageal carcinoma in humans, the implication may be inferred from several lines of experimental evidence. In animal models, ROS have been implicated in chronic esophageal inflammation, esophageal epithelial metaplasia, and esophageal adenocarcinoma; in experimentally induced reflux esophagitis, a significant increase in malondialdehyde levels, nuclear factor- κ B activation, and reduced glutathione depletion have also been shown (44). In addition, nitric oxide, formed from dietary nitrites exposed to acid gastric juice (45), may lead to the greater oxidative DNA damage we are reporting.

An additional finding should be considered (i.e., the detection of a more significant increase in oxidative DNA damage at the GEJ of patients suffering from hiatal hernia). Several authors have reported that hiatal hernia is closely associated with reflux esophagitis, which may become symptomatic when *H. pylori* eradication "depresses" gastric acid secretion (16, 35).

What has been described above for GEJ does not find a correlation with what we observed in the antral mucosa. Indeed, despite a significant reduction in gastric inflammation, basically no change in mean 8OHdG levels was detected at this site at any time point. This finding might seem somewhat surprising, but Pignatelli et al. (46) recently reported data fairly consistent with ours using immunostaining-inducible nitric oxide synthase, nitrotyrosine, and 8OHdG. Although she observed a consistent reduction in inducible nitric oxide and nitrotyrosine staining, the data for 8OHdG were somewhat erratic with a sizable share of patients with stable or higher levels after eradication (44%), whereas the levels dropped in only 32% of cases. These data are in fact absolutely comparable with ours, because in our study we observed, after eradication, an increase of 8OHdG levels in 43% of the patients and a drop only in 38%.

It is generally agreed that *H. pylori* eradication is followed by a reduction in simple inflammatory changes; on the other hand, a regression of precancerous changes (i.e., IM or epithelial noninvasive neoplasia) is much less supported by evidence in the literature, although our own previous experience and the majority of the reports point to a regression of metaplastic and precancerous changes (39, 47). In this experience, a reduction in metaplastic changes was only observed in a minority of patients, however, and was not accompanied by any regression of atrophy.

In short, this study showed that (a) despite a significant reduction in inflammatory lesions and a near-significant trend toward a regression of IM, no clear-cut change in antral mucosa oxidative DNA damage is observed after *H. pylori* eradication. (b) Conversely, eradication results in a significant increase in the esophageal inflammatory lesions in tissue samples from the GEJ district, in parallel with a significant increase in DNA oxidative damage. This condition is more clearly established in patients who had been affected by *H. pylori-cagA*-positive infection, thus contributing to the debate on the relationship between *H. pylori-cagA*-positive strains and risk of cardia adenocarcinoma (48, 49), and in the event of predisposing factors, such as hiatal hernia, thus confirming the conclusions recently drawn by Graham (50).

The above findings may well have something to do with the greater risk of developing precancerous changes, such as Barrett's esophagus or, possibly, with a greater risk of distal esophageal cancer.

References

- de Groot H. Reactive oxygen species in tissue injury. *Hepatogastroenterology* 1994;41:328-32.
- Adelman R, Saul RL, Ames BN. Oxidative damage to DNA: relation to species metabolic rate and life span. *Proc Natl Acad Sci U S A* 1988;85:2706-18.
- Basaga HS. Biochemical aspects of free radicals. *Biochem Cell Biol* 1990;68:989-98.
- Floyd RA. Role of oxygen free radicals in carcinogenesis and brain ischemia. *FASEB J* 1990;4:2587-97.
- Du MQ, Carmichael PL, Phillips DH. Induction of activating mutations in the human c-Ha-ras-1 proto-oncogene by oxygen free radicals. *Mol Carcinog* 1994;11:170-5.
- Kuchino Y, Mori F, Kasai H, et al. Misreading of DNA templates containing 8-hydroxydeoxyguanosine at the modified base and at adjacent residues. *Nature* 1987;327:77-9.
- Farinati F, Cardin R, Degan P, et al. Oxidative DNA damage accumulation in gastric carcinogenesis. *Gut* 1998;42:351-6.
- Baik SC, Youn HS, Chung MH, et al. Increased oxidative DNA damage in *Helicobacter pylori* infected human gastric mucosa. *Cancer Res* 1996;56:1279-82.
- Danese S, Cremonini F, Armuzzi A, et al. *Helicobacter pylori* CagA-positive strains affect oxygen free radicals generation by gastric mucosa. *Scand J Gastroenterol* 2001;36:247-50.
- Loffeld RJ, Werdmuller BF, Kuster JG, Perez-Perez GI, Blaser MJ, Kuipers EJ. Colonization with cagA-positive *Helicobacter pylori* strains is inversely associated with reflux esophagitis and Barrett's esophagus. *Digestion* 2000;62:95-9.
- Rokkas T, Ladas SD, Triantafyllou K, et al. The association between CagA status and the development of esophagitis after the eradication of *Helicobacter pylori*. *Am J Med* 2001;110:703-7.
- Chow WH, Blaser MJ, Blot WJ, et al. An inverse relation between cagA+ strains of *Helicobacter pylori* infection and risk of esophageal and gastric cardia adenocarcinoma. *Cancer Res* 1998;58:588-90.
- Rugge M, Russo V, Busatto G, et al. The phenotype of gastric mucosa coexisting with Barrett's esophagus. *J Clin Pathol* 2001;54:456-60.
- El-Omar EM. The importance of interleukin 1 β in *Helicobacter pylori* associated disease. *Gut* 2001;48:743-7.
- Vakil NB. Review article: gastro-esophageal reflux disease and *Helicobacter pylori* infection. *Aliment Pharmacol Ther* 2002;16:47-51.
- Koike T, Ohara S, Sekine H, et al. Increased gastric acid secretion after *Helicobacter pylori* eradication may be a factor for developing reflux esophagitis. *Aliment Pharmacol Ther* 2001;15:813-20.
- Farhadi A, Fields J, Banan A, Keshavarzian A. Reactive oxygen species: are they involved in the pathogenesis of GERD, Barrett's esophagus, and the latter's progression toward esophageal cancer? *Am J Gastroenterol* 2002;97:23-6.
- Spechler SJ. Carcinogenesis at the gastroesophageal junction: free radicals at the frontier. *Carcinogenesis* 2002;23:1518-32.
- Armstrong D, Bennett JR, Blum AL, et al. The endoscopic assessment of esophagitis: a progress report on observer agreement. *Gastroenterology* 1996;111:85-92.

20. Goldblum JR. The esophagogastric junction. *Am J Surg Pathol* 2000;24:1171-4.
21. Rugge M, Correa P, Dixon MF, et al. Gastric mucosal atrophy: interobserver consistency using new criteria for classification and grading. *Aliment Pharmacol Ther* 2002;16:1249-59.
22. Genta RM. Recognizing atrophy: another step toward a classification of gastritis. *Am J Surg Pathol* 1996;20 Suppl 1:S23-30.
23. Rugge M, Busatto G, Cassaro M, et al. Patients younger than 40 years with gastric carcinoma. *Helicobacter pylori* genotype and associated gastritis phenotype. *Cancer* 1999;85:2506-11.
24. Farinati F, Cardin F, Di Mario F, et al. Preendoscopic gastric pH determination. Simple method for increasing accuracy in diagnosing chronic atrophic gastritis. *Gastrointest Endosc* 1987;33:293-7.
25. Perri F, Piepoli A, Quitadamo M, Quarticelli M, Merla A, Bisceglia M. HLA-DQA1 and -DQB1 genes and *Helicobacter pylori* infection in Italian patients with gastric adenocarcinoma. *Tissue Antigens* 2002;59:55-7.
26. Gallo N, Zambon CF, Navaglia F, et al. *Helicobacter pylori* infection in children and adults: a single pathogen but a different pathology. *Helicobacter* 2003;8:21-8.
27. Farinati F, Della Libera G, Cardin R, et al. Gastric antioxidant, nitrites, and mucosal lipoperoxidation in chronic gastritis and *Helicobacter pylori* infection. *J Clin Gastroenterol* 1996;22:275-81.
28. Noguchi K, Kato K, Moriya T, et al. Analysis of cell damage in *Helicobacter pylori*-associated gastritis. *Pathol Int* 2002;52:110-8.
29. Naito Y, Yoshikawa T. Molecular and cellular mechanisms involved in *Helicobacter pylori*-induced inflammation and oxidative stress. *Free Radic Biol Med* 2002;33:323-6.
30. Choi J, Yoon SH, Kim JE, Rhee KH, Youn HS, Chung MH. Gene-specific oxidative DNA damage in *Helicobacter pylori* infected human gastric mucosa. *Int J Cancer* 2002;99:485-90.
31. Papa A, Danese S, Sgambato A, et al. Role of *Helicobacter pylori* CagA+ infection in determining oxidative DNA damage in gastric mucosa. *Scand J Gastroenterol* 2002;37:409-13.
32. Farinati F, Cardin R, Russo VM, Busatto G, Franco M, Rugge M. *Helicobacter pylori* cagA status, mucosal oxidative damage and gastritis phenotype: a potential pathway to cancer? *Helicobacter* 2003;8:227-34.
33. Sipponen P, Marshall BJ. Gastritis and gastric cancer. Western countries. *Gastroenterol Clin North Am* 2000;29:579-92.
34. Goldblum JR. Inflammation and intestinal metaplasia of the gastric cardia: *Helicobacter pylori*, gastroesophageal reflux disease, or both. *Dig Dis* 2000;18:14-9.
35. Hamada H, Haruma K, Mihara M, et al. High incidence of reflux esophagitis after eradication therapy for *Helicobacter pylori*: impacts of hiatal hernia and corpus gastritis. *Aliment Pharmacol Ther* 2000;14:729-35.
36. Ito M, Haruma K, Kamada T, et al. *Helicobacter pylori* eradication therapy improves atrophic gastritis and intestinal metaplasia: a 5-year prospective study of patients with atrophic gastritis. *Aliment Pharmacol Ther* 2002;16:1449-56.
37. Ohkusa T, Fujiki K, Takashimizu I, et al. Improvement in atrophic gastritis and intestinal metaplasia in patients in whom *Helicobacter pylori* was eradicated. *Ann Intern Med* 2001;134:380-6.
38. Franceschi F, Genta RM, Sepulveda AR. Gastric mucosa: long-term outcome after cure of *Helicobacter pylori* infection. *J Gastroenterol* 2002;37:17-23.
39. Rugge M, Russo MV, Guido M. Review article: what have we learnt from gastric biopsy? *Aliment Pharmacol Ther* 2003;17:68-74.
40. Yin B, Whyatt RM, Perera FP, Randall MC, Cooper TB, Santella RM. Determination of 8-hydroxydeoxyguanosine by an immunoaffinity chromatography-monoclonal antibody-based ELISA. *Free Radic Biol Med* 1995;18:1023-32.
41. Graham DY, Yamaoka Y. *H. pylori* and cagA: relationships with gastric cancer, duodenal ulcer and reflux esophagitis and its complications. *Helicobacter* 1998;3:145-50.
42. Queiroz DM, Rocha GA, Oliveira CA, et al. Role of corpus gastritis and cagA-positive *Helicobacter pylori* infection in reflux esophagitis. *J Clin Microbiol* 2002;40:2849-53.
43. Warburton-Timms VJ, Charlett A, Valori RM, et al. The significance of cagA(+) *Helicobacter pylori* in reflux esophagitis. *Gut* 2001;49:319-20.
44. Lee JS, Oh TY, Ahn BO, et al. Involvement of oxidative stress in experimentally induced reflux esophagitis and Barrett's esophagus: clue for the chemoprevention of esophageal carcinoma by antioxidants. *Mutat Res* 2001;480-481:189-200.
45. Iijima K, Henry E, Moriya A, Wirz A, Kelman AW, McColl K. Dietary nitrate generates potentially mutagenic concentrations of nitric oxide at the gastroesophageal junction. *Gastroenterology* 2002;122:1248-57.
46. Pignatelli B, Bancel B, Plummer M, Toyokuni S, Patricot L-M, Ohshima H. *Helicobacter pylori* eradication attenuates oxidative stress in human gastric mucosa. *Am J Gastroenterol* 2001;96:1758-66.
47. Farinati F, Foschia F, Di Mario F, Cassaro M, Rugge M. *H. pylori* eradication and gastric precancerous lesions. *Gastroenterology* 1998;115:512-4.
48. Wu AH, Crabtree JE, Bernstein L, et al. Role of *Helicobacter pylori* CagA+ strains and risk of adenocarcinoma of the stomach and esophagus. *Int J Cancer* 2003;103:815-21.
49. Warburton-Timms VJ, Charlett A, Valori RM, et al. The significance of cagA+ *Helicobacter pylori* in reflux esophagitis. *Gut* 2001;49:341-6.
50. Graham DY. The changing epidemiology of GERD: geography and *Helicobacter pylori*. *Am J Gastroenterol* 2003;98:1462-70.