

Agnogenic Myeloid Metaplasia: A Clonal Proliferation of Hematopoietic Stem Cells With Secondary Myelofibrosis

By Robert J. Jacobson, Armi Salo, and Philip J. Fialkow

The glucose-6-phosphate dehydrogenase (G-6-PD) types and chromosomes of hematopoietic and other tissues were determined in a woman with agnogenic myeloid metaplasia. The patient was heterozygous at the X-linked G-6-PD locus so that both B and A isoenzymes were found in nonhematopoietic cells. In contrast, only one G-6-PD type was found in granulocytes, red cells, and platelets. She also had a distinctive chromosome abnormality in blood cells but not in other tissues. These results indicate that agnogenic myeloid metaplasia is a disorder of a

pluripotent stem cell and provide strong evidence that it is of clonal origin. In contrast to blood cells, the patient's cultured marrow "fibroblasts" had normal chromosomes and both B and A G-6-PD types, suggesting that the marrow fibrosis is a secondary abnormality. Thus, at least in this case of agnogenic myeloid metaplasia, the hematopoietic cell proliferation appears to be clonal, and, by inference, possibly neoplastic, whereas the marrow fibrosis is probably not clonal, and therefore appears to be secondary.

MYELOFIBROSIS WITH MYELOID METAPLASIA may arise idiosyncratically (so-called agnogenic myeloid metaplasia) or during the course of chronic myelocytic leukemia and polycythemia vera. The disorder is often classified with these two diseases as myeloproliferative in origin, presumably a neoplasia. However, the identity of the putative neoplastic cell has not been defined, nor have the factors underlying the marrow fibrosis. The latter process may represent one facet of a general neoplasia arising in pluripotent stem cells, or it may represent a secondary reaction, perhaps in response to marrow injury or to stimulatory factors produced by abnormal hematopoietic cells.

These issues can be resolved by studying patients with two or more genetically marked populations of cells. For example, Van Slyck and co-workers¹ have reported a 22-yr-old woman with acute myelofibrosis and myeloid metaplasia in whom unstimulated blood cells showed a consistent, abnormal chromosome rearrangement. In contrast to the blood cells, cultured marrow fibroblasts lacked this anomaly, suggesting that they are derived from a normal stem cell population. However, this patient's disease had several atypical features, including early age of onset, unusually high number of myeloblasts in the peripheral blood, and rapid progression to pronounced myelofibrosis.

From the Division of Hematology-Oncology, Department of Medicine, University of the Witwatersrand and Baragwanath Hospital, Johannesburg, South Africa; the Medical Genetics Section, Medical Service, Veterans Administration Hospital, and the Departments of Medicine and Genetics, University of Washington, Seattle, Wash.

Submitted July 26, 1977; accepted September 9, 1977.

Supported by Grants CA 16448 and GM 15253 from the National Cancer Institute and the Institute of General Medical Sciences, NIH.

Address for reprint requests: Dr. Philip J. Fialkow, Medical Service, Veterans Administration Hospital, 4435 Beacon Ave., S. Seattle, Wash. 98108.

© 1978 by Grune & Stratton, Inc. ISSN 0006-4971/78/5102-0013\$01.00/0

We have studied a female patient with a more typical presentation of agnogenic myeloid metaplasia, using as cell markers her chromosomes and the electrophoretic pattern of glucose-6-phosphate dehydrogenase (G-6-PD), an X-linked isoenzyme. The results indicate that the disease is a disorder of a pluripotent stem cell and appears to be clonal in origin. Cells giving rise to the fibrosis, however, do not seem to arise from the abnormal marrow progenitor. Thus, as in acute myelofibrosis, the predominant finding in this disorder, widespread myelofibrosis, appears to be secondary in origin.

MATERIALS AND METHODS

Case Report

D.M., a 70-yr-old black female, was admitted to Baragwanath Hospital in Johannesburg on February 3, 1975 for investigation of hepatosplenomegaly of at least 3 mo duration. Hemoglobin level was 7 g/dl and on peripheral blood smear the red cells showed anisocytosis and poikilocytosis (including tear-shaped cells) and nucleated cells. Leukocyte count was 22,400/cu mm with a differential count of 72% neutrophils, 1% monocytes, 26% lymphocytes, 1% myelocytes, and 5% normoblasts/100 WBC. Platelet count was 165,000/cu mm and uncorrected reticulocyte count 5.5%. Leukocyte alkaline phosphatase was 6 units (normal 12-130 units) and the serum vitamin B₁₂ was 546 pg/ml (normal 250-1100 pg/ml). Attempts to aspirate marrow from the sternum and posterior iliac crest were unsuccessful. Bone marrow biopsy from the posterior superior iliac spine showed myelofibrosis with a marked increase in reticulin material, prominent large megakaryocytes, and a decrease in erythroid and myeloid elements. Percutaneous liver biopsy showed islands of extramedullary hematopoiesis in the hepatic sinuses.

The patient was transfused and discharged from hospital with a hemoglobin of 11 g/dl, but was readmitted on May 11, 1975 with congestive heart failure and bronchopneumonia. The hemoglobin was 6 g/dl, leukocyte count 25,200/cu mm, and platelet count 40,000/cu mm. She was transfused with packed red cells, treated for cardiac failure, and received parenteral antibiotics. She initially appeared to improve but then had gastrointestinal bleeding and developed renal insufficiency and died on May 25, 1975. An autopsy was not performed.

Methods

Blood was obtained for G-6-PD and chromosome studies before the patient was transfused. To determine G-6-PD phenotypes, extracts of skin and cultured skin fibroblasts, as well as peripheral blood granulocytes, erythrocytes, and platelets, were prepared and analyzed for isoenzyme type by starch-gel electrophoresis as previously described.^{2,3} The relative activity of the isoenzyme bands was estimated visually. This technique allows detection of a minor enzyme component contributing at least 5% - 10% of the total activity.²

Bone marrow biopsies were performed on the posterior superior iliac spine using a Westerman-Jensen needle with the patient's informed consent. The portions of marrow biopsy specimens used for fibroblast cultures were immediately adjacent to those that showed extensive fibrosis on microscopic examination. Marrow fibroblasts were cultured from biopsy tissue and from material remaining after cells were teased out of the biopsies.³ Fibroblasts grew in both cultures and were harvested for G-6-PD and chromosome analysis after the first, second, or third transfer.

For chromosome studies, marrow was examined directly³ and after 72 hr in culture with and without phytohemagglutinin stimulation. No metaphases were found. Peripheral blood obtained in preservative-free heparin was examined after 72 hr in culture with and without phytohemagglutinin stimulation.⁴ Karyotypes were prepared using conventional Giemsa staining and two banding techniques, trypsin-Giemsa⁵ and acetic-saline-Giemsa.⁶

RESULTS

G-6-PD

When skin and cultured skin fibroblasts obtained from two separate sites were analyzed for G-6-PD, approximately equal amounts of B and A iso-

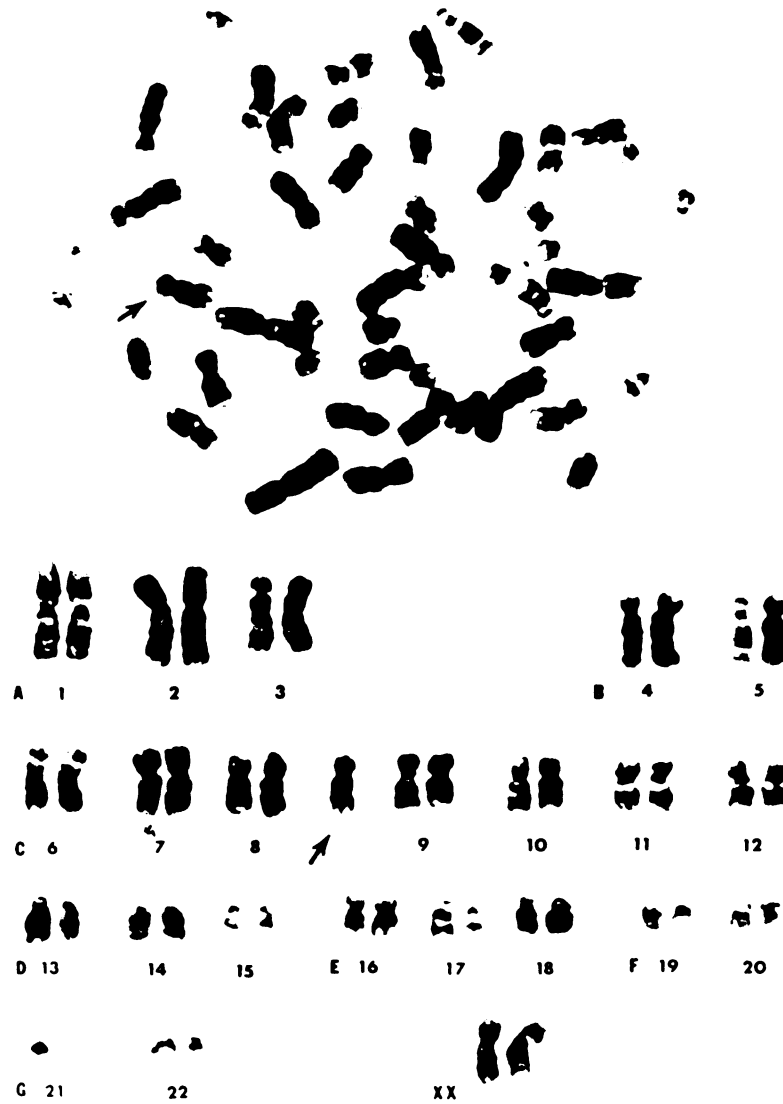


Fig. 1. Karyotype prepared from a white blood cell showing trisomy 8 (47,XX,+8). $\times 1600$.

enzymes were found. Thus, the patient was presumed to be a Gd^B/Gd^A heterozygote. In marked contrast, only type A enzyme was detected in peripheral blood granulocytes, erythrocytes, and platelets and in cells obtained directly from marrow biopsy tissue. Equal proportions of B and A isoenzymes were repeatedly observed in cultured marrow fibroblasts.

Chromosomes

Of 60 metaphases studied at the third transfer of cultured fibroblasts, 58 had 46 chromosomes and 2 had 45. Four banded karyotypes had a normal 46,XX chromosome complement. All 40 metaphases examined from blood cultured

without phytohemagglutinin stimulation had 47 chromosomes with an extra C-group member (47,XX,+C). Of 60 blood cells cultured in the presence of phytohemagglutinin, 27 (45%) had the same C-trisomy and 33 were normal. Nine banded karyotypes of 47,XX,+C were prepared. The extra chromosome was identical in every cell and had the characteristics of a No. 8 chromosome (Fig. 1). Fibroblasts cultured from a portion of the intact marrow spicules and from a portion of the spicules after loose cells had been removed were examined at the first and second transfers, respectively. In the former, 37 of 40 cells had 46 chromosomes. Two cells had 45 chromosomes and one had 44. Chromosome loss in these three cells was random and presumed to be artifactual. From the second culture, 59 of 60 metaphases had 46 chromosomes. One cell had 45 chromosomes. Two banded karyotypes were prepared from each culture and were 46,XX.

DISCUSSION

The locus for G-6-PD is on the X chromosome and, as a consequence of X-chromosome inactivation, only one G-6-PD gene is active in each somatic cell.⁷⁻⁹ Therefore, females heterozygous for a B and an A gene have two cell populations—one synthesizing type B enzyme and the other type A. Normal tissues such as blood granulocytes and skin almost always contain a mixture of cells and manifest both B and A enzymes². However, clonal cell proliferations display only one enzyme type, B or A.¹⁰

Patients with chronic myelocytic leukemia or polycythemia vera who are heterozygous for G-6-PD have both enzyme types in their nonhematopoietic tissues, but only one isoenzyme is found in blood granulocytes, erythrocytes, and platelets.^{3,11,12} The results strongly suggest clonal origin of these myeloproliferative diseases and provide formal proof that they arise from hematopoietic pluripotent stem cells. Similarly, both B and A types of G-6-PD have been found in nonhematopoietic tissues from our patient with agnogenic myeloid metaplasia and myelofibrosis, but only type A enzyme has been detected in her peripheral blood granulocytes, erythrocytes, and platelets. Thus, the data provide strong evidence that agnogenic myeloid metaplasia is a stem cell disorder, probably of clonal origin. Similar conclusions have been suggested by Kahn et al. in a study of a patient heterozygous for G-6-PD deficiency¹³ and are also supported by the chromosome studies in our patient. Cultured cells derived from normal tissues were 46,XX, but all unstimulated blood cells had a characteristic chromosome abnormality (47,XX,+8).

Marrow cells cultured from biopsy specimens showing extensive fibrosis and growing as monolayers had morphology typical of fibroblasts. Since these cells were repeatedly passaged, they were not blood cells and probably were fibroblasts. Thus, the observations that, in contrast to the patient's blood cells, the cultured "fibroblasts" had normal chromosomes and displayed both B and A type G-6-PD, strongly suggest that the marrow fibrosis is a secondary abnormality. An alternative possibility is that marrow fibroblasts *in vivo* are clonally derived, but, *in vitro*, outgrowth of these cells is depressed in favor of residual normal cells. However, not even one chromosomally abnormal cultured marrow fibroblast was detected, and the proportion of B:A G-6-PD after

the first transfer was the same as it was in skin. Thus, any selection in vitro against abnormal marrow fibroblasts would have to be virtually complete, even though these same cells predominate in vivo. A better explanation would be that the cultured fibroblasts are predominantly derived from the cells responsible for the myelofibrosis in vivo, and, therefore, that the latter cells do not arise from the abnormal hematopoietic stem cell. Thus, the myelofibrosis in agnogenic myeloid metaplasia is apparently a secondary abnormality.

The cause(s) of agnogenic myeloid metaplasia are, as its name implies, unknown. Some workers consider it to be a neoplasm,^{14,15} whereas others feel that it is a generalized secondary hyperplasia.¹⁶⁻¹⁸ However, most investigators consider the marrow fibrosis to be part of the same process that affects the blood cells.^{14-16,19} Our data and those previously reported by Van Slyck et al.¹ suggest that this interpretation may not be correct. The hematopoietic cell proliferation appears to be clonal, and, by inference, possibly neoplastic, whereas the marrow fibrosis is probably not clonal and appears to be secondary.

ACKNOWLEDGMENT

We thank P. Basford, G. Herner, and L. Steinmann for their expert assistance and Dr. F. Segal (Department of Medicine, Baragwanath Hospital) for referring the patient to us.

REFERENCES

1. Van Slyck EJ, Weiss L, Dully M: Chromosomal evidence for the secondary role of fibroblastic proliferation in acute myelofibrosis. *Blood* 36:729, 1970
2. Fialkow PJ: Primordial cell pool size and lineage relationships of five human cell types. *Ann Hum Genet* 37:39, 1973
3. Fialkow PJ, Jacobson RJ, Papayanopoulou T: Chronic myelocytic leukemia: Clonal origin in a stem cell common to the granulocyte, erythrocyte, platelet and monocyte/macrophage. *Am J Med* 53:125, 1977
4. Moorhead PS, Nowell PC, Mellman WJ, Battips DM, Hungerford DA: Chromosome preparations of leukocytes cultured from human peripheral blood. *Exp Cell Res* 20:613, 1960
5. Seabright M: A rapid banding technique for human chromosomes. *Lancet* 2:971, 1971
6. Sumner AT, Evans HJ, Buckland RA: New technique for distinguishing between human chromosomes. *Nature [New Biol]* 232:21, 1971
7. Beutler E, Yeh M, Fairbanks F: The normal human female as a mosaic of X-chromosome activity: Studies using the gene for G-6-PD deficiency as a marker. *Proc Natl Acad Sci USA* 48:9, 1962
8. Davidson RG, Nitowsky HM, Childs B: Demonstration of two populations of cells in the human female heterozygous for glucose-6-phosphate dehydrogenase variants. *Proc Natl Acad Sci USA* 50:481, 1963
9. De Mars R, Nance WE: Electrophoretic variants of glucose-6-phosphate dehydrogenase and the single-active-X in cultivated human cells in Defendi V (ed): *Retention of Functional Differentiation in Cultured Cells*. Philadelphia, Wistar Institute, 1964, p 35
10. Fialkow PJ: Clonal origin of human tumors. *Biochim Biophys Acta* 458:283, 1976
11. Fialkow PJ, Gartler SM, Yoshida A: Clonal origin of chronic myelocytic leukemia in man. *Proc Natl Acad Sci USA* 58:1468, 1967
12. Adamson JW, Fialkow PJ, Murphy S, Prchal JF, Steinmann L: Polycythemia vera: Stem cell and probable clonal origin of the disease. *N Engl J Med* 295:913, 1976
13. Kahn A, Bernard JF, Cottreau D, Marie J, Boivin P, Gd(-) Abrami: A deficient G-6-PD variant with hemizygous expression in blood cells of a woman with primary myelofibrosis. *Humangenetik* 30:41, 1975
14. Dameshek W: Some speculations on the myeloproliferative syndromes. *Blood* 6:372, 1951
15. Gilbert HS: The spectrum of myeloproliferative disorders. *Med Clin North Am* 57:355, 1973
16. Ward HP, Block MH: The natural history of agnogenic myeloid metaplasia (AMM) and a critical evaluation of its relation-

ship with the myeloproliferative syndrome. *Medicine* 50:357, 1971

17. Williams JW, Beutler E, Erslev AJ, Rundles WR: *Hematology*. New York, McGraw-Hill, 1972, p 696

18. Wintrobe MM, Lee GR, Boggs DR, Bithell TC, Athens JW, Foerster J: *Clinical*

Hematology (ed 7). Philadelphia, Lea & Febiger, 1974, p 1778

19. Laszlo J: Myeloproliferative disorders (MPD): Myelofibrosis, myelosclerosis, extra-medullary hematopoiesis, undifferentiated MPD, and hemorrhagic thrombocytopenia. *Semin Hematol* 12:409, 1975