

## POSTMORTEM FINDINGS FROM DUGONG (*DUGONG DUGON*) SUBMISSIONS TO THE UNIVERSITY OF QUEENSLAND: 1997–2010

Helen Owen,<sup>1,2,3</sup> Alison Gillespie,<sup>1</sup> and Ian Wilkie<sup>1</sup>

<sup>1</sup> School of Veterinary Science, Building 8114, University of Queensland, Gatton Campus, Gatton, Queensland 4343, Australia

<sup>2</sup> Vet-MARTI group, Building 8114, School of Veterinary Science, University of Queensland, Gatton Campus, Gatton, Queensland 4343, Australia

<sup>3</sup> Corresponding author (email: h.owen1@uq.edu.au)

**ABSTRACT:** To better record and characterize mortality in the declining population of dugong (*Dugong dugon*) in southeast Queensland, Australia, animals were collected and brought to the University of Queensland for postmortem examination. Fifty-five animals were examined over a 14-yr period. Human activities commonly caused the animal death. Several deaths were attributed to primary or secondary infections and idiopathic and degenerative diseases. A significant proportion of animals were found to have nonspecific signs of chronic debility, but the causes of disease and mortality in these cases remains to be identified.

**Key words:** Australia, dugong, pathology, Sirenia, wildlife.

### INTRODUCTION

The dugong (*Dugong dugon*) is the only strictly marine, herbivorous mammal and is one of four surviving species of the order Sirenia or seacows. Dugongs are widely distributed in the Indo-Pacific region, but the largest population adjacent to a major metropolitan area is found in Moreton Bay, southern Queensland, Australia (Lanyon, 2003). Dugongs' dependence on seagrasses mostly restricts them to shallow, nearshore waters, habitats that are increasingly being occupied by humans and influenced by human activities, particularly in Australia where a large proportion of the human population lives along the coast. It is likely that human activities have contributed to the substantial decline in dugong numbers along the urban coast of Queensland, Australia. Several dugong mortalities each year occur because of boat strikes and netting. There have also been many dugong mortalities of undetermined causes (Greenland and Limpus, 2007). Despite dugongs being listed as vulnerable to extinction (IUCN, 2010), little is known about their common disease processes and causes of natural mortality.

The closely related manatee (*Trichechus manatus*) has been studied more extensively, and it is likely that, in certain circumstances, dugongs would be prone to

similar pathologic processes. Manatees are also an endangered species. The largest population of manatees lives in the waters off Florida, USA (Walsh et al., 1987).

As in the dugong population, a large proportion of manatee deaths are the direct result of human activity. Many animals are hit by boats or crushed by flood gates and locks (Buergelt, 1984; Bossart, 1999). Reports of deaths from natural disease in manatees are relatively uncommon. In fact, the manatees appear remarkably resilient to natural disease and the effects of trauma. This robustness may partially result from an exceptionally efficient and responsive immune system (Bossart, 1999). However, there are two notable exceptions to this resistance to disease. Given particular environmental conditions, "cold stress syndrome" and brevetoxicosis can cause significant mortality (Bossart, 2001).

Other reported natural conditions of manatees include infections, such as systemic and pulmonary mycobacteriosis, hemorrhagic enteritis, pleuritis, lung abscessation, pyelonephritis, and mycotic and other dermatopathies (Bossart, 2001; Sato et al., 2003; Keller et al., 2008). Several species of endoparasites are commonly found in manatees, sometimes in large numbers, but associated pathologic signs, clinical disease, and mortalities are

rare (Bossart, 2001). Compared with adults, neonates can develop severe health problems, and perinatal death is common and often the result of malnutrition, exposure, or opportunistic disease (Walsh et al., 1987; Bossart, 1999; Bossart, 2001).

As with manatees, records of dugong deaths from natural disease are uncommon, and most are single-case studies (Elliot et al., 1981; Greenland and Limpus, 2007; Ladds, 2009). Intestinal cryptosporidiosis was identified in a terminally ill animal; however, it was not possible to comment on its clinical significance (Ladds, 2009). A fatal *Salmonella* sp. infection occurred in a young dugong after it was accidentally separated from its mother and subsequently held in captivity (Elliot et al., 1981). Of six dugong necropsies on animals in the Townsville region of north Queensland, Australia, in 1999, one was diagnosed with a bacterial septicemia, verminous bronchopneumonia, cachexia, and extensive skin and gastrointestinal tract abscessation. Two other animals died from acute peritonitis secondary to rupture of a small intestinal abscess, and a neonate was believed to have starved, based on its extremely poor body condition. No diagnosis was established for the two remaining animals (Marsh et al., 2000).

Increases in dugong mortality can result from extensive die off of seagrass (Marsh et al., 2000; Greenland and Limpus, 2007). Seagrass ecosystems are very sensitive and are readily destroyed by anything that increases turbidity and deprives them of light or causes nutrient enrichment and increased epiphytic growth. Human activities, such as trawling and dredging and water pollution, have a negative effect on sea-grass ecosystems, as have natural events, such as cyclones and flooding (Heinsohn and Spain, 1974; Marsh et al., 2000; Greenland and Limpus, 2007).

A collaboration has been established between the Department of Environment and Resource Management (DERM; Brisbane, Queensland, Australia) and

the University of Queensland (Gatton, Queensland, Australia) to better record and characterize causes of dugong death. Ultimately, this information can be used to implement and improve management strategies.

## MATERIALS AND METHODS

Dugong carcasses were collected by the Queensland, Australia, DERM rangers and transported to the University of Queensland's Veterinary Pathology department for post-mortem examinations. Carcasses were examined by researchers between 2005 and 2007. The necropsy technique employed was that advocated by Eros et al. (2007). Body condition was subjectively determined based on the amount of subcutaneous and visceral adipose tissue. Depending on the degree of autolysis and the diagnostic value, tissue, fluid, and microbiologic samples were collected as required from a standard set of organs, preserved in 10% neutral-buffered formalin, embedded in paraffin, sectioned at 5  $\mu$ m, and routinely stained with hematoxylin and eosin.

Aerobic culture was attempted for exudative, caseous, or otherwise potentially infectious lesions on 5% sheep blood agar (SBA) and MacConkey agar (MCA) plates (Oxoid, Thebarton, South Australia, Australia), and incubated overnight at 35 C. Samples for anaerobic culture were inoculated onto SBA and incubated under anaerobic conditions overnight at 35 C. Skin samples were cultured aerobically onto SBA, MCA, Sabouraud dextrose medium containing chloramphenicol (SC), and SC agar with the addition of actidione (cycloheximide, SCA, and Oxoid) overnight at 25 C.

All isolates considered significant were further identified by standard veterinary diagnostic techniques, including the Microbact 24E system (Medvet Diagnostics, Thebarton, South Australia, Australia), Streptex (Oxoid) for *Streptococcus* Lancefield grouping, and 16S rRNA gene sequencing (Sidjabat et al., 2007), as required. The immunohistochemistry for *Toxoplasma gondii* was performed by a commercial laboratory.

When nematodes were present, their numbers were estimated by counting the number of worms in a weighed aliquot of stomach contents. The total mass of stomach content was then weighed, and the number of worms was estimated by extrapolation.

TABLE 1. Causes of death and significant lesions in 32 dugongs (*Dugong dugon*) from southeast Queensland, Australia, examined at necropsy from 1997 to 2010. No necropsies of dugongs were conducted in 2006 and 2007.

Case No. (yr)	Age <sup>a</sup>	Sex	Diagnosis
1 (1997)	Juvenile	M	Massive stomach worm burden, presumed semi-impaction, cachexia
2 (1997)	Adult	F	Fibrinous peritonitis secondary to rupture of uterine abscess
3 (1998)	Adult	F	Cardiomyopathy
4 (1999)	Juvenile	F	Widespread bacterial cellulitis
5 (2000)	Adult	F	Fibrino-pyogranulomatous pleuritis and cachexia
6 (2000)	Juvenile	M	Head trauma, cachexia
7 (2000)	Adult	F	Superficial skin lesions consistent with trapped in net
8 (2001)	Adult	F	Presumed suffocation and drowning
9 (2002)	Adult	M	Peritonitis, suspect septicemia or enterotoxemia
10 (2002)	Adult	M	Boat strike
11 (2002)	Adult	M	Boat strike
12 (2003)	Adult	M	Boat strike
13 (2003)	Adult	M	Boat strike
14 (2003)	Adult	M	Toxoplasmosis
15 (2003)	Adult	M	Inconclusive, parasitic tracheobronchitis
16 (2004)	Adult	F	Boat strike
17 (2004)	Adult	F	Boat strike
18 (2004)	Juvenile	M	Boat strike
19 (2005)	Juvenile	M	Boat strike
20 (2008)	Juvenile	F	Peritonitis, suspect septicemia or enterotoxemia
21 (2008)	Adult	M	Inconclusive, myocardial mineralization
22 (2009)	Adult	M	Chest injury, trauma
23 (2009)	Adult	M	Chest injury, trauma
24 (2009)	Adult	M	Possible head trauma
25 (2009)	Adult	F	Possible myocardial degeneration
26 (2009)	Adult	F	Bronchopneumonia, possible myocardial degeneration, cachexia
27 (2009)	Adult	M	Chest trauma
28 (2009)	Calf	M	Meningitis and septicemia
29 (2010)	Adult	F	Intestinal volvulus and peritonitis
30 (2010)	Juvenile	F	Inconclusive, verminous tracheitis
31 (2010)	Adult	M	Head and neck trauma
32 (2010)	Adult	M	Presumed suffocation and drowning

<sup>a</sup> Age estimation based on maturity of reproductive system, snout to fluke length: adult, >2.2 m; independent immature (juvenile), 1.8–2.2 m; dependent calves, <1.8 m (Greenland and Limpus, 2007).

## RESULTS

The causes of death of 32 dugongs are listed in Table 1. In 23 cases (6 adult males, 5 juvenile males, 5 adult females, 1 juvenile female, 3 females of undetermined maturity, 1 animal of unspecified age and sex, and 1 adult and 1 juvenile of undetermined sex), cause of death could not be determined. One animal was a beached neonate that was euthanized based on a poor prognosis for successful release. No abnormalities were noted in this dugong. Examples of typical presen-

tations and relevant features in six categories are as follows.

### Mortality due to trauma and netting

**Case 6:** Generally, visceral adipose tissue was depleted and of a gelatinous consistency (serous atrophy). Over the skull, there was extensive intramuscular hemorrhage, and histologically, there was perivascular hemorrhage around many meningeal vessels. The hemorrhage over the skull and brain was considered consistent with head trauma, and boat strike was the most likely cause.

**Case 7:** This adult female was in excellent body condition. The animal had multiple <10-cm-long, linear lacerations over its skin, consistent with being trapped in netting, with death probably due to suffocation and drowning.

**Case 13:** The carcass had 10 linear, evenly spaced skin wounds (8–30 cm long) over its right side, and 13 ribs were fractured, with associated hemorrhage. There was approximately 10–12 L of serosanguinous fluid in the peritoneal cavity, and the right lung contained hemorrhages and tears in the visceral pleura subjacent to the rib fractures. There was a moderate amount of hemorrhage around the right kidney. These findings are consistent with trauma caused by boat strike.

**Case 16:** This carcass was in good condition. The animal had 6 very deep, roughly parallel, transverse cuts from the nose to middorsal region (Fig. 1). The first cut was deep into soft tissue of the nose, just caudal to the nostrils. The second cut had smashed the skull and completely removed the brain. There was some fresh clotted blood in the remains of the left cranial vault. The third cut had completely severed the vertebral column in the mid-cervical region, and the fourth had penetrated the thorax on the left side, lacerating the left lung. The remaining two cuts were also very deep but had not penetrated to the body cavity. The diagnosis was also trauma associated with boat strike.

#### **Mortality due to inflammatory and infectious diseases**

**Case 1:** The animal's body condition was poor with marked serous atrophy. The dugong's upper small intestine and the stomach compartments were semi-impacted with a massive helminth burden (approximately 5,500–6,000 parasites). Cause of death was not determined but was possibly associated with the parasite burden of *Paradujardinia halicoris*.

**Case 2:** The animal's abdomen was filled with red/brown flocculent fluid, and most

serosal and visceral surfaces were coated with fibrin tags. Within the right uterine horn, there was a transmural, 250×300-mm abscess. Much of the abscess was necrotic and had ruptured into the abdomen at one site. Death was considered to be the result of peritonitis and septicemia or toxemia.

**Case 5:** This carcass had moderate serous atrophy. There was a marked, unilateral, suppurative pleuritis with an intralesional, mixed population of anaerobic bacteria. The suggested cause of death was respiratory failure or septicemia or toxemia.

**Case 9:** This carcass was in good condition. The animal had a large amount of brown, serosanguinous fluid and a moderate amount of fibrin in its peritoneal cavity. There were multifocal paintbrush and echymotic hemorrhages on the visceral and parietal pleura. The skeletal musculature was edematous and dark red with green mottling; a heavy, mixed growth of anaerobes, including two species of *Clostridium* (not identified to species), were cultured from the muscle. Death was considered a result of septicemia or toxemia.

**Case 14:** This carcass was in poor body condition. There was marked serous atrophy of visceral adipose tissue. There were multiple granulomas in several organs, most prevalent in the liver and mesenteric lymph nodes, which contained numerous cyst-like structures approximately 8–12 µm in diameter, with a thin, outer membrane enveloping bradyzoite-like structures. Structures were approximately 0.5–1 µm, accurate estimation hampered by autolytic changes. Immunohistochemistry was performed, and cysts reacted positively to *Toxoplasma gondii* antibodies. The diagnosis was systemic toxoplasmosis.

#### **Idiopathic mortality**

**Case 29:** The abdomen contained 5 L of sanguineous, flocculent fluid, and much of the viscus was coated with fibrin tags. A



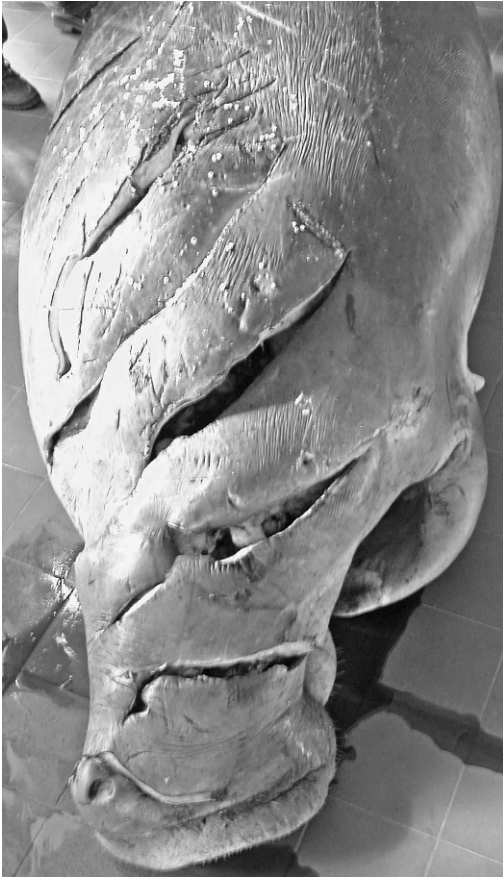

FIGURE 1. Dugong (*Dugong dugon*) carcass (case 17) from southeast Queensland, Australia, collected in 2004. Figure shows multiple deep, linear, and parallel cuts on the craniodorsal surface, consistent with a boat strike.

3-m section of small intestine was dark red to black from congestion and necrosis caused by a  $>180^\circ$  volvulus in the corresponding mesentery. The diagnosis was peritonitis with septicemia or toxemia.

#### Perinatal mortality

**Case 28:** This calf was orphaned and being cared for in captivity. Gross and microscopic findings were consistent with a severe, heterophilic meningoencephalitis; an ulcerative and heterophilic enteritis; a mild, chronic cystitis; and fungal dermatitis. A light to heavy growth of *Enterococcus faecalis* was cultured from urine (heavy growth), cerebrospinal fluid (light

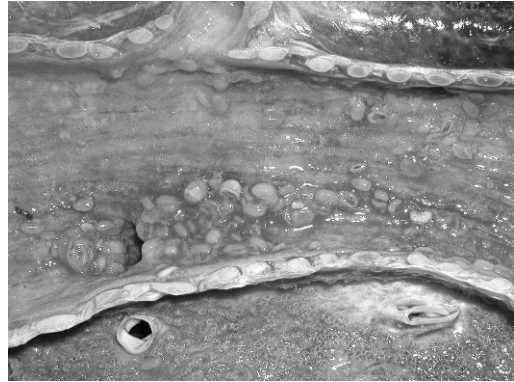


FIGURE 2. The inflamed mucosal surface of the trachea from a dugong (*Dugong dugon*; case 15) from southeast Queensland, Australia, collected in 2003. The tissue is covered by moderate to large numbers of trematodes (*Cochleotrema indicum*).

growth), and feces (heavy growth). Death was considered a result of the multisystemic infection.

#### Degeneration

**Case 3:** The pleural cavity contained approximately 1–2 L of serous fluid and large quantities of watery fluid were present in the primary bronchi and lung tissue. Histologically, there was evidence of low-protein edema in the pulmonary interstitium. Within the myocardium, there were subtle changes suggestive of a cardiomyopathy, namely, moderate variation in myofiber size and marked anisokaryosis, with the nucleus often having a vesicular chromatin pattern. Congestive heart failure was the likely cause of death.

#### Inconclusive and/or likely opportunistic infection

**Case 30:** The animal was in good condition, but there was some serous atrophy of the pericardiac adipose tissue. The mucosal surfaces of the trachea and intrapulmonary bronchi were diffusely red and covered by moderate to large numbers of trematodes (*Cochleotrema indicum*; Fig. 2). Histologically, there was hyperplasia, squamous metaplasia, and ulceration of the tracheal mucosal surface and a moderate to marked, chronic, active tracheitis and bronchitis.

## DISCUSSION

As in previous investigations of dugong mortalities (Greenland and Limpus, 2007), the cause of death was not established for a large proportion (23 of 55; 42%) of the dugongs examined. Also, in agreement with previously published data (Greenland and Limpus, 2007), human activities were identified as a significant cause of dugong mortality. Fourteen (cases 6, 10, 11–13, 16–19, 22–24, 27, and 31; Table 1) of the 55 dugongs (25%) in this study may have been killed by boat strike. It is suggested that Florida manatees may be prone to boat strike because of a limited sensitivity to low frequencies, which hampers their ability to detect and locate approaching boats. The anatomy of the dugong ear differs from that of the manatee, and we are uncertain about the role of hearing in dugong boat strikes (Marsh et al., 2000). Cachectic, debilitated animals are likely to be more prone to collisions with boats (e.g., case 6, which also had evidence of trauma, probably caused by boat strike; Marsh et al., 2000). Areas in Moreton Bay Marine-Park and the Great Sandy Marine Park, where dugongs and humans are most likely to interact, are designated “go slow” areas, meaning boats must travel off-plane or in displacement mode, and boats that are longer than 8 m are restricted to <10 knots. Motorized water sports are prohibited in these areas. This strategy reduced the number of boat strikes (Greenland and Limpus, 2007).

Dugongs can also drown after being caught in nets, such as those used to protect beaches from sharks and those used for fishing. Several animals were reported to have died in this manner in 2007 (Greenland and Limpus, 2007) and for three of the dugongs in this study (5%; cases 7, 8, and 32; Table 1). Diagnosing drowning in the absence of reliable information on where and how the body was found is difficult because there are no specific internal lesions and net

marks on skin can be difficult to differentiate from other premortem and postmortem changes (Marsh et al., 2000). Reported pulmonary lesions associated with drowning in marine mammals are inconsistent (Ladds, 2009). Drowning dugongs do not appear to inhale water, probably because of a highly developed dive reflex (Ladds, 2009), and it is rare to find water in the respiratory tract. In those few cases where it was present, it was thought most likely to have entered after rigor mortis had subsided, and the larynx relaxed.

The dugong population around Townsville, Queensland, Australia, was severely depleted following the introduction of a shark netting program in 1964 (Heinsohn, 1972). The program was modified, and subsequently, the catch rate reduced substantially, probably because of altered netting strategies and a reduction of the dugong population in these areas (Heinsohn, 1972; Marsh et al., 2000). The introduction of an act requiring fishermen to report all interactions with protected species, including dugongs, is also likely to have reduced dugong mortality (Greenland and Limpus, 2007).

Several animals in this study (cases 1, 2, 4, 5, 9, 20, and 28; Table 1) likely died because of primary or secondary infectious disease. Case 1 had a massive helminth (*Paradujardina halicoris*) burden in its stomach. Little is known about the pathogenicity of helminth parasites in sirenians (Bossart, 2001), and *Paradujardina* spp. were often found in large numbers in dugong stomachs, including those in apparently good body condition. The burden of worms may have caused physical effects on gastric function, or less likely, perhaps, parasite-induced appetite suppression, similar to that which occurs with some intestinal parasites in domesticated animals (Dynes et al., 1998).

*Toxoplasma gondii* caused death from meningoencephalitis (Buergelt, 1983; Dailey, 2001) and myocarditis (Bossart, 2001) in manatees, and the systemic *T. gondii* infection in case 14 is the first

recorded case of toxoplasmosis in a dugong (that case was previously published by Ladds [2009]). Unfortunately, the brain was not examined because dugongs have great significance for the traditional Aboriginal owners of the site. Dugong heads are returned to these people as a condition of our being able to conduct necropsies on animals which die in their area. Consequently, meningoencephalitis cannot be excluded, but is likely, because the infection was clearly multisystemic. The mode of transmission is uncertain. There is a large population of domestic and feral cats living near Moreton Bay, Australia, so it is also possible that the dugongs are ingesting water contaminated by infected cat feces, as suggested elsewhere (Miller et al., 2008).

The route of infection and dissemination of bacteria in cases 4 and 5 was not determined, but possible pathogeneses may include direct introduction of an infectious agent through a penetrating wound or the hematogenous spread of infection from some other focus. *Clostridium* spp. were cultured from cases 9 and 20, both of which had peritonitis and possible septicemia or toxemia. The *Clostridium* spp. recovered may have been significant but may also have been a postmortem contaminant.

Meningitis in the calf (case 28) also had an infectious etiology. *Enterococcus* spp. have been identified as an uncommon cause of postoperative or spontaneous meningitis in humans (Pintado et al., 2003). Most instances of "hematogenous" or "spontaneous" meningitis secondary to an enterococcal infection outside the central nervous system occurred in humans with severe underlying medical conditions or immunosuppression. Common routes of infection included genitourinary, biliary, and intra-abdominal tracts, and some authors suggest that underlying gastrointestinal tract infections may be the source in some cases (Pintado et al., 2003). There was ulcerative, heterophilic enteritis in case 28, and that may

have led to septicemia and meningitis in the dugong calf. The calf may also have been immunosuppressed, given its history and fungal skin infection.

We were unable to determine the cause of the intestinal volvulus that resulted in infarction, fibrinous peritonitis, and mortality in case 29; however, that is unsurprising because volvulus is commonly idiopathic. It is possible that dugongs are predisposed to volvulus because, like horses, they have a long gut that is relatively mobile with long, mesenteric attachments (Gillespie et al., 2011).

Cardiomyopathies were recorded in cases 3, 21, 25, and 26. The myocardial degeneration in case 3 was considered significant, but changes present in the other cases were less convincing and consisted of occasional areas of myocyte mineralization. Because there were no indications of subacute to chronic heart failure, the clinical significance of those changes is uncertain. Cardiac myocyte degeneration is a common feature in manatee cold stress syndrome. In those cases, degeneration manifests histologically as nuclear "rowing"; cytoplasmic vacuolation and loss of cross striations; attenuated, wavy myofibers; and pleomorphic, hypertrophic nuclei with prominent nucleoli (Bossart et al., 2002). No other features suggestive of cold stress syndrome were found in dugongs, and there is no particular seasonal distribution to the mortalities (Greenland and Limpus, 2007), but the possibility of cold-related disease cannot be entirely excluded. Idiopathic cardiomyopathies occur in terrestrial species (Maxie and Robinson, 2007), so the observed lesions in this animal may have no relationship to ambient water temperature.

No clear cause of death or primary disease was found in 23 of 55 cases (42%). Advanced autolysis and postmortem scavenging precluded determination of the causes of death. A significant proportion of these animals had nonspecific signs of debilitation, such as serous atrophy of subcutaneous and visceral fat, dermatopathies, and likely secondary



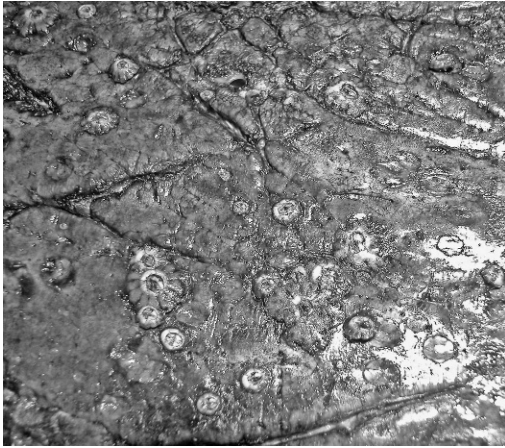


FIGURE 3. Dugong (*Dugong dugon*) skin demonstrating thickening and fissuring (adult, female dugong from southeast Queensland, Australia, collected in 2003, cause of death was not determined). Barnacles visible on the skin are commonly present on the skin of submitted carcasses.

infections, including lung and liver abscessation. The dermatopathies were commonly characterized by degeneration, thickening, and fissuring (Fig. 3). Although cachectic, most of these dugongs had stomachs containing moderate to large amounts of their preferred species of seagrass, so starvation seems unlikely, and some underlying disease or toxicosis may have been affecting their metabolism.

Of the 55 cases of dugong mortality examined between 1997 and 2010, the cause of death was satisfactorily established in some cases, but, for a significant proportion, cause of death was not identified. Dugongs remain a diagnostic challenge because of delays in carcass reporting, collection, and necropsy. We need better understanding of dugong physiology and response to disease to interpret postmortem findings more completely.

#### ACKNOWLEDGMENTS

We acknowledge pathologists, veterinarians, and students that performed or assisted with the postmortem examinations, particularly Roger Kelly, Dick Sutton, Janet Patterson-Kane, Mark Chalkley, Andrew Davis, and Christopher Shooter. This work was funded by the Department of Environment and

Resource Management, The University of Queensland Veterinary School Diagnostic Services, and the Cybec Foundation.

#### LITERATURE CITED

- BOSSART, G. 1999. The Florida manatee: On the verge of extinction? *Journal of the American Veterinary Medical Association* 214: 1178–1183.
- . 2001. Manatees. *In* CRC Handbook of Marine Mammal Medicine. 2nd Edition, L. Dierauf and F. Gulland (eds.). CRC Press LLC, Boca Raton, Florida, pp. 939–960.
- , R. MEISNER, S. ROMMEL, S. GHIM, AND A. BENNETT JENSON. 2002. Pathological features of the Florida manatee cold stress syndrome. *Aquatic Mammals* 29: 9–17.
- BUERGELT, C. 1983. Toxoplasmosis meningoencephalitis in a West Indian manatee. *Journal of the American Veterinary Medical Association* 183: 1294–1296.
- . 1984. Pathologic findings in manatees in Florida. *Journal of the American Veterinary Medical Association* 185: 1331–1334.
- DAILEY, M. 2001. Parasitic diseases. *In* CRC Handbook of Marine Mammal Medicine. 2nd Edition, L. Dierauf and F. Gulland (eds.). CRC Press LLC, Boca Raton, Florida, pp. 357–382.
- DYNES, R., D. POPPI, G. BARRELL, AND A. SYKES. 1998. Elevation of feed intake in parasite-infected lambs by central administration of a cholecystokinin receptor antagonist. *British Journal of Nutrition* 79: 47–54.
- ELLIOT, H., A. THOMAS, P. LADDS, AND G. HEINSOHN. 1981. A fatal case of salmonellosis in a dugong. *Journal of Wildlife Diseases* 17: 203–208.
- EROS, C., H. MARSH, R. BONDE, T. O'SHEA, C. BECK, C. RECCHIA, K. DOBBS, M. TURNER, S. LEMM, R. PEARS, AND R. BOWATER. 2007. Procedures for the salvage and necropsy of the dugong (*Dugong dugon*). 2nd Edition. Great Barrier Reef Marine Park Authority, Townsville, Queensland, Australia, 98 pp.
- GILLESPIE, A., E. BURGESS, J. LANYON, AND H. OWEN. 2011. Small intestinal volvulus in a free-ranging female dugong (*Dugong dugon*). *Australian Veterinary Journal* 89: 276–278.
- GREENLAND, J., AND C. LIMPUS. 2007. Marine wildlife stranding and mortality database annual report 2007, I: Dugong. Queensland Environmental Protection Agency Conservation technical and data report, Brisbane, Queensland, Australia, 23 pp.
- HEINSOHN, G. 1972. A study of dugongs (*Dugong dugon*) in northern Queensland, Australia. *Biological Conservation* 4: 205–213.
- , AND A. SPAIN. 1974. Effects of a tropical cyclone on littoral and sub-littoral biotic communities and on a population of dugongs (*Dugong dugon* (Müller)). *Biological Conservation* 6: 143–152.



- INTERNATIONAL UNION FOR CONSERVATION OF NATURE (IUCN). 2010. IUCN Red List of Threatened Species. Version 2010.2. [www.iucnredlist.org](http://www.iucnredlist.org). Accessed July 2010.
- KELLER, M., J. MOLINER, G. VÁSQUEZ, D. CRUZ, O. BELLO, A. COSTIDIS, S. ROMMEL, M. CALDERWOOD MAYS, AND S. GEARHART. 2008. Nephrolithiasis and pyelonephritis in two West Indian manatees (*Trichechus manatus* spp.). *Journal of Wildlife Diseases* 44: 707–711.
- LADDS, P. 2009. Pathology of Australian native wildlife. Commonwealth Scientific and Industrial Research Organisation (CSIRO) Publishing, Victoria, Australia, 640 pp.
- LANYON, J. 2003. Distribution and abundance of dugongs in Moreton Bay, Queensland, Australia. *Wildlife Research* 30: 397–409.
- MARSH, H., C. EROS, AND R. WEBB. 2000. Dugongs in health and disease. In *Proceedings 335. Marine Wildlife: The Fabian Fay Course of Veterinarians*, Postgraduate Foundation for Veterinary Science, Sydney, Australia, pp. 301–317.
- MAXIE, M., AND W. ROBINSON. 2007. Cardiovascular system. In *Jubb, Kennedy & Palmer's Pathology of Domestic Animals*, Vol. 3, 5th Edition, G. Maxie (ed.). Elsevier Saunders, Edinburgh, Scotland, 4737 pp.
- MILLER, M., W. MILLER, P. CONRAD, E. JAMES, A. MELLI, C. LEUTENEGER, H. DABRITZ, A. PACKHAM, D. PARADIES, M. HARRIS, J. AMES, D. JESSUP, K. WORCESTER, AND M. GRIGG. 2008. Type X *Toxoplasma gondii* in a wild mussel and terrestrial carnivores from coastal California: New linkages between terrestrial mammals, runoff and toxoplasmosis of sea otters. *International Journal for Parasitology* 38: 1319–1328.
- PINTADO, V., C. CABELLOS, S. MORENO, M. MESEGUER, J. AYATS, AND P. VILADRICH. 2003. Enterococcal meningitis: A clinical study of 39 cases and review of the literature. *Medicine* 82: 346–364.
- SATO, T., H. SHIBUYA, S. OHBA, T. NOJIRI, AND W. SHIRAI. 2003. Mycobacteriosis in two captive Florida manatees (*Trichechus manatus latirostris*). *Journal of Zoo and Wildlife Medicine* 34: 184–188.
- SIDJABAT, H., N. HANSON, E. SMITH-MOLAND, J. BELL, J. GIBSON, L. FILIPPICH, AND D. TROTT. 2007. Identification of plasmid-mediated extended-spectrum and AmpC  $\beta$ -lactamases in *Enterobacter* spp. isolated from dogs. *Journal of Medical Microbiology* 56: 426–434.
- WALSH, M., G. BOSSART, W. YOUNG, AND P. ROSE. 1987. Omphalitis and peritonitis in a young West Indian manatee (*Trichechus manatus*). *Journal of Wildlife Diseases* 23: 702–704.

Submitted for publication 17 March 2011.

Accepted 5 April 2012.