

SHORT COMMUNICATIONS

DOI: 10.7589/2011-08-226

Journal of Wildlife Diseases, 48(4), 2012, pp. 1030–1034
© Wildlife Disease Association 2012

***Cryptococcus albidus* Infection in a California Sea Lion (*Zalophus californianus*)**

Shannon Mcleland,^{1,4} Colleen Duncan,¹ Terry Spraker,¹ Elizabeth Wheeler,³ Shawn R. Lockhart,² and Frances Gulland³ ¹Department of Microbiology, Immunology, Pathology, Colorado State University, Fort Collins, Colorado 80523 USA; ²Mycotic Diseases Branch, Centers for Disease Control and Prevention, Atlanta, Georgia 30333 USA; ³The Marine Mammal Center, Sausalito, California 94965, USA; ⁴Corresponding author (email: Shannon.Mcleland@colostate.edu)

ABSTRACT: Sporadic cases of cryptococcosis have been reported in marine mammals, typically due to *Cryptococcus neoformans* and, more recently, to *Cryptococcus gattii* in cetaceans. *Cryptococcus albidus*, a ubiquitous fungal species not typically considered to be pathogenic, was recovered from a juvenile California sea lion (*Zalophus californianus*) rescued near San Francisco Bay, California. Yeast morphologically consistent with a *Cryptococcus* sp. was identified histologically in a lymph node and *C. albidus* was identified by an rDNA sequence from the lung. Infection with *C. albidus* was thought to have contributed to mortality in this sea lion, along with concurrent bacterial pneumonia. *Cryptococcus albidus* should be considered as a potential pathogen with a role in marine mammal morbidity and mortality.

Key words: California sea lion, *Cryptococcus albidus*, fungal infection, pinniped.

Since the late 19th Century, when marine fungal organisms were first discovered, numerous genera have been described throughout the coastal waters of the Atlantic, Pacific, and Indian Oceans (Kutty and Philip, 2008). Described in sporadic case reports, species in the genera of *Candida*, *Aspergillus*, *Mucor*, *Blasatomyces*, *Histoplasma*, *Coccidioides*, and *Cryptococcus* have been implicated as pathogens in marine mammals (Sweeney et al., 1976; Sweeney, 1986; Fauquier et al., 1996; Higgins, 2000). *Cryptococcus* species have gained attention as agents of significant diseases in humans and animals due to the recent emergence of *Cryptococcus gattii* in British Columbia, Canada and the Pacific Northwest of the United States (Datta et al., 2009). Clinical illness has been identified in species that include cats (*Felis*

catus), dogs (*Canis lupus familiaris*), ferrets (*Mustela putorius*), llamas (*Lama glama*), horses (*Equus ferus*), elk (*Cervus canadensis*), cockatoo (*Cacatua* sp.), porpoises (Family Phocoenidae), and a dolphin (*Tursiops truncatus*) in these areas (Miller et al., 2002; Stephen et al., 2002; Lester et al., 2004; Iqbal et al., 2010). However, pinnipeds (Suborder Pinnipedia) have not been included in reports of marine mammals affected by *C. gattii*.

Cryptococcosis is most commonly caused by *Cryptococcus neoformans*, a basidiomycetous fungus that can infect humans and numerous animal species, most commonly manifesting as respiratory or neurologic disease (Malik et al., 2006). In contrast, *Cryptococcus albidus* is regarded as less pathogenic and has been infrequently reported in humans but was reported in two horses, a cat, and a dog. The dog and cat were described as having systemic mycosis, whereas the two horses presented with genital infection and keratitis (Codazza et al., 1973; Desbrosse, 1996; Labrecque et al., 2005; Kano et al., 2008). Human disease due to *C. albidus* is typically secondary to immunosuppression causing meningitis, cryptococemia, and cutaneous lesions (Melo et al., 1980; Gluck et al., 1987; Narayan et al., 2000). Lesions due to cutaneous cryptococcosis in a human case report were described as multiple, ulcerative nodules due to granulomatous inflammation and identifiable yeast organisms without serologic evidence of systemic cryptococemia (Narayan et al., 2000). In marine mammals, reports of

cryptococcosis caused by *C. gattii* or *C. neoformans* involve cetaceans (dolphins and porpoises) (Higgins, 2000; Stephen et al., 2002; Norman et al., 2011). Reports of *C. albidus* infection have not been previously documented in marine mammals.

An approximately 1-yr-old male California sea lion (*Zalophus californianus*) was found in a canal adjacent to San Francisco Bay, California (37°23'2"N, 121°59'14"W), 27 May 2009. The animal was brought to The Marine Mammal Center, Sausalito, California where he was examined and treated supportively with oral fluids by stomach tube and penicillin G intramuscularly, but he died 3 days after admission. The animal weighed 18 kg, was emaciated, and had multifocal cutaneous ulcers scattered along the ventral abdomen and hind-flippers. His abdomen was distended due to an enlarged, friable liver.

Gross necropsy revealed jaundiced blubber and poor skin turgor consistent with dehydration. Lungs were edematous and hemorrhagic, most notably in the right cranial lobe, with froth in the trachea. Tracheobronchial and sternal lymph nodes were enlarged. Multiple mucosal ulcers measuring <1 mm in diameter were present within the gastric fundus and pylorus. Liver lobes were diffusely pale and friable. Kidneys were bilaterally pale and shrunken with loss of distinct renule pattern. The pericardial sac was thickened and contained approximately 20 ml of yellow, turbid fluid.

Microscopic evaluation of sections from the lung and tracheobronchial lymph node revealed severe bacterial pneumonia and granulomatous lymphadenitis. Granulomatous inflammation within the lymph node was accompanied by spherical to ovoid, yeast-like organisms approximately 13–15 µm in diameter with a thick, clear capsule and infrequently narrow-based budding, which is considered microscopically as a characteristic of *Cryptococcus* spp. (Fig. 1) (Malik et al., 2006). The capsule did not stain with Grocott's methenamine silver stain (mucicarmine

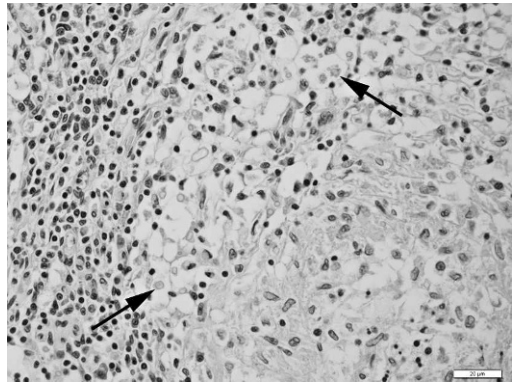


FIGURE 1. Microscopic examination of a tracheobronchial lymph node from a California sea lion (*Zalophus californianus*); necropsy revealed perinodal granulomatous inflammation and large aggregates of *Cryptococcus albidus* organisms. Organisms, indicated by arrows, are spherical with a large, clear capsule. H&E stain. 400×. Bar=20 µm.

stain was not available). Additional lymph nodes (gastric and mesenteric) and tonsils were consistently depleted of lymphocytes. The lungs were consolidated with alveolar spaces containing abundant neutrophils and macrophages, edema, hemorrhage, and fibrin along with large numbers of rod-shaped bacteria. A Brown-Hopps Gram stain confirmed short, gram-negative rods throughout the lung. *Pseudomonas aeruginosa* was cultured in moderate numbers from the lung.

Other histologic lesions included a few foci of hepatocellular necrosis with associated bacteria morphologically similar to that seen in the lung. Hepatocytes were markedly swollen throughout the liver due to hydropic degeneration characterized by discrete to coalescing microvacuoles that give a lacy appearance to the cytoplasm. The right ventricular epicardium was thickened due to edema, inflammation, and bacteria. Multifocal necrosis with bacteria was present in the thyroid gland. A moderate lymphoplasmocytic infiltration was observed within the interstitium of the kidneys. Occasionally, tubules were lined by degenerative epithelium. No spirochetes were detected in sections of the kidney by Warthin-Starry silver staining.

Histologic evidence of a superficial, resolving ulcer with associated mild inflammation but no identifiable infectious etiology was present in selected sections of skin. The stomach contained few mucosal lymphocytic infiltrates. Mild numbers of lymphocytes within meninges of the brain at the region of the thalamus were present but, otherwise, there were no significant lesions in the brain. Additional tissues examined with no significant microscopic abnormalities included spleen, small intestine, large intestine, pancreas, salivary gland, trachea, diaphragm, and pituitary gland.

Fresh lung tissue was submitted to the Centers for Disease Control and Prevention, Atlanta, Georgia, USA for fungal culture and biochemical and molecular analysis. Lung tissue was macerated with a scalpel, vortexed in sterile water, and plated on Sabouraud dextrose agar containing gentamicin and chloramphenicol. Following 5 days of incubation at 35 C, white mucoid colonies were recovered. The isolate did not produce melanin on L-3 4-dihydroxyphenylalanine-containing media (Kwon-Chung et al., 1982). The D1–D2 region of the rDNA was sequenced (Linton et al., 2007). A GenBank BLAST search revealed a 100% match to sequences of *C. albidus* in the American Type Culture Collection and the Centraalbureau voor Schimmelcultures collection (100% match to GenBank numbers AF335982, AF181538).

Cryptococcus albidus is a ubiquitous, saprophytic yeast that has been isolated from the human skin, bird excreta, air, and soil (Fell and Statzell-Tallman, 1998; Sugita et al., 2001). Thought to be less pathogenic than *C. neoformans*, few cases of human and animal disease due to *C. albidus* have been reported in literature. Transmission of *C. albidus* from animal to human has not been reported. Characteristic microscopic morphology, biochemical tests, and molecular analysis are utilized in identification of *C. albidus* (Larone, 2002). *Cryptococcus* species grown on Sabouraud dextrose agar appear creamy, smooth,

and mucoid (Larone, 2002). Biochemical tests for *C. albidus* result in positive utilization of inositol, urease, and nitrate without melanin production (Larone, 2002). Results of culture and biochemical and molecular analysis of isolates from the lung tissue in this California sea lion juvenile were consistent with *C. albidus*. An increased infection rate in the San Francisco area in either human or veterinary medicine has not been reported in the literature and, therefore, this appears to be an isolated incident.

Inhalation is thought to be the major route of infection for cryptococcosis, although in many cases the exact mode of transmission cannot be elucidated (Malik et al., 2006). The absence of identifiable organisms within lung sections examined does not preclude inhalation as a major route of transmission in this case, given that *C. albidus* was cultured from the lung. This, in conjunction with microscopic identification of yeast consistent with cryptococci within the regional lymph node, confirms dissemination with a probable aerogenous exposure. Bacterial bronchopneumonia was severe, presumably masking the presence of *Cryptococcus* sp. in lung sections. Undoubtedly, multiple factors such as bronchopneumonia, stress, and dehydration increased susceptibility to an opportunistic pathogen such as *C. albidus*, culminating in mortality.

Between 2006 and 2010, 2,071 California sea lions were necropsied at the Marine Mammal Center with 602 cases evaluated histologically. In 2009, the year *C. albidus* was discovered, 928 of 934 deceased sea lions were necropsied and histopathology was submitted for 178. To the best of our knowledge, this is the first report of cryptococcosis in pinnipeds, more specifically in a California sea lion, and the first report of *C. albidus* infection in any species of marine mammal. Animals have served as good sentinels of cryptococcal disease in the current emergence of *C. gattii* in the Pacific Northwest and British Columbia. More specifically, mor-

bidity and mortality of cetaceans recently contributed to the recognition of *C. gattii* infection within these regions. Surveillance for infectious organisms in marine mammals is logistically challenging; however, even novel fungal organisms should be considered a potential primary, or at least contributing, pathogen. Given the current emergence of *C. gattii* in the region where the sea lion was found, without careful mycologic examination this case might have been attributed to *C. gattii*, and *C. albidus* may not have been recognized as a potential pathogen of pinnipeds. Thus, culture is always recommended to confirm organisms that are identified histologically.

The findings and conclusions of this article are those of the authors and do not necessarily represent the views of the Centers for Disease Control and Prevention.

LITERATURE CITED

- CODAZZA, D., G. BERTOLDINI, AND G. SAMPIERI. 1973. Genital infection caused by *Cryptococcus albidus* in the horse. *Folia Veterinaria Latina* 3: 339–342.
- DATTA, K., K. H. BARTLETT, R. BAER, E. BRYNES, E. GALANIS, J. HEITMAN, L. HOANG, M. J. LESLIE, L. MACDOUGALL, S. S. MAGILL, M. G. MORSHED, AND K. A. MARR. 2009. Spread of *Cryptococcus gattii* into Pacific Northwest region of the United States. *Emerging Infectious Diseases* 15: 1185–1191.
- DESBROSSE, A. M. 1996. *Cryptococcus* mycotic keratitis in a horse. *Pratique Vétérinaire Equine* 28: 147–148.
- FAUQUIER, D. A., F. M. D. GULLAND, J. G. TRUPKIEWICZ, T. R. SPRAKER, AND L. J. LOWENSTINE. 1996. Coccidioidomycosis in free-living California sea lions. *Journal of Wildlife Diseases* 32: 707–710.
- FELL, J. W., AND A. STATZELL-TALLMAN. 1998. *Cryptococcus* Vuillemin. In *The yeast, a taxonomic study*, 4th Edition, C. P. Kurtman and J. W. Fell (eds.). Amsterdam, The Netherlands, Elsevier, pp. 748–749.
- GLUCK, J. L., J. P. MYERS, AND L. M. PASS. 1987. Cryptococemia due to *Cryptococcus albidus*. *Southern Medical Journal* 80: 511–513.
- HIGGINS, R. 2000. Bacteria and fungi of marine mammals: A review. *Canadian Veterinary Journal* 41: 105–116.
- IQBAL, N., E. E. DEBESS, R. WOHRLE, B. SUN, R. J. NETT, A. M. AHLQUIST, T. CHILLER, AND S. R. LOCKHART. 2010. Correlation of genotype and *in vitro* susceptibilities of *Cryptococcus gattii* from the Pacific Northwest of the United States. *Journal of Clinical Microbiology* 48: 539–544.
- KANO, R., M. KITAGAWA, S. OOTA, T. OOSUMI, Y. MURAKAMI, M. TOKURIKI, AND A. HASEGAWA. 2008. First case of feline systemic *Cryptococcus albidus* infection. *Medical Mycology* 46: 75–77.
- KUTTY, S. N., AND R. PHILIP. 2008. Marine Yeasts—A review. *Yeast* 25: 465–483.
- KWON-CHUNG, K. J., I. POLACHEK, AND T. J. POPKIN. 1982. Melanin-lacking mutants of *Cryptococcus neoformans* and their virulence for mice. *Journal of Bacteriology* 150: 1414–1421.
- LABRECQUE, O., D. SYLVESTRE, AND S. MESSIER. 2005. Systemic *Cryptococcus albidus* infection in a Doberman pinscher. *Journal of Veterinary Diagnostic Investigation* 17: 598–600.
- LARONE, D. H. 2002. *Medically important fungi*, 4th edition. ASM Press, Washington, DC, pp. 54–55 and 129–130.
- LESTER, S. J., N. J. KOWALEWICH, K. H. BARTLETT, M. B. KROCKENBERGER, T. M. FAIRFAX, AND R. MALIK. 2004. Clinicopathologic features of an unusual outbreak of cryptococcosis in dogs, cats, ferrets, and a bird: 38 cases (January to July 2003). *Journal of the American Veterinary Medical Association* 225: 1716–1722.
- LINTON, D. J., A. M. BORMAN, G. CHEUNG, A. D. HOLMES, A. SZEKELY, M. D. PALMER, P. D. BRIDGE, C. K. CAMPBELL, AND E. M. JOHNSON. 2007. Molecular identification of unusual pathogenic yeast isolates by large ribosomal subunit gene sequencing: 2 years of experience at the United Kingdom mycology reference laboratory. *Journal of Clinical Microbiology* 45: 1152–1158.
- MALIK, R., M. KROCKENBERGER, C. R. O'BRIEN, P. MARTIN, D. WIGNEY, AND L. MEDLEAU. 2006. Cryptococcosis. In *Infectious diseases of dog and cat*, 3rd Edition, C. E. Greene (ed.). Saunders Elsevier, St. Louis, Missouri, pp. 584–588.
- MELO, J. C., S. SRINIVASAN, M. L. SCOTT, AND M. J. RAFT. 1980. *Cryptococcus albidus* meningitis. *Journal of Infection* 2: 79–82.
- MILLER, W. G., A. A. PADHYE, W. VAN BONN, E. JENSEN, M. E. BRANDT, AND S. H. RIDGEWAY. 2002. Cryptococcosis in a bottlenose dolphin (*Tursiops truncatus*) caused by *Cryptococcus neoformans* var. *gattii*. *Journal of Clinical Microbiology* 40: 721–724.
- NARAYAN, S., K. BATA, P. COLLOBY, AND C. Y. TAN. 2000. Cutaneous *Cryptococcus* infection due to *C. albidus* associated with Seâzary syndrome. *British Journal of Dermatology* 143: 632–634.
- NORMAN, S. A., S. RAVERTY, E. ZABECK, S. ETHERIDGE, J. K. B. FORD, F. M. N. HOANG, AND M. MORSHED. 2011. Maternal-fetal transmission of *Cryptococcus gattii* in harbor porpoise. *Emerging Infectious Diseases* 17: 304–305.
- STEPHEN, C., S. LESTER, W. BLACK, M. FYFE, AND S. RAVERTY. 2002. Multispecies outbreak of

- cryptococcosis on southern Vancouver Island, British Columbia. *Canadian Veterinary Journal* 43: 792–794.
- SUGITA, T., TAKASHIMA, M., R. IKEDA, T. NAKASE, AND T. SHINODA. 2001. Intraspecies diversity of *Cryptococcus albidus* isolated from humans as revealed by sequences of the internal transcribed spacer regions. *Microbiology and Immunology* 45: 291–297.
- SWEENEY, J. C. 1986. Marine mammals (Cetacea, Pinnipedia, and Sirenia): Infectious diseases. In *Zoo and wild animal medicine*, 2nd Edition, M. E. Fowler (ed.). W. B. Saunders Co., Philadelphia, Pennsylvania, pp. 777–781.
- , G. MUGAKI, P. M. VAINIK, AND R. H. CONKLIN. 1976. Systemic mycoses in marine mammals. *Journal of the American Veterinary Medical Association* 169: 946–948.
- Submitted for publication 2 August 2011.*
Accepted 20 March 2012.