

Case Scenario: Hypotonia in Infancy

Anesthetic Dilemma

Angela K. Saettele, M.D.,* Anshuman Sharma, M.D.,† David J. Murray, M.D.‡

INFANTS with hypotonia of unknown etiology pose a unique challenge as many of the potential diagnoses have major, often conflicting, anesthetic management implications. The differential diagnosis of hypotonia is long and includes possibilities such as Duchenne muscular dystrophy, central core disease, and multimimic disease. Intravenous anesthetic techniques are recommended because hyperkalemia or malignant hyperthermia is associated with the use of volatile anesthetics. However, the differential diagnosis of infants with hypotonia also includes mitochondrial disorders. In children with mitochondrial disorders, an intravenous anesthetic technique that includes propofol could lead to metabolic decompensation because propofol alters mitochondrial electron transfer. This dilemma is often encountered when hypotonic infants require anesthesia for diagnostic tests such as magnetic resonance imaging and muscle biopsies for definitive diagnosis.

Case Scenario

A 4-week, 3.7-kg infant presented for a muscle and skin biopsy. The infant was full term and had been discharged from the hospital with her mother 24 h after delivery. Three weeks later she was admitted for poor feeding and weight

gain. At that time she was noted to be hypotonic and somnolent, with laboratory studies indicating a metabolic acidosis with a base excess of -10 mM and lactate of 12 mM. Over the next week, an extensive set of testing including a serum amino acid profile, urine organic acids, newborn screen for fatty acid oxidation disorders, mitochondrial point mutation mapping, electroencephalogram, echocardiogram, and retina examination were all reported as normal. A head magnetic resonance imaging revealed hyperintensity in the bilateral thalami, basal ganglia, and frontal lobe white matter consistent with a mitochondrial myopathy. After infusion of dextrose containing intravenous fluids, she became more alert and interactive, but remained hypotonic with a persistent metabolic acidosis with a pH of 7.3, base excess of -6.0 mM, and lactate of 6.0 mM. A muscle biopsy was planned to further direct therapy.

In the operating room, anesthesia was induced with 5 mg propofol, 5 μ g fentanyl, and 3 mg rocuronium. A propofol infusion at 200 μ g \cdot kg $^{-1}\cdot$ min $^{-1}$ was used to maintain anesthesia (44 mg propofol total). She returned to the intensive care unit intubated. During the 6 h after anesthesia, she became more alert but remained intubated and ventilated with a respiratory and metabolic acidosis. A capillary blood gas measured at that time indicated a pH of 7.14, pCO₂ of 54 mm, and base excess of -10.7 mM. Her blood lactate levels had increased to 12.8 mM. Over the next 72 h, she became more somnolent and developed a sinus bradycardia, presumed to be due to worsening lactic acidosis. A bicarbonate infusion and an enteral sodium citrate/citric acid mixture were initiated. One week after surgery, her capillary blood gas measured a pH of 6.83 and base excess of -24.3 mM. The infant died 2 weeks after admission after withdrawal of mechanical ventilation. The muscle biopsy confirmed a mitochondrial abnormality.

Discussion

What Was the Primary Preoperative Dilemma Concerning This Patient's Anesthetic?

Hypotonia is a common presenting feature in a variety of congenital, metabolic, and neuromuscular disorders. The

* Instructor, † Associate Professor, ‡ Professor, Department of Anesthesiology, Washington University, Saint Louis, Missouri.

Received from the Department of Anesthesiology, Washington University, Saint Louis, Missouri. Submitted for publication December 12, 2012. Accepted for publication March 29, 2013. Financial support received from Washington University, Department of Anesthesiology. Dr. Murray receives financial support from the Agency for Health Quality and Research, Rockville, Maryland. Figure 1 was drawn by Annemarie B. Johnson, C.M.I., Medical Illustrator, Vivo Visuals, Winston-Salem, North Carolina.

Address correspondence to Dr. Murray: Department of Anesthesiology, Washington University, 660 South Euclid, Campus Box 8054, Saint Louis, Missouri 63110. murrayd@anest.wustl.edu. This article may be accessed for personal use at no charge through the Journal Web site, www.anesthesiology.org.

Copyright © 2013, the American Society of Anesthesiologists, Inc. Lippincott Williams & Wilkins. Anesthesiology 2013; 119:443-6

initial assessment and laboratory testing often suggest the etiology; however, in those infants who have a neuromuscular cause of hypotonia, the potential diagnoses have differing anesthetic implications. Neuromuscular disorders can affect any component of the nervous system from the anterior horn of the spinal column to the muscle fiber (table 1).¹ Each of these diseases can affect multiple organ systems with overlapping symptoms and varying clinical presentations.

Children with mitochondrial diseases may present with a variety of clinical signs and symptoms such as developmental delay, hypotonia, seizures, cardiomyopathy, respiratory muscle weakness, renal or hepatic insufficiency, and lactic acidemia,² but disruption of the mitochondrial respiratory chain is the root cause of all these abnormalities. Some of these same symptoms can be seen in infants who are susceptible to either malignant hyperthermia or profound hyperkalemia. Malignant hyperthermia is a rare but known complication seen when children with congenital myopathies including central core disease and multiminicore disease are exposed to succinylcholine or volatile anesthetics.³ A different pathology causing rhabdomyolysis and profound hyperkalemia can also be seen in patients with muscular dystrophy undergoing inhalational anesthesia. For this reason, many anesthesiologists avoid inhalation anesthetics and succinylcholine in infants with hypotonia. However, due to the effect of propofol on mitochondrial electron transfer pathways, many experts recommend avoiding propofol in children with mitochondrial diseases. However, several case reports and small case series suggest that propofol can be used in this population.⁴⁻⁶

This case highlights a frequent, but challenging anesthetic circumstance when a hypotonic infant who does not have a confirmed diagnosis is scheduled for an operation.⁷ In this patient, the clinical picture led to a presumed diagnosis of mitochondrial myopathy; however, other causes such as a congenital myopathy or muscular dystrophy could not be ruled out.

What Is the Basic Science Behind Mitochondrial Disorders?

Mitochondria are intracellular organelles that have multiple functions including adenosine triphosphate (ATP) synthesis, tricarboxylic acid cycle, urea cycle, β -fatty acid oxidation, and lipid and cholesterol synthesis.⁴ Mitochondria produce energy using a series of enzyme complexes on the inner mitochondrial membrane. Named Complexes I–IV, these components comprise the electron transport chain that moves electrons from electron donors such as nicotinamide adenine dinucleotide to electron receivers such as oxygen. In doing so, a proton gradient is created across the inner mitochondrial membrane that is used by ATP synthase to turn adenosine diphosphate to ATP.⁸ This ATP is broken down to adenosine diphosphate by ATPase, and the energy released in this reaction is used for various cellular functions.

Mitochondria are unique in that they have their own DNA that encodes proteins used in its own processes. Nuclear DNA encodes the majority of the proteins that are required for normally functioning mitochondria. In fact, only 13 proteins, 22 transfer RNAs, and 2 ribosomal RNAs are encoded by mitochondrial DNA (mtDNA). The rest of the mitochondrial proteins are encoded by nuclear genes.⁸

Every cell contains between 1,000 and 100,000 copies of mtDNA. These copies are homogenous within one individual, termed homoplasmy. Any duplication, deletion, or mutation of this mtDNA is potentially pathogenic. Both pathogenic and normal mtDNA can reside within one cell, termed heteroplasmy. Part of the phenotypic variation observed in mitochondrial disorders can be explained by this heteroplasmy. Unlike in nuclear DNA mutations that affect every cell in the body equally, the percentage of mutant mtDNA can vary from cell to cell and organ to organ. Mitochondrial dysfunction only sets in when a certain percentage of pathogenic mtDNA is reached.⁹ This leads to the

Table 1. Partial Differential Diagnoses of Hypotonia

Neural Defects	Myopathies
Spinal muscular atrophies	Congenital myopathies
Type I (Werdnig–Hoffmann disease)	Central core disease
Type III (Kugelberg–Welander disease)	Multiminicore disease
Poliomyelitis	Nemaline myopathy
Neurometabolic disorders	Muscular dystrophies
Leukodystrophies	Limb girdle muscular dystrophy
Mucopolysaccharidoses	Emery–Dreifuss muscular dystrophy
Organic and amino acid disorders	Myotonic dystrophy
Hereditary motor sensory neuropathies	Dystrophinopathies (Duchenne, Becker)
Charcot–Marie–Tooth	Metabolic myopathies
Acute inflammatory neuropathy	Channelopathies
Guillain–Barre	Hypokalemic periodic paralysis
Myasthenia gravis	Sodium channelopathies
Botulism	Mitochondrial
	Lipid myopathies
	Systemic carnitine deficiency

large number of phenotypic variation that can be found in mitochondrial myopathies. This also increases the difficulty of diagnosis. Specific point mutations have been described for multiple mitochondrial diseases.⁹ Targeted point mutation mapping can be used to determine the presence of these specific variants, but many patients with a mitochondrial myopathy do not have any specific mutation identified. The large numbers of nuclear genes that encode mitochondrial proteins along with heteroplasmy increase the difficulty in definitively diagnosing these disorders. Even if a novel mutation is discovered, it may or may not be the cause of the pathology seen in the patient.

How Common Are Mitochondrial Myopathies? How Common Are Mitochondrial Myopathies in Patients Having Muscle Biopsies?

The reported overall incidence of mitochondrial myopathies varies from 11.5 to 25 per 100,000.^{1,5,7} Even though mitochondrial myopathies are an uncommon diagnosis in the general population, the incidence is potentially much higher in those infants presenting for selected diagnostic procedures such as magnetic resonance imaging or muscle biopsy. We reviewed the anesthetic management of 40 infants who required muscle biopsy to diagnose hypotonia over a 5-yr period from 2005 to 2010. Mitochondrial myopathy was the final diagnosis in 8 of the 40 infants (20%). In the other 32 infants, 8 were diagnosed with congenital myopathies, 1 with muscular dystrophy, 3 with cardiomyopathy of unknown etiology, 9 had inconclusive testing, and 11 had miscellaneous diagnoses such as infantile botulism and arthrogyrosis.

How Do You Diagnose Mitochondrial Myopathies?

Due to the heteroplasmy as described previously, the definitive diagnosis of this disorder continues to require an open muscle biopsy to look for the pathognomonic sign of ragged red fibers. As abnormal mitochondria accumulate in the muscle fibers, Gomori trichrome stain will show increased red coloring at the periphery of the muscle fiber. This look is described as ragged red fibers. Laboratory studies and clinical picture are not sufficient for a diagnosis due to the genetic and clinical variation seen in mitochondrial myopathies.^{4,10} Improved blood and cerebrospinal fluid testing to diagnose many of these diseases may eliminate the need for performing muscle biopsy.^{1,11}

How Does Propofol Affect Mitochondria?

Propofol has been described to have several effects on the respiratory chain, including inhibition of Complex I and II along with modification of ATPase, which allows a proton leak reducing the proton gradient (fig. 1).^{2,12} The decreased production of ATP leads to decreased gluconeogenesis, increased glycogenolysis, increased glycolysis, and increased oxygen uptake.¹³ Increased glycolysis increases lactate and pyruvate production, which may be one reason that propofol

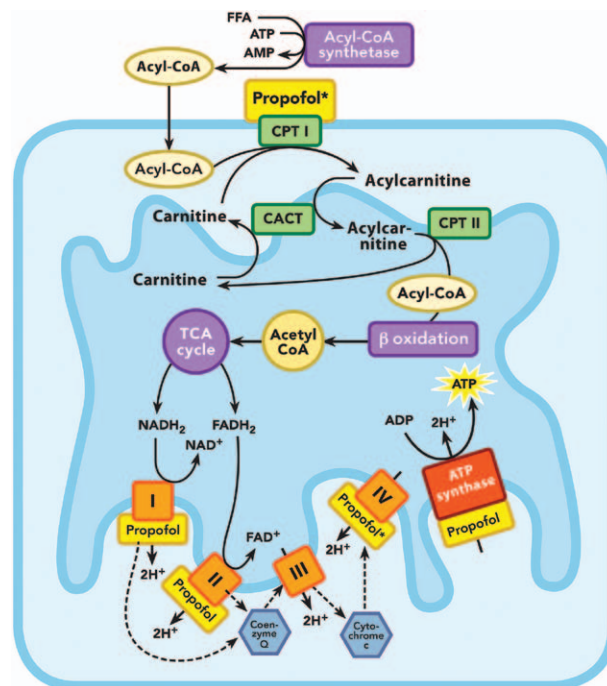


Fig. 1. Sites of propofol action within the mitochondrion. Propofol* denotes sites that are affected with high doses of propofol. ADP = adenosine diphosphate; AMP = adenosine monophosphate; ATP = adenosine triphosphate; CACT = carnitine acyl carnitine translocase; CoA = coenzyme A; CPT = carnitine palmitoyl transferase; FADH₂ = flavin adenine dinucleotide; FFA = free fatty acid; NADH₂ = nicotinamide adenine dinucleotide; TCA = tricarboxylic acid cycle.

could cause increased metabolic acidemia after an intravenous-based anesthetic technique.

Case reports in both children and adults have described a syndrome of metabolic acidosis, bradycardia, myocardial failure, rhabdomyolysis, and renal failure associated with propofol infusions. The etiology of propofol infusion syndrome is still not completely understood though it is known that high doses of propofol additionally inhibit Complex IV and carnitine palmitoyltransferase and also causes mitochondrial apoptosis.^{14,15} Propofol infusion syndrome and the acidosis seen with mitochondrial myopathies likely have related underlying pathologies.

How Do You Manage Patients with Mitochondrial Myopathies?

The types of associated symptoms and signs observed in mitochondrial myopathies influence the choice of anesthetic management. Propofol is avoided primarily based on its effects on mitochondrial metabolism. In many of these children, any catabolic stress such as fasting, infection, or surgery rapidly leads to hypoglycemia and acidosis, so modifications in the usual fasting recommendations and infusion of intravenous dextrose (either 5% or 10%) are included whereas solutions containing lactate are not recommended. Although there are no contraindications, the severity of

concomitant organ dysfunction associated with the mitochondrial disorder requires that an anesthetic plan be modified based on each patient's disease including presence of seizures, hypoventilation, acidemia, cardiomyopathy, renal or hepatic dysfunction, and aspiration risk. Volatile anesthetics can be used safely, but patients may have increased sensitivity requiring lower concentrations.¹⁶ Both sensitivity and resistance to nondepolarizing muscle relaxants have been reported.⁶ Succinylcholine has been used without adverse event,⁴ but caution is advised because the reported number of patients is small. Diaphragmatic muscle fiber atrophy and dysfunction is known to occur in individuals after positive pressure ventilation.^{17,18} Though the exact amount of time that it takes for this to occur in patients with preexisting myopathy is unknown, it is prudent to consider minimizing time on positive pressure ventilation when possible.

How Do You Manage Patients with Hypotonia of Unknown Etiology?

In infants and children presenting with an unknown cause of hypotonia, anesthetic recommendations are often based on a presumptive diagnosis. If the infant has had recurrent episodes of hypoglycemia and/or acidosis, our approach is to manage it as a potential mitochondrial myopathy. At present, in children who have mitochondrial myopathies, the approach is to use volatile anesthetics and avoid the use of propofol. In infants who do not have any metabolic abnormalities, propofol is used and succinylcholine and volatile agents are avoided. Regional anesthetic techniques as well as other induction anesthetic agents such as ketamine and etomidate could be considered, each with their unique profiles. Ketamine can cause increased intracranial and intraocular pressure, so caution should be exercised in patients in whom this increased pressure could be a cause for concern. Etomidate has the well-described effect of causing adrenocorticoid dysfunction even after a single dose, with prolonged use causing increased morbidity. The clinical significance of this after a single dose is not clear because the suppression resolves quickly.¹⁹

What Knowledge Gap Still Remains?

Due to the multitude of potential diagnoses for hypotonia, it is often difficult to decide which anesthetic would be best for each patient. The potential for a definitive laboratory diagnosis for myopathies would be helpful in limiting the number of infants who have undiagnosed myopathy presenting for anesthetic management. Additionally, if each mitochondrial myopathy's effects on electron transfer were better understood, then more specific recommendations could be made about the use of propofol. There may be many types of mitochondrial myopathies in which propofol would not cause a deterioration in mitochondrial function. In addition, research is needed to understand the conditions and medications that exacerbate the potential for metabolic decompensation in mitochondrial myopathies as well as to

determine what interventions are helpful in ameliorating those conditions.

References

1. Crean P, Hicks E: Essentials of neurology and neuromuscular disease, A Practice of Anesthesia for Infants and Children. 4th edition. Edited by Cote CJ, Lerman J, Todres D. Philadelphia, Saunders, 2009, pp 491–7
2. Lerman J: Perioperative management of the paediatric patient with coexisting neuromuscular disease. *Br J Anaesth* 2011; 107(suppl 1):i79–9
3. Klingler W, Rueffert H, Lehmann-Horn F, Girard T, Hopkins PM: Core myopathies and risk of malignant hyperthermia. *Anesth Analg* 2009; 109:1167–73
4. Footitt EJ, Sinha MD, Raiman JA, Dhawan A, Moganasundram S, Champion MP: Mitochondrial disorders and general anaesthesia: A case series and review. *Br J Anaesth* 2008; 100:436–41
5. Driessen J, Willems S, Dercksen S, Giele J, van der Staak F, Smeitink J: Anesthesia-related morbidity and mortality after surgery for muscle biopsy in children with mitochondrial defects. *Paediatr Anaesth* 2007; 17:16–1
6. Thompson VA, Wahr JA: Anesthetic considerations in patients presenting with mitochondrial myopathy, encephalopathy, lactic acidosis, and stroke-like episodes (MELAS) syndrome. *Anesth Analg* 1997; 85:1404–6
7. Ross AK: Muscular dystrophy *versus* mitochondrial myopathy: The dilemma of the undiagnosed hypotonic child. *Pediatr Anesth* 2007; 17:1–6
8. Muravchick S, Levy RJ: Clinical implications of mitochondrial dysfunction. *ANESTHESIOLOGY* 2006; 105:819–37
9. Chinnery PF, Howell N, Andrews RM, Turnbull DM: Clinical mitochondrial genetics. *J Med Genet* 1999; 36:425–36
10. Wong LJC: Diagnostic challenges of mitochondrial DNA disorders. *Mitochondrion* 2007; 7:45–2
11. Flick RP, Gleich SJ, Herr MM, Wedel DJ: The risk of malignant hyperthermia in children undergoing muscle biopsy for suspected neuromuscular disorder. *Paediatr Anaesth* 2007; 17:22–7
12. Rigoulet M, Devin A, Avéret N, Vandais B, Guérin B: Mechanisms of inhibition and uncoupling of respiration in isolated rat liver mitochondria by the general anesthetic 2,6-diisopropylphenol. *Eur J Biochem* 1996; 241:280–5
13. Acco A, Comar JF, Bracht A: Metabolic effects of propofol in the isolated perfused rat liver. *Basic Clin Pharmacol Toxicol* 2004; 95:166–74
14. Kam PC, Cardone D: Propofol infusion syndrome. *Anaesthesia* 2007; 62:690–1
15. Hsing CH, Chen YH, Chen CL, Huang WC, Lin MC, Tseng PC, Wang CY, Tsai CC, Choi PC, Lin CF: Anesthetic propofol causes glycogen synthase kinase-3 β -regulated lysosomal/mitochondrial apoptosis in macrophages. *ANESTHESIOLOGY* 2012; 116:868–81
16. Morgan PG, Hoppel CL, Sedensky MM: Mitochondrial defects and anesthetic sensitivity. *ANESTHESIOLOGY* 2002; 96:1268–70
17. Levine S, Nguyen T, Taylor N, Friscia ME, Budak MT, Rothenberg P, Zhu J, Sachdeva R, Sonnad S, Kaiser LR, Rubinstein NA, Powers SK, Shrager JB: Rapid disuse atrophy of diaphragm fibers in mechanically ventilated humans. *N Engl J Med* 2008; 358:1327–35
18. Mrozek S, Jung B, Petrof BJ, Pauly M, Roberge S, Lacampagne A, Cassan C, Thireau J, Molinari N, Futier E, Scheuermann V, Constantin JM, Matecki S, Jaber S: Rapid onset of specific diaphragm weakness in a healthy murine model of ventilator-induced diaphragmatic dysfunction. *ANESTHESIOLOGY* 2012; 117:560–7
19. Short TG, Young Y: Toxicity of intravenous anaesthetics. *Best Pract Res Clin Anaesthesiol* 2003; 17:77–9