

Case Scenario: Residual Curarization in Diabetic Polyneuropathy

Christoph Unterbuchner, M.D., Heidrun Fink, M.D., Achim Berthele, M.D., Manfred Blobner, M.D.



This article has been selected for the ANESTHESIOLOGY CME Program. Learning objectives and disclosure and ordering information can be found in the CME section at the front of this issue.

POSTOPERATIVE residual curarization is common after the use of muscle relaxants and may compromise patient outcome after general anesthesia.^{1–3} The incidence of postoperative residual curarization can be reduced by adequate neuromuscular block reversal and quantitative neuromuscular monitoring.^{4,5} However, in patients with severe pathologies of the peripheral nervous system, quantitative neuromuscular monitoring may become so difficult⁶ that standard monitoring techniques may fail, particularly when the anesthesiologist is oblivious to the concomitant disease. This case scenario should help the clinician to recognize the pitfalls of electrical nerve stimulation and to overcome the situation of poor stimulation success.

Case Report

A 65-yr-old male patient (having weight 112 kg, height 172 cm, and American Society of Anesthesiologists classification III) with a 54 yr history of type 1 diabetes mellitus was scheduled to undergo elective abdominal incisional hernia repair.

He was receiving immunosuppressive therapy, which consists of tacrolimus and prednisone, after receipt of a cadaveric donor kidney transplant, after long-lasting dialysis due to diabetic nephropathy. Renal function was compensated (serum creatinine level, 132.6 μM and serum urea level, 4.2 mM). He was *status post* an apoplectic stroke without residual paralysis; however, he had mild, bilateral symmetric paraesthesias of the upper and lower extremity of unknown origin.

Aside from immunosuppressive drugs, the patient's daily medication consisted of esmolol, aspirin, simvastatin, insulin, and omeprazole. Preoperative evaluation showed a normal range of the physiologic parameters. The patient received standard noninvasive monitoring (electrocardiogram, pulse oximetry, and noninvasive blood pressure). Anesthesia was

induced as a modified rapid-sequence induction, due to acid reflux, with intravenous administration of 25 μg of sufentanil, 230 mg of propofol, and 100 mg of rocuronium. Anesthesia was maintained with isoflurane at 1.0 minimum alveolar concentration in 40% oxygen in air. Ventilation was controlled to maintain end-tidal normocapnia (30–35 mmHg). No more rocuronium was injected. Core body temperature was kept constant more than 36°C by convective warming (Warm Touch 5800; Tyco Healthcare Deutschland GmbH, Neustadt, Germany). Ten minutes after relaxation, uncalibrated, quantitative, kinemyographic neuromuscular monitoring was performed on the right forearm (Neuromuscular Transmission Module, M-NMT; GE Healthcare, Helsinki, Finland).

The ulnar nerve was stimulated with a 70-mA train-of-four (TOF) pattern at 20-s intervals (pulse width 200 ms, square wave). Initially, no response could be recorded. After 75 min, at the end of the operation procedure, response to TOF stimulation could still not be detected, and the patient was transferred to the postanesthesia care unit assuming residual curarization. Anesthesia was maintained with propofol (5 mg $\text{kg}^{-1} \text{h}^{-1}$). Neuromuscular monitoring was continued with acceleromyography using the portable TOF-Watch[®] device (Essex Pharma GmbH, München, Germany). Uncalibrated TOF stimulation of the ulnar nerve (70 mA, pulse width 200 ms, square wave) at 20-s intervals elicited minimal twitch response of the adductor pollicis muscle. At 110 min after injection of rocuronium, the TOF ratio was still 10–20%. Therefore, 230 mg of sugammadex was injected to accelerate neuromuscular recovery. Surprisingly, there was still no change in the TOF ratio. Visual and tactile detection showed four very weak twitches. We doubted the values of our neuromuscular monitoring; therefore, 10 min after injection of sugammadex, we tested neuromuscular

This article is featured in "This Month in Anesthesiology," page 1A. Table 1 and figure 2 were created by Annemarie B. Johnson, C.M.I., Medical Illustrator, Vivo Visuals, Winston-Salem, North Carolina.

Submitted for publication October 26, 2012. Accepted for publication July 29, 2013. From the Klinik für Anaesthesiologie (C.U., H.F., M.B.) and Neurologische Klinik und Poliklinik (A.B.), Klinikum rechts der Isar, Technische Universität München, Munich, Germany.

Copyright © 2013, the American Society of Anesthesiologists, Inc. Lippincott Williams & Wilkins. Anesthesiology 2014; 120:474–9

function at other sites. Acceleromyography performed at the contralateral arm and the left and right tibial posterior nerves showed a similar weak muscle contraction. In contrast, stimulation of the motor branches of the right and the left facial nerves with 35 mA revealed qualitatively strong muscle contractions of the orbicularis oculi muscles, which could be quantified with TOF ratios between 95 and 100% (piezoelectric probe positioned on the external half of the upper eyelid; fig. 1). Therefore, the propofol infusion was stopped. Once the patient was awake, cooperative, and breathing sufficiently, he was extubated. After extubation, the patient was able to lift his arm for more than 5 s, lift his head for more than 5 s, keep his eyes open for more than 5 s, and swallow 20 ml water. The next day, electrophysiological examination revealed a diabetic peripheral polyneuropathy due to long-standing diabetes mellitus. It was suggested that diabetic peripheral neuropathy was responsible for the failure of quantitative neuromuscular monitoring.

Discussion

Epidemiology and Classification of Diabetic Peripheral Neuropathy

Diabetic peripheral neuropathy is the most common form of neuropathy worldwide with a prevalence of 70% in patients with diabetes mellitus. Diffuse or focal damage of different nerve fibers provokes a wide variety of symptoms.⁷ Half of patients with this condition suffer from distal symmetric sensorimotor polyneuropathy which progresses following a fiber-length-dependent pattern (length-dependent diabetic polyneuropathy).^{8,9} An anatomic-modified classification scheme summarizes the different entities of manifestation proposed by Thomas¹⁰ (table 1). There are two different categories of symptoms: “Positive symptoms” include pain, paresthesia, and aberrant sensitivity to external stimuli and “Negative symptoms” are loss of sensory perception of different modalities and muscle weakness.^{11,12} Three distinct categories of length-dependent diabetic polyneuropathy can be distinguished: acute painful remitting neuropathy, chronic painful neuropathy, and painless neuropathy with ulcer.^{13,14} Distal muscle weakness is an end-stage symptom and is usually found in patients with long-term diabetes mellitus with symptomatic diabetic peripheral neuropathy, with an annual decline of muscle strength of 3%.¹⁵

Pathophysiology of Diabetic Peripheral Neuropathy

Duration of diabetes mellitus and poor metabolic control are well-known risk factors for the development of diabetic peripheral neuropathy.¹⁶ Pathophysiologically, three factors result in an impaired axonal function: deterioration of the microvascular, endoneural circulation with ischemia of the axons and glial cells; malfunction of the axon–glial relationship; and segmental or paranodal demyelination, axonal injury, and following this, Wallerian degeneration.^{17,18}

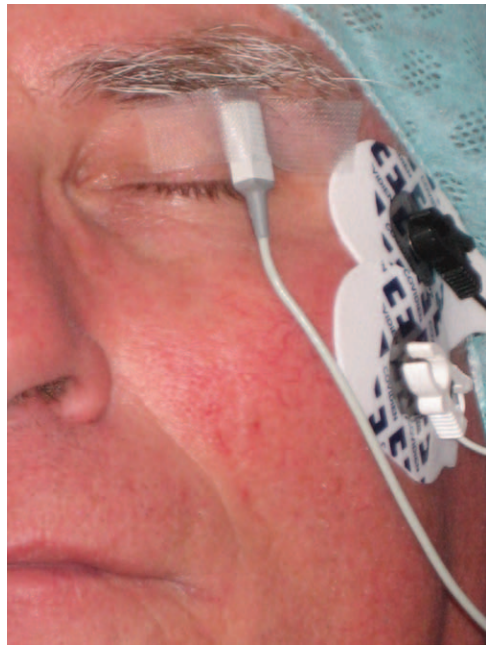

Fig. 1. Stimulation of the facial nerve (rami zygomatici) with electrodes and positioning of the piezoelectric probe of the TOF-Watch® device (Essex Pharma GmbH, München, Germany) on the external half of the upper eyelid to measure the acceleration of the orbicularis oculi muscle.

Typical of diabetic peripheral neuropathy is its symmetric, bilateral presentation with a progression from distal to proximal. This may arise from the fact that the longest axons of the body will most likely be affected by a number of local damages, and their performance will be impaired first.^{19,20}

In our patient, other pathognomonic reasons for his neuropathy have to be discussed. Tacrolimus can cause neuropathy, and case reports have previously described difficulties in peripheral nerve stimulation in patients receiving this agent.²¹ In addition, chronic inflammatory demyelinating polyneuropathy occurs more frequently in patients with diabetes mellitus than can be explained by chance alone.²² Long-standing diabetes mellitus and chronic hemodialysis are frequently associated with amyloidosis and consecutive compression of the nerves at the wrist. Therefore, aside from possible carpal tunnel syndrome, Loge de Guyon syndrome (compression of the ulnar nerve beneath the ligamentum carpi palmare) could impair the nerval conduction in the distal ulnar nerve and the response to external electrical stimulation.²³ Furthermore, obesity and edematous tissue could also potentially impair stimulation success.

Electrophysiological Findings in Diabetic Peripheral Neuropathy

Common neurophysiological findings for the various forms of diabetic peripheral neuropathy include decreased nerve conduction velocity, as a sign of demyelination of large peripheral fibers, and reduced amplitude of nerve compound action potential, as a sign of fiber axonopathy.^{9,11,24}

The grade of clinical severity of the neuropathy is more closely related to the loss of response amplitudes than to the reduction of conduction velocity, as the former reflects the number of fibers in the nerve.²⁵

Our patient had clinically paresthetic symptoms of length-dependent diabetic polyneuropathy. The patient showed no obvious signs of peripheral muscle wasting (hand muscles) and experienced no impairment of upper and lower limb muscle strength in his day-to-day life.

Electrophysiological testing of the sensory and motor fibers of the extremities directly identified a reduced distal conduction velocity, reduced compound action potential, long-loop latencies, and a distal-to-proximal conduction gradient (fig. 2).²⁶

Quantitative Neuromuscular Monitoring in Diabetic Peripheral Neuropathy

Calibration of quantitative neuromuscular-monitoring device (see Device Calibration) is successful in less than 60% of patients with diabetes mellitus compared with more than 90% of patients without diabetes mellitus.⁶ Pathologic and morphologic changes in neuropathic nerve fibers themselves could be responsible for the poor stimulation response. The reduction and splitting of the compound muscle

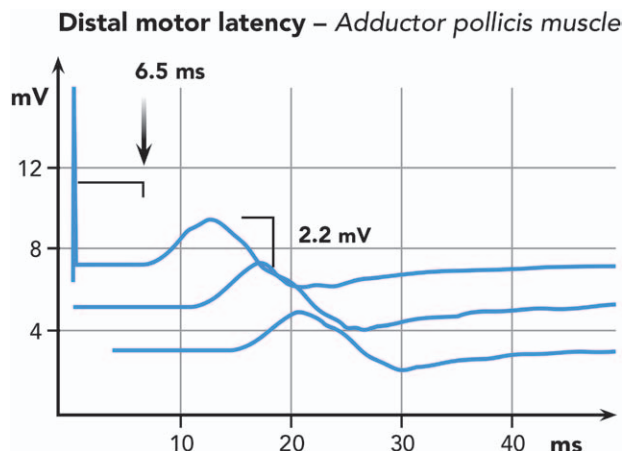


Fig. 2. Ulnar nerve motor conduction study in a mixed axonal and demyelinating polyneuropathy. The ulnar nerve is electrically stimulated distally and proximally, and the myoelectric response of the adductor pollicis muscle is recorded. Upper trace: stimulation at the wrist, 7 cm proximal to the recording electrode. Middle trace: stimulation below the elbow sulcus. Lower trace: stimulation above the elbow sulcus (x-axis: 5 ms/div; y-axis: 2 mV/div). The latencies between stimulation and muscle response allow determining the ulnar motor nerve conduction velocity; the amplitude of the compound muscle action potential serves as a measure of the number of activated axons. Delayed distal motor latency (upper trace: 6.5 ms, upper limit of normal 3.5 ms), reduced conduction velocities (middle trace: 44 m/s at the forearm, lower limit of normal 50 m/s; and lower trace: 31 m/s at the elbow), disclosed demyelination, and reduced compound muscle action potentials (e.g., upper trace: 2.2 mV, lower limit of normal 8 mV), combined with electromyographic findings, indicated axonal loss.

action potential of the stimulated muscle can indicate that supramaximal stimulation was not obtained.⁶

Supramaximal stimulation current in evoked electromyography analysis is higher in patients with diabetes mellitus than that in patients without diabetes mellitus.²⁷ Partial nerve degeneration with axon loss, segmental demyelination, diseased neuromuscular junctions, and the consecutive loss of motor units could impair the stimulation response further.^{28,29} Damage to the muscle typical of diabetes, such as infarction, atrophy, and denervation, can also interfere with a successful stimulation.³⁰

Although we stimulated our patient's ulnar nerve with the highest possible charges of our device (constant current devices varying the generated voltage), which is the product of current intensity (70 mA) and stimulus pulse width (200 ms), there was insufficient motor reaction of the adductor pollicis muscle. It is possible that the routinely delivered charges in everyday clinical use do not trigger the maximum recruitment of nerve fibers because of the fewer functioning sodium channels of the axons. This is especially relevant for single-twitch stimulation, while the TOF ratio is a relative value, as it represents the ratio of the fourth twitch response to the first. If the neuromuscular-monitoring device is successfully calibrated before administering a muscle relaxant, the applied stimulus is usually 15–20% higher than the necessary threshold for maximal muscle contraction.³¹

General Aspects of Neuromuscular Stimulation

Essential for every neuromuscular stimulation technique are general factors such as correct electrode placement, polarity, and impedance. To achieve the best stimulation response, the contact area of the stimulation electrodes should be 7–11 mm in diameter and the distance between the electrodes should be 3–6 cm. Current density and muscle contraction are greatest if the polarity of the distal electrode is negative.³² Skin temperature should be kept above 35°C, as hypothermia decreases mechanically measured TOF ratios and is inversely related to the electromyographical signal.^{33,34}

Pitfalls of Different Detecting Methods

If the response to nerve stimulation is inadequate, specific technical pitfalls have to be considered. In our patient, we initially used kinemyography (Neuromuscular Transmission Module, M-NMT; GE Healthcare), an established tool for quantitative neuromuscular monitoring, which is integrated into our standard monitor. The piezoelectric sensor needs to be securely fixed in the correct position to avoid artefacts and unreproducible TOF ratios.

In the postanesthesia care unit, we monitored neuromuscular function with an acceleromyography device (TOF-Watch[®]; Essex Pharma GmbH). Although acceleromyography has a good agreement with mechanomyographic and electromyographical measurements, its use at sites other than the adductor pollicis muscle (e.g., orbicularis oculi muscle) is restricted.³⁵ Acceleromyographic accuracy is highly dependent

on the muscle mass monitored and the position of the piezoelectric transducer.³⁶ Generally speaking, acceleromyography tends to overestimate TOF ratios. Therefore, to avoid any risk of residual curarization, it is recommended that the acceleromyography-measured TOF ratio should be 1.0 or above.³⁷

Device Calibration

Every objective neuromuscular-monitoring device should be calibrated before injecting a muscle relaxant to reduce the levels of incidental background noise. This is especially important in patients with neuromuscular disorders to identify individual nerve pathology, as seen in the presented case.³¹ Calibrated acceleromyography is able to identify up to 97% of cases of residual paralysis,³⁷ with visualization of the stimulation response curve helping to indicate a pathologic twitch response. In the presented case, however, calibration was not performed before injection of the neuromuscular-blocking agent. If this mistake had not been made, failure to accomplish supramaximal stimulation would have been detected and repositioning of the stimulation electrodes or changing stimulation site would have subsequently been attempted. The lack of stimulation response would have therefore become evident.

Stimulation Site

The adductor pollicis muscle is the most commonly used site to monitor neuromuscular function, as it is one of the last muscle groups to recover from neuromuscular block.³⁶ Recovery of the adductor pollicis is similar to that of the upper airway muscles, and it reflects sufficient protection reflexes and opening of the upper airway.

Because no stimulation response could be obtained at the forearm of the patient in the present case, we stimulated the facial nerve (rami zygomatici) and monitored the corresponding orbicularis oculi muscle by acceleromyography (piezoelectric probe positioned on the external half of the upper eyelid; fig. 1). Retrospectively in this specific case, this stimulation site was advantageous, because the cranial nerves are infrequently involved in length-dependent diabetic polyneuropathy.¹⁵ In addition, responses to neuromuscular monitoring at the orbicularis oculi muscle are similar to that at the adductor pollicis muscle. Typical current intensity is 20 mA for stimulating the facial nerve; therefore, direct muscle stimulation of the orbicularis oculi could not definitely be eliminated by the stimulation currents of 35 mA used in this case. Monitoring of muscles at one region does not always provide the full image of recovery of other muscle groups. Indeed, the diaphragm, corrugator supercilii, and laryngeal muscles are considerably more resistant to muscle relaxants than the adductor pollicis and orbicularis oculi muscles.³⁸

Alternative Management of Muscle Relaxation in Patients with Neurological Diseases

On the basis of the TOF ratio of 10–20%, we injected 230 mg (2 mg/kg) of sugammadex, which is the recommended dose for reversal of rocuronium-induced neuromuscular blockade

Table 1.

Classification of Diabetic Neuropathy	
Diffuse	Focal
<ul style="list-style-type: none"> • Distal symmetric sensorimotor polyneuropathy • Symmetric proximal lower limb motor neuropathy (amyotrophy) • Autonomic neuropathy <ul style="list-style-type: none"> – Sudomotor (cholinergic innervation of the sympathetic nervous system of sweat glands) – Cardiovascular – Gastrointestinal – Genitourinary 	<ul style="list-style-type: none"> • Cranial neuropathy • Radiculopathy/plexopathy • Entrapment neuropathy • Asymmetric limb motor neuropathy (amyotrophy)

after reappearance of T_2 .³⁹ The intravascular encapsulating mechanism of action, distant from the neuromuscular junction, was considered ideal for reversing shallow and deep blocks, especially in a patient with neuromuscular pathology. We predicted that administration of 2 mg/kg of sugammadex after reappearance of T_2 for reversal of rocuronium-induced residual neuromuscular blockade would result in rapid recovery.³⁹ The lack of change in TOF ratio after sugammadex administration thus caused us to mistrust the uncalibrated neuromuscular monitoring and to consider alternative nerve-muscle pairs. Although in retrospect neuromuscular function may have recovered before sugammadex, its administration guided us to recognize the underlying problem in this patient.

Knowledge Gap

The knowledge about electrophysiology of diabetic polyneuropathy is not incorporated in the technique of quantitative neuromuscular monitoring. Accordingly, a strategy neither to identify patients with poor stimulation success nor to overcome the respective shortcoming has been developed. On the basis of electrophysiological changes, alternative stimulation patterns must be investigated; for example, investigation as to whether extending the current above 70 mA or extending the impulse width above 200 ms improves stimulation quality at the ulnar nerve. Furthermore, the validity of neuromuscular monitoring of the orbicularis oculi muscle in patients with diabetes mellitus with peripheral neuropathy could help to prevent postoperative residual curarization and its poor outcome after general anesthesia.

Conclusion

Muscle relaxants have to be used very carefully in patients with neuromuscular disorders. Calibration of any neuromuscular-monitoring device before application of muscle relaxants is essential, so that poor stimulation can be recognized and improved. Although neuromuscular monitoring of the adductor pollicis muscle remains the definitive standard, neuromuscular monitoring at alternative sites, for example, the orbicularis oculi muscle, could improve the grading of relaxation in diabetic peripheral polyneuropathy.

Acknowledgments

Editorial assistance was provided by Melanie More, B.Sc. (Prime Medica Ltd., Knutsford, Cheshire, United Kingdom), during the final stages of this article.

Support was provided solely from institutional and/or departmental sources.

Competing Interests

The authors declare no competing interests.

Correspondence

Address correspondence to Dr. Unterbuchner: Klinik für Anaesthesiologie, Technische Universität München, Klinikum rechts der Isar, Munich 81675, Germany. christoph.unterbuchner1@freenet.de. This article may be accessed for personal use at no charge through the Journal Web site, www.anesthesiology.org.

References

- Murphy GS, Szokol JW, Marymont JH, Greenberg SB, Avram MJ, Vender JS: Residual neuromuscular blockade and critical respiratory events in the postanesthesia care unit. *Anesth Analg* 2008; 107:130–7
- Harrison GG: Death attributable to anaesthesia. A 10-year survey (1967–1976). *Br J Anaesth* 1978; 50:1041–6
- Arbous MS, Meursing AE, van Kleef JW, de Lange JJ, Spoormans HH, Touw P, Werner FM, Grobbee DE: Impact of anesthesia management characteristics on severe morbidity and mortality. *ANESTHESIOLOGY* 2005; 102:257–68
- Baillard C, Clec'h C, Catoire J, Salhi F, Gehan G, Cupa M, Samama CM: Postoperative residual neuromuscular block: A survey of management. *Br J Anaesth* 2005; 95:622–6
- Murphy GS, Szokol JW, Marymont JH, Greenberg SB, Avram MJ, Vender JS, Nisman M: Intraoperative acceleromyographic monitoring reduces the risk of residual neuromuscular blockade and adverse respiratory events in the postanesthesia care unit. *ANESTHESIOLOGY* 2008; 109:389–98
- Knüttgen D, Burgwinkel W, Nieden KZ, Jahn M, Müller-Gorges MR, Doehn M: Limited applicability of the DATEX Relaxograph in diabetics with peripheral polyneuropathy. *Int J Clin Monit Comput* 1996; 13:21–5
- Greene DA, Stevens MJ, Feldman EL: Diabetic neuropathy: Scope of the syndrome. *Am J Med* 1999; 107(2B):2S–8S
- Argoff CE, Cole BE, Fishbain DA, Irving GA: Diabetic peripheral neuropathic pain: Clinical and quality-of-life issues. *Mayo Clin Proc* 2006; 81(4 suppl):S3–11
- Vinik AI, Mehrabian A: Diabetic neuropathies. *Med Clin North Am* 2004; 88:947–99
- Thomas PK: Classification, differential diagnosis, and staging of diabetic peripheral neuropathy. *Diabetes* 1997; 46(suppl 2):S54–7
- Horowitz SH: Diabetic neuropathy. *Clin Orthop Relat Res* 1993; 296:78–85
- Dyck PJ: Detection, characterization, and staging of polyneuropathy: Assessed in diabetics. *Muscle Nerve* 1988; 11:21–32
- Young RJ, Zhou YQ, Rodriguez E, Prescott RJ, Ewing DJ, Clarke BF: Variable relationship between peripheral somatic and autonomic neuropathy in patients with different syndromes of diabetic polyneuropathy. *Diabetes* 1986; 35:192–7
- Young RJ, Ewing DJ, Clarke BF: Chronic and remitting painful diabetic polyneuropathy. Correlations with clinical features and subsequent changes in neurophysiology. *Diabetes Care* 1988; 11:34–40
- Andreassen CS, Jakobsen J, Andersen H: Muscle weakness: A progressive late complication in diabetic distal symmetric polyneuropathy. *Diabetes* 2006; 55:806–12
- Keen H: The Diabetes Control and Complications Trial (DCCT). *Health Trends* 1994; 26:41–3
- Sima AA, Nathaniel V, Bril V, McEwen TA, Greene DA: Histopathological heterogeneity of neuropathy in insulin-dependent and non-insulin-dependent diabetes, and demonstration of axo-glial dysjunction in human diabetic neuropathy. *J Clin Invest* 1988; 81:349–64
- Dyck PJ, Lambert EH, O'Brien PC: Pain in peripheral neuropathy related to rate and kind of fiber degeneration. *Neurology* 1976; 26:466–71
- House SD, Johnson PC: Microvascular pressure in venules of skeletal muscle during arterial pressure reduction. *Am J Physiol* 1986; 250(5 Pt 2):H838–45
- Dyck PJ, Lais A, Karnes JL, O'Brien P, Rizza R: Fiber loss is primary and multifocal in sural nerves in diabetic polyneuropathy. *Ann Neurol* 1986; 19:425–39
- Bhagavati S, Maccabee P, Muntean E, Sumrani NB: Chronic sensorimotor polyneuropathy associated with tacrolimus immunosuppression in renal transplant patients: Case reports. *Transplant Proc* 2007; 39:3465–7
- Stewart JD, McKelvey R, Durcan L, Carpenter S, Karpati G: Chronic inflammatory demyelinating polyneuropathy (CIDP) in diabetics. *J Neurol Sci* 1996; 142:59–64
- Staub F, Dombert T, Assmus H: [Carpal tunnel syndrome in haemodialysis patients: Analysis of clinical and electrophysiological findings in 268 patients (395 hands)]. *Handchir Mikrochir Plast Chir* 2005; 37:150–7
- Sugimoto K, Murakawa Y, Sima AA: Diabetic neuropathy—A continuing enigma. *Diabetes Metab Res Rev* 2000; 16:408–33
- Dyck PJ, Litchy WJ, Daube JR, Harper CM, Dyck PJ, Davies J, O'Brien PC: Individual attributes *versus* composite scores of nerve conduction abnormality: Sensitivity, reproducibility, and concordance with impairment. *Muscle Nerve* 2003; 27:202–10
- Arezzo JC, Brosnan CF, Schroeder CE, Litwak MS, Bornstein MB: Electrophysiological analysis of factors involved in the primary demyelinating diseases: The rabbit eye model system. *Brain Res* 1988; 462:286–300
- Saitoh Y, Kaneda K, Hattori H, Nakajima H, Murakawa M: Monitoring of neuromuscular block after administration of vecuronium in patients with diabetes mellitus. *Br J Anaesth* 2003; 90:480–6
- Abu-Shakra SR, Cornblath DR, Avila OL, Chaudhry V, Freimer M, Glass JD, Reim JW, Ronnett GV: Conduction block in diabetic neuropathy. *Muscle Nerve* 1991; 14:858–62
- Lamontagne A, Buchthal F: Electrophysiological studies in diabetic neuropathy. *J Neurol Neurosurg Psychiatry* 1970; 33:442–52
- Van Slyke MA, Ostrov BE: MRI evaluation of diabetic muscle infarction. *Magn Reson Imaging* 1995; 13:325–9
- Fuchs-Buder T, Claudius C, Skovgaard LT, Eriksson LI, Mirakhur RK, Viby-Mogensen J; 8th International Neuromuscular Meeting: Good clinical research practice in pharmacodynamic studies of neuromuscular blocking agents II: The Stockholm revision. *Acta Anaesthesiol Scand* 2007; 51:789–808
- Berger JJ, Gravenstein JS, Munson ES: Electrode polarity and peripheral nerve stimulation. *ANESTHESIOLOGY* 1982; 56:402–4
- Engbaek J, Skovgaard LT, Friis B, Kann T, Viby-Mogensen J: Monitoring of the neuromuscular transmission by electromyography (I). Stability and temperature dependence of evoked EMG response compared to mechanical twitch recordings in the cat. *Acta Anaesthesiol Scand* 1992; 36:495–504
- Heier T, Caldwell JE: Impact of hypothermia on the response to neuromuscular blocking drugs. *ANESTHESIOLOGY* 2006; 104:1070–80
- Kirkegaard-Nielsen H, Helbo-Hansen HS, Lindholm P, Pedersen HS, Severinsen IK, Schmidt MB: New equipment

- for neuromuscular transmission monitoring: A comparison of the TOF-Guard with the Myograph 2000. *J Clin Monit Comput* 1998; 14:19–27
36. Hemmerling TM, Le N: Brief review: Neuromuscular monitoring: An update for the clinician. *Can J Anaesth* 2007; 54:58–72
 37. Capron F, Alla F, Hottier C, Meistelman C, Fuchs-Buder T: Can acceleromyography detect low levels of residual paralysis? A probability approach to detect a mechanomyographic train-of-four ratio of 0.9. *ANESTHESIOLOGY* 2004; 100:1119–24
 38. Plaud B, Debaene B, Donati F: The corrugator supercilii, not the orbicularis oculi, reflects rocuronium neuromuscular blockade at the laryngeal adductor muscles. *ANESTHESIOLOGY* 2001; 95:96–101
 39. Blobner M, Eriksson LI, Scholz J, Motsch J, Della Rocca G, Prins ME: Reversal of rocuronium-induced neuromuscular blockade with sugammadex compared with neostigmine during sevoflurane anaesthesia: Results of a randomised, controlled trial. *Eur J Anaesthesiol* 2010; 27:874–81