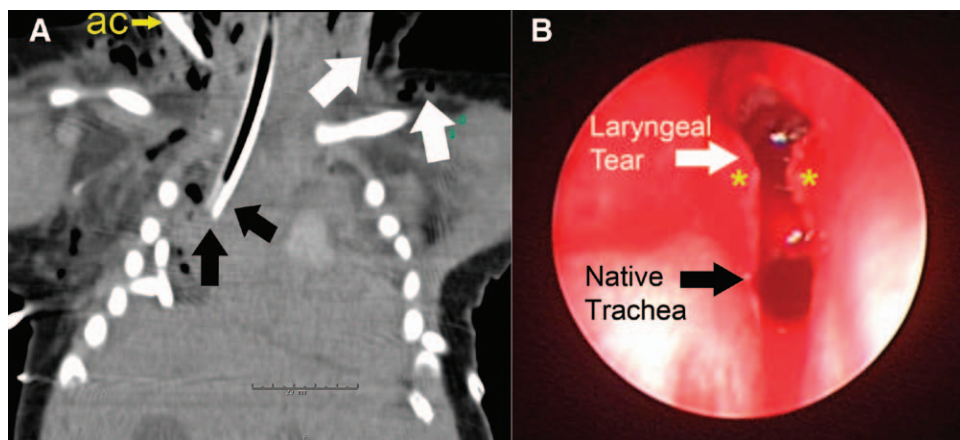


Charles D. Collard, M.D., Editor
 Alan Jay Schwartz, M.D., M.S. Ed., Associate Editor

Shoulder Dystocia, Laryngeal Tear, Mediastinal Intubation, and Extracorporeal Membrane Oxygenation in a Neonate

Allan F. Simpao, M.D., Luv R. Javia, M.D., Alan Jay Schwartz, M.D., M.S.Ed., Mohamed A. Rehman, M.D.



A 5.6-KG term neonate was born *via* spontaneous vaginal delivery complicated by shoulder dystocia; Apgar scores were 5 and 7 at 1 and 5 min. The neonate received continuous positive airway pressure for respiratory distress, developed cervical emphysema, and then was intubated because of hypoxemia. Although capnography appeared to indicate a successful intubation, breath

sounds were undetectable by auscultation. Chest tubes were placed after a radiograph showed bilateral pneumothoraces.

The neonate arrived at our institution *in extremis* (heart rate, 59 beats/min; mean arterial pressure, 50 mmHg; SpO₂, 62%). Venoarterial extracorporeal membrane oxygenation was initiated *via* the right internal jugular vein and the right internal carotid artery. Computed tomography showed absent lung aeration, the arterial cannula (fig. 1A, ac), subcutaneous emphysema (fig. 1A, white arrows), and the endotracheal tube diverging from the midline (fig. 1A, black arrows). Bronchoscopy by the otorhinolaryngologist confirmed a laryngeal tear with a ruptured anterior commissure (fig. 1B, asterisks) through which the endotracheal tube traveled into the mediastinum. The otorhinolaryngologist repositioned the endotracheal tube into the native trachea (fig. 1B). Support was withdrawn 6 days later after progression of hypoxic ischemic injury. Autopsy findings included a hypoplastic thyroid cartilage that likely resulted in an inherent weakness of the anterior tracheal wall.

Traumatic delivery and endotracheal intubation can cause life-threatening tracheal and laryngeal injuries in neonates.¹ Development of cervical emphysema before intubation suggests that this child's laryngeal rupture was caused by a difficult delivery rather than traumatic intubation. Fiberoptic endoscopy should be used to investigate potential airway rupture, with emergent otorhinolaryngology consultation and deferral of endotracheal intubation until direct airway visualization has been accomplished.² Extracorporeal membrane oxygenation should be considered early if direct airway visualization cannot be performed.³

Competing Interests

The authors declare no competing interests.

Correspondence

Address correspondence to Dr. Simpao: simpaoa@email.chop.edu

References

1. Mahieu HF, de Bree R, Ekkelkamp S, Sibarani-Ponsen RD, Haasnoot K: Tracheal and laryngeal rupture in neonates: Complication of delivery or of intubation? *Ann Otol Rhinol Laryngol* 2004; 113:786–92
2. Kacmarynski DS, Sidman JD, Rimell FL, Husted VA: Spontaneous tracheal and subglottic tears in neonates. *Laryngoscope* 2002; 112(8 Pt 1):1387–93
3. Kunisaki SM, Fauza DO, Craig N, Jennings RW: Extracorporeal membrane oxygenation as a bridge to definitive tracheal reconstruction in neonates. *J Pediatr Surg* 2008; 43:800–4

From the Department of Anesthesiology and Critical Care Medicine, Perelman School of Medicine, University of Pennsylvania, and The Children's Hospital of Philadelphia, Philadelphia, Pennsylvania (A.F.S.).

Copyright © 2013, the American Society of Anesthesiologists, Inc. Lippincott Williams & Wilkins. *Anesthesiology* 2014; 120:480