

# Fatal Pancreatic Injury due to Trauma after Successful Cardiopulmonary Resuscitation with Automatic Mechanical Chest Compression

Pauline Deras, M.D., Jonathan Manzanera, M.D., Ingrid Millet, M.D., Jonathan Charbit, M.D., Xavier Capdevila, M.D., Ph.D.

**T**HE reported incidence of out-of-hospital cardiac arrest varies according to different states. This incidence has been estimated at 1.89/1,000 person-years in the United States<sup>1</sup> and at 0.55/1,000 in France.<sup>2</sup> As per published reports, survival rates for out-of-hospital cardiac arrest range from 3 to 16% in North America,<sup>3</sup> whereas the survival rate in France is 21% after initial resuscitation, decreasing to 2.5% after 1 month.<sup>2</sup> Strict French guidelines<sup>2</sup> consider as essential the effectiveness of chest compression during cardiopulmonary resuscitation (CPR) and propose the use of automatic mechanical chest compression for prolonged or prehospital CPR. This case report describes a fatal pancreatic injury due to trauma after successful CPR with automatic mechanical chest compression. One only other case of pancreatic injury was described in pediatrics by Waldman *et al.*<sup>4</sup> during conventional CPR in a child, augmented with interposed abdominal compressions.

## CASE REPORT

A 32-yr-old man with body mass index of 22 kg/m<sup>2</sup> presented with sudden out-of-hospital cardiac arrest, without any previous trauma. Manual CPR was immediately begun by an experienced first-aider during the 10 min before the arrival of the medical prehospital team (French emergency and resuscitation mobile service). Mechanical chest compressions using the LUCAS device (Lund University Cardiopulmonary Assist System; Jolife AB, Lund, Sweden) were immediately started by the physician arrived on scene, who has been specifically trained to position and use this device. The airway was thus secured by tracheal intubation. The initial electrocardiogram, 10 min after cardiac arrest, showed asystole. An overall dose of 25 mg of epinephrine was injected within a 40-min medicalized CPR period and cardiac rhythm changed to ventricular fibrillation, which necessitated 10 defibrillations with 360 J. A sinus rhythm and a spontaneous cardiac output were recovered after a total

of 50 min in total, and then he was quickly transported to hospital. The epinephrine infusion was set at a rate of 1 mg/h to sustain an acceptable blood pressure. At the arrival, trans-thoracic echocardiography showed a ventricular left ejection fraction of 30% with an anteroapical hypokinesis. A cardiac angiography performed within the hour after patient admission showed a total occlusion of the left anterior descending artery associated with arteriosclerosis of coronary arteries. The artery was dilated and a bare-metal stent was positioned after administration of anticoagulant (heparin 4,000 U) and antiplatelet therapies (aspirin 500 mg, clopidogrel 600 mg).

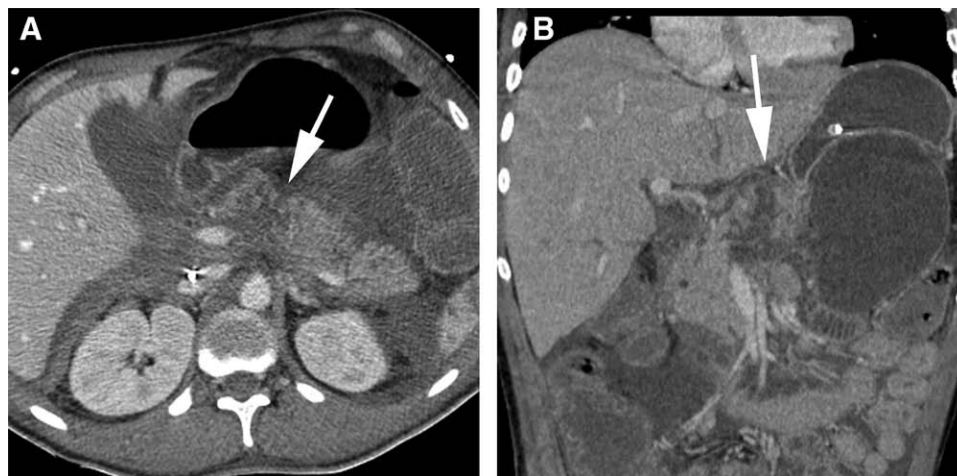After the procedure, the patient was taken to the intensive care unit. Body cooling was initiated to maintain therapeutic hypothermia at 33°C for 12 h, before progressive rewarming over the next 12 h. The patient developed a postcardiac syndrome with multiorgan failure, requiring volemic expansion, norepinephrine and dobutamine, and continuous venovenous hemofiltration. At the end of 96 h, his clinical status gradually improved. Continuous infusions of amines were stopped on day 9; normalization of coagulation and liver enzymes was noted on day 6. Hemofiltration had to be continued because of persistent renal failure. After discontinuation of sedation on day 5, the patient had an awakening delay with gradual emergence of response to nociceptive stimuli and appropriate orders. On day 14, rectal bleeding necessitated transfusion of 5 units of erythrocytes, 3 units of fresh-frozen plasma, and 1 unit of platelet concentrate. A subsequent colonoscopy found ischemic colitis in the transverse and left colon. On day 15, abdominopelvic tomodensitometry revealed a large pancreatic pseudocyst complicating pancreatic fracture due to trauma, grade III in the American Association for the Surgery of Trauma classification, without any signs of bowel perforation or thoracic injuries. This pancreatic fracture was probably due to abdominal mechanical compression by inadvertent movement of the LUCAS device. As a result of hemodynamic and digestive deterioration, the patient was laparotomized on day 18. A pancreatic pseudocyst and a peritoneal effusion

Written agreement was obtained from the family for the publication of this report.

Corresponding article on page 797.

Submitted for publication June 6, 2013. Accepted for publication October 21, 2013. From the Trauma Center and Department of Anesthesiology and Critical Care Medicine, Lapeyronie University Hospital, Montpellier, France (P.D., J.M., and J.C.); Department of Radiology, Lapeyronie University Hospital, Montpellier, France (I.M.); and Trauma Center and Department of Anesthesiology and Critical Care Medicine, University of Montpellier, Montpellier, France, and INSERM Unit U1046, Batiment Crastes de Paulet, Montpellier, France (X.C.).

Copyright © 2014, the American Society of Anesthesiologists, Inc. Lippincott Williams & Wilkins. Anesthesiology 2014; 120:1038–41



**Fig. 1.** Computed tomography (CT) scan showing the traumatic fracture of the pancreas (*white arrows*). (A) Axial contrast-enhanced CT scan (venous phase); (B) Coronal contrast-enhanced CT scan (venous phase).

of 3 l of serous liquid associated with rupture of the Wirsung duct were evacuated and drained. Broad-spectrum antibiotics (piperacillin-tazobactam, amikacine, and fluconazole) were initiated. A new tomodensitometry scan was performed on day 30 because of clinical deterioration and suspicion of a pancreatic fistula (fig. 1). The pancreatic fistula was confirmed as well as chemical peritonitis and gangrenous cholecystitis. A second laparotomy was carried out for cholecystectomy, peritoneal lavage, and drainage. In the postoperative period, a massive hemorrhagic shock related to venous diffuse bleeding of the pancreas required surgical hemostasis, which was finally impossible. The patient died on day 30 after refractory ventricular tachycardia and fibrillation secondary to uncontrolled massive hemorrhage.

## Discussion

In this case report, we described a fatal pancreatic injury due to trauma, grade III in the American Association for the Surgery of Trauma classification, secondary to prolonged automatic mechanical compression of the chest using the LUCAS device during an out-of-hospital cardiac arrest in a 32-yr-old patient.

Automatic mechanical CPR has been developed as an alternative to standard and manual CPR to improve blood flow to the heart and brain, generating systemic pressures and flow superior to those obtained with manual chest compression in porcine<sup>5,6</sup> and in human models.<sup>6</sup> Other theoretical advantages of automatic CPR include elimination of the rescuer fatigue factor and the need to stop CPR during rescuer changeovers and patient transfers,<sup>7</sup> as well as more reliable chest compression.<sup>8</sup> Device-assisted CPR can be either manual or automated. Manual device-assisted CPR, such as the CardioPump<sup>®</sup> or ResQPump<sup>®</sup> (Advanced Circulatory Systems Inc., Roseville, CA), is an active

compression–decompression CPR, using a manually operated suction cup with cushion pad, which requires the constant efforts of emergency personnel. However, automated device-assisted CPR performs autonomously the continuous chest compressions. The automated CPR devices are of two patterns: the one uses a piston at the end of an automated arm, such as LUCAS (fixed and standardized compression depth of 4 to 5 cm) or Thumper<sup>®</sup> (Michigan Instruments, Grand Rapids, MI; adjustable compression depth between 0 and 8 cm); the other uses a load-distributing band that encircles and constricts the chest, such as Autopulse<sup>®</sup> (Zoll Medical Corporation, Chelmsford, MA). Traumatic injuries have been reported due to the use of manual device-assisted CPR, mainly bone injuries (*i.e.*, sternal, rib, and spine fractures).<sup>9</sup> Conversely, a very limited number of studies described the injuries caused by the automated CPR devices. Vertebral fractures, skin abrasions, and visceral injuries (*i.e.*, liver, mesenteric, or splenic lacerations) were rarely documented after a management including Autopulse<sup>®</sup>.<sup>10</sup>

The LUCAS device provides also automatic mechanical compression and active decompression of 4 to 5 cm back to the neutral position of the chest with a compression force of 530 to 600 N at a frequency of 100/min.\*<sup>11</sup> Technically, the effectiveness of the LUCAS seems controversial. Ong *et al.*<sup>12</sup> demonstrated that the application of a mechanical CPR device in an emergency department is associated with a higher no-flow ratio than manual CPR in the first 5 min of resuscitation. A review of the literature<sup>13</sup> suggested that even if mechanical CPR could improve consistency and reduce interruptions in chest compressions, it may worsen the neurologic outcome. There is no evidence of improved survival.<sup>13,14</sup> Recent studies<sup>8,15</sup> recommended implementation of training cardiac arrest teams with a protocol to reduce the no-flow ratio in the first 10 min of resuscitation. In contrast to the technical aspects, the safety of LUCAS has not been clearly established.<sup>2</sup> Theoretically, distributing compressive force over the anterior chest might help to mitigate chest

\* LUCAS<sup>™</sup> Device instructions. Available at: [http://www.lucas-cpr.com/en/lucas\\_cpr/technical\\_info\\_and\\_instructions\\_for\\_use/lucas\\_v2\\_and\\_v1](http://www.lucas-cpr.com/en/lucas_cpr/technical_info_and_instructions_for_use/lucas_v2_and_v1). Accessed September 23, 2013.

wall trauma and injuries to the thoracoabdominal visceral organs. These injuries occur frequently during manual or mechanical CPR.<sup>8</sup> In an autopsy cohort,<sup>16</sup> mechanical chest compressions with the LUCAS device appear to be associated with the same variety and incidence of injuries as manual chest compressions, in particular sternal fractures (29 *vs.* 21%, not significant), rib fractures (47 *vs.* 32%, not significant), and mediastinal bleeding (11 *vs.* 19%, not significant) for the LUCAS device *versus* manual compressions.

In our case, pancreatic fracture could have been attributed to improper placement of the rescuer's hand on cardiac compression. But the initial CPR was begun by an experienced first-aider, a nurse who had received specific training. Despite the fact that the LUCAS device was modified with a stabilization strap to prevent it sliding in the caudal direction,<sup>14</sup> the pancreatic fracture seems to be the consequence of unexpected epigastric abdominal compression during automatic mechanical CPR of long duration. The maximal chest compression force is theoretically similar to manual CPR. Although a simulated manual chest compression study<sup>17</sup> evaluated the compressive force of 12 volunteer anesthetists at between 612 N and 644 N for each chest compression, it seems weaker in clinical practice. The mean distribution force during 91 out-of-hospital cardiac arrest resuscitated by paramedics is well below 431 N for a 38-mm compression.<sup>18</sup> This difference between the results of simulations and the clinical results can be explained by the paramedics' fear of inflicting trauma injuries during CPR.<sup>19</sup> Even if the paramedics are able to provide effective CPR for at least 5 continuous minutes,<sup>19</sup> an unintentional decrease in distribution force is observed. Moreover, because of variations in the stiffness of

human chests during CPR, the force required to achieve efficient chest compression decreases as the number of compressions performed increases.<sup>18</sup> The duration of CPR is already known to be a common risk factor of iatrogenic trauma.<sup>20</sup> Consequently, continuous and significant compressions with the LUCAS device, providing a force greater than 500 N for more than 30 min in our case, can generate high pressure related to an increased risk of injuries. This risk is amplified in patients with low chest stiffness, especially when the maximal compression force exceeds 450 N. In addition, it was well known that the compliance and suppleness of the human thorax under dynamic loading decrease as age and body mass index increase. Consequently, the young age (32 yr) and low body mass index (<25 kg/m<sup>2</sup>) of our patient were likely risk factors of high pressure and excessive compression force.<sup>21,22</sup> It seems probable that the extended duration of CPR and the high compressive force of the LUCAS device are implicated in the pancreatic fracture reported here (fig. 2), and really worsened the prognosis of our patient.

To our knowledge, this is the first report of a fatal complication related to automatic mechanical CPR. The long duration of CPR and a probably progressive movement of the LUCAS device may explain the traumatic pancreatic fracture (grade III in American Association for the Surgery of Trauma classification) related to direct abdominal compression. Even though the LUCAS device was conceived to assure a CPR both prolonged and effective, we have to keep in mind that its superiority over manual CPR is not proved in terms of survival or better neurologic outcome. We present this case because it illustrates really the risks incurred during of a prolonged mechanical CPR, especially if the automatic device is misused. So, prehospital teams using this device in the management of out-of-hospital cardiac arrest must be careful to avoid any adverse event, particularly potential traumatic impact. The initial location and repositioning after patient transfers must indeed be scrupulously controlled. Moreover, this case highlights that all unexplained hemodynamic instability—without obvious cardiac failure—during the days after return of spontaneous circulation may require a thoraco-abdominal tomodensitometry, to rule out an occult traumatic injury due to CPR. Future studies would be necessary to estimate the profit in front of risks of this device for the outcome of resuscitated patients.

### Acknowledgments

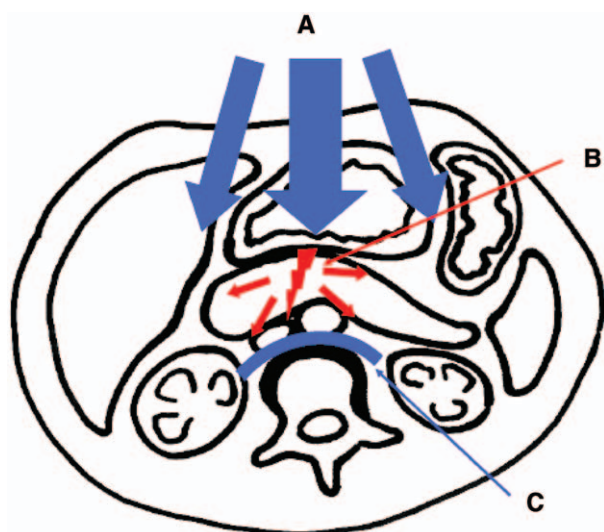
Support was provided solely from institutional and/or departmental sources.

### Competing Interests

The authors declare no competing interests.

### Correspondence

Address correspondence to Dr. Manzanera: Department of Anesthesiology and Critical Care Medicine, Lapeyronie University Hospital, Avenue du Doyen G Giraud, Montpellier, France. jonathan.



**Fig. 2.** Mechanism of pancreatic injury: distribution of antero-posterior compressive forces and their impact on the pancreas, above the vertebral body. (A) Compressions by the LUCAS device (Lund University Cardiopulmonary Assist System; Jolife AB, Lund, Sweden) of 530–600 N at a frequency of 100/min (administrated for >30 min in current case); (B) pancreatic injury; (C) vertebral body.

manzanera@gmail.com. Information on purchasing reprints may be found at [www.anesthesiology.org](http://www.anesthesiology.org) or on the masthead page at the beginning of this issue. ANESTHESIOLOGY's articles are made freely accessible to all readers, for personal use only, 6 months from the cover date of the issue.

## References

1. Rea TD, Pearce RM, Raghunathan TE, Lemaitre RN, Sotoodehnia N, Jouven X, Siscovick DS: Incidence of out-of-hospital cardiac arrest. *Am J Cardiol* 2004; 93:1455–60
2. Recommandations Formalisées d'Experts. Prise en charge de l'arrêt cardiaque. *Ann Fr Anesth Réanim* 2007; 26:1008–19
3. Nichol G, Thomas E, Callaway CW, Hedges J, Powell JL, Aufderheide TP, Rea T, Lowe R, Brown T, Dreyer J, Davis D, Idris A, Stiell I; Resuscitation Outcomes Consortium Investigators: Regional variation in out-of-hospital cardiac arrest incidence and outcome. *JAMA* 2008; 300:1423–31
4. Waldman PJ, Walters BL, Grunau CF: Pancreatic injury associated with interposed abdominal compressions in pediatric cardiopulmonary resuscitation. *Am J Emerg Med* 1984; 2:510–2
5. Ikeno F, Kaneda H, Hongo Y, Sakanoue Y, Nolasco C, Emami S, Lyons J, Rezaee M: Augmentation of tissue perfusion by a novel compression device increases neurologically intact survival in a porcine model of prolonged cardiac arrest. *Resuscitation* 2006; 68:109–18
6. Timerman S, Cardoso LF, Ramires JA, Halperin H: Improved hemodynamic performance with a novel chest compression device during treatment of in-hospital cardiac arrest. *Resuscitation* 2004; 61:273–80
7. Steen S, Sjöberg T, Olsson P, Young M: Treatment of out-of-hospital cardiac arrest with LUCAS, a new device for automatic mechanical compression and active decompression resuscitation. *Resuscitation* 2005; 67:25–30
8. Ong ME, Quah JL, Annathurai A, Noor NM, Koh ZX, Tan KB, Pothiwala S, Poh AH, Loy CK, Fook-Chong S: Improving the quality of cardiopulmonary resuscitation by training dedicated cardiac arrest teams incorporating a mechanical load-distributing device at the emergency department. *Resuscitation* 2013; 84:508–14
9. Hoke RS, Chamberlain D: Skeletal chest injuries secondary to cardiopulmonary resuscitation. *Resuscitation* 2004; 63:327–38
10. Pinto DC, Haden-Pinneri K, Love JC: Manual and automated cardiopulmonary resuscitation (CPR): A comparison of associated injury patterns. *J Forensic Sci* 2013; 58:904–9
11. Steen S, Liao Q, Pierre L, Paskevicius A, Sjöberg T: Evaluation of LUCAS, a new device for automatic mechanical compression and active decompression resuscitation. *Resuscitation* 2002; 55:285–99
12. Ong ME, Annathurai A, Shahidah A, Leong BS, Ong VY, Tiah L, Ang SH, Yong KL, Sultana P: Cardiopulmonary resuscitation interruptions with use of a load-distributing band device during emergency department cardiac arrest. *Ann Emerg Med* 2010; 56:233–41
13. Ong ME, Mackey KE, Zhang ZC, Tanaka H, Ma MH, Swor R, Shin SD: Mechanical CPR devices compared to manual CPR during out-of-hospital cardiac arrest and ambulance transport: A systematic review. *Scand J Trauma Resusc Emerg Med* 2012; 18:20–39
14. Smekal D, Johansson J, Huzevka T, Rubertsson S: A pilot study of mechanical chest compressions with the LUCAS™ device in cardiopulmonary resuscitation. *Resuscitation* 2011; 82:702–6
15. Yost D, Phillips RH, Gonzales L, Lick CJ, Satterlee P, Levy M, Barger J, Dodson P, Poggi S, Wojcik K, Niskanen RA, Chapman FW: Assessment of CPR interruptions from trans-thoracic impedance during use of the LUCAS™ mechanical chest compression system. *Resuscitation* 2012; 83:961–5
16. Smekal D, Johansson J, Huzevka T, Rubertsson S: No difference in autopsy detected injuries in cardiac arrest patients treated with manual chest compressions compared with mechanical compressions with the LUCAS device—A pilot study. *Resuscitation* 2009; 80:1104–7
17. Baubin M, Kollmitzer J, Pomaroli A, Kraincuk P, Kranzl A, Sumann G, Wiesinger GF, Gilly H: Force distribution across the heel of the hand during simulated manual chest compression. *Resuscitation* 1997; 35:259–63
18. Tomlinson AE, Nysaether J, Kramer-Johansen J, Steen PA, Dorph E: Compression force-depth relationship during out-of-hospital cardiopulmonary resuscitation. *Resuscitation* 2007; 72:364–70
19. Ødegaard S, Kramer-Johansen J, Bromley A, Myklebust H, Nysaether J, Wik L, Steen PA: Chest compressions by ambulance personnel on chests with variable stiffness: Abilities and attitudes. *Resuscitation* 2007; 74:127–34
20. Krischer JP, Fine EG, Davis JH, Nagel EL: Complications of cardiac resuscitation. *Chest* 1987; 92:287–91
21. Kent R, Lee SH, Darvish K, Wang S, Poster CS, Lange AW, Brede C, Lange D, Matsuoka F: Structural and material changes in the aging thorax and their role in crash protection for older occupants. *Stapp Car Crash J* 2005; 49:231–49
22. Poulard D, Bermond F, Compigne S, Bruyère K: *In-vivo* analysis of thoracic mechanical response under belt loading: The role of body mass index in thorax stiffness. *J Biomech* 2013; 46:883–9