

Jerrold H. Levy, M.D., F.A.H.A., F.C.C.M., Editor

Pulmonary Thromboendarterectomy for Chronic Thromboembolic Pulmonary Hypertension

Vikram Shenoy, M.D., James M. Anton, M.D., Charles D. Collard, M.D., Sloan C. Youngblood, M.D.

CHRONIC thromboembolic pulmonary disease is an important cause of severe pulmonary hypertension and is associated with significant morbidity and mortality. At 2-yr follow-up, 3.8% of survivors of an acute pulmonary embolic event develop chronic thromboembolic pulmonary hypertension (CTEPH) defined as a persistent mean pulmonary arterial pressure greater than 25 mmHg for 6 months after the inciting event.^{1,2}

Chronic thromboembolic pulmonary hypertension is progressive in nature and carries a poor prognosis due to the limited efficacy of medical therapy. Surgical intervention by pulmonary thromboendarterectomy (PTE) or lung transplantation is the only effective cure.¹ However, because the mortality rate of untreated CTEPH approaches 90% after 3 yr, the scarcity of available organs limits the viability of transplantation as a therapeutic option.³ Therefore, PTE has become the therapy of choice for patients with CTEPH, and a thorough understanding of the procedure and the medical management of these patients is necessary. We now review the anesthetic management and perioperative outcomes of the patients undergoing PTE.

CTEPH Pathophysiology

The initiating event for CTEPH is an acute pulmonary embolism followed by residual pulmonary arterial hypertension greater in magnitude than that seen during the acute phase. Risk factors include multiple embolic events, various inflammatory diseases, chronic indwelling vascular devices, and splenectomy (table 1).⁴ Each of these shares features of chronic inflammation and increased propensity for thrombus formation.

After an acute pulmonary embolic event, CTEPH occurs as a consequence of numerous secondary events

within the pulmonary vasculature. Unresolved emboli along with thrombus organization and fibrosis lead to pulmonary vascular obstruction and increase in pulmonary arterial pressures (fig. 1).⁵ Although the pulmonary vasculature typically expresses large quantities of plasmin, fibrinolysis may be abnormal in patients who develop CTEPH and may contribute to incomplete recanalization of affected pulmonary arteries.⁶

Persistent pulmonary hypertension causes medial hypertrophy and intimal hyperplasia leading to narrowing of the vascular lumen, further increasing vascular resistance. Microvascular thrombosis occurs at sites of chronic intimal disruption. Prostacyclin metabolic pathways are disrupted in patients with pulmonary arterial hypertension resulting in pulmonary vasoconstriction, hypercoagulability, and smooth muscle hypertrophy.⁷ Meanwhile, increased endothelin-1 expression causes intense pulmonary vasoconstriction and potentiation of vascular remodeling.^{8,9}

Moser *et al.*¹⁰ demonstrated that the microvascular changes associated with CTEPH are indistinguishable from those of idiopathic pulmonary arterial hypertension and may occur in pulmonary vascular domains not affected by the inciting embolus. Counterintuitively, vasculature distal to the inciting embolus often remains unaffected while “normal” vasculature demonstrates evidence of remodeling. This paradox likely occurs because those pulmonary vessels unaffected by the initial thrombus are exposed to increased pulmonary arterial pressures thus inciting the microvascular alterations characteristic of the disease. Because these changes occur throughout the lungs, increased pulmonary arterial pressures in CTEPH are often greater in magnitude than that observed during the initial embolic event.

This article is featured in “This Month in Anesthesiology,” page 1A. Figures 1 and 2 were prepared by Annemarie B. Johnson, C.M.I., Medical Illustrator, Vivo Visuals, Winston-Salem, North Carolina.

Submitted for production May 10, 2013. Accepted for publication October 17, 2013. From the Department of Anesthesiology, Division of Cardiovascular Anesthesiology, Texas Heart Institute, St. Luke’s Hospital, Houston, Texas (V.S., J.M.A., C.D.C.); and the Department of Anesthesiology, University of Mississippi Medical Center, Jackson, Mississippi (S.C.Y.).

Copyright © 2014, the American Society of Anesthesiologists, Inc. Lippincott Williams & Wilkins. Anesthesiology 2014; 120:1255–61

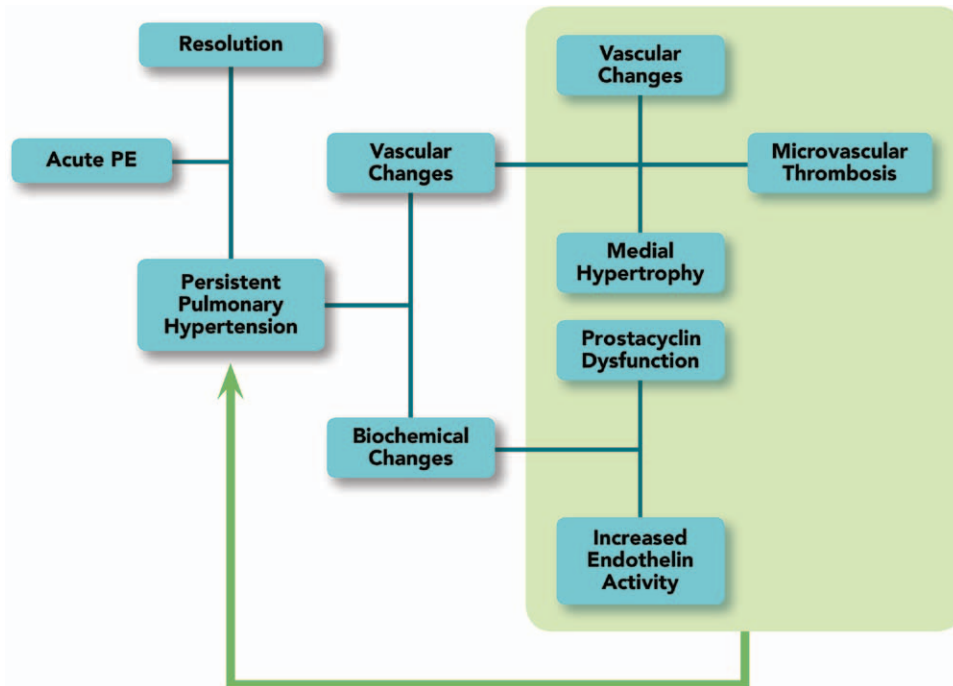


Fig. 1. Progression from acute pulmonary embolism (PE) to development of chronic thromboembolic pulmonary hypertension.

Evaluation of CTEPH

Patients with CTEPH may present with symptoms of exercise intolerance, fatigue, and dyspnea. Physical examination often reveals signs of right heart failure including jugular venous distention, hepatomegaly, ascites, and peripheral edema.¹ Bruits may be appreciated on auscultation of the peripheral lung fields.

After a diagnosis of CTEPH is made, the primary goal of further evaluation is determination of surgical accessibility. This incorporates both angiographic data and the individual surgeon's proficiency with the procedure. Pulmonary angiography, the definitive standard for the diagnosis of CTEPH, along with right heart catheterization allows characterization of the disease process, evaluation of cardiac function, and assessment of surgical risk based on assessment of pulmonary vascular resistance (PVR).^{11–13} Characteristic angiographic findings include vascular webs, intimal irregularities, abrupt narrowing of vessels, and proximal obstruction of pulmonary arteries.¹⁴ Anomalies detected on angiography provide clues regarding the extent of disease and surgical accessibility. Patients with predominantly small-vessel disease on angiography or with significant comorbidities are typically considered inoperable.

Although echocardiography is sensitive for the diagnosis of pulmonary hypertension and right ventricular dysfunction, specificity for CTEPH is lacking. Transthoracic echocardiography can reveal abnormal right heart function and structure and can be used to quantify pulmonary arterial pressures using the tricuspid regurgitant jet.¹⁵ In the event a pulmonary arterial thrombus is identified, echocardiography

cannot accurately differentiate acute from chronic pulmonary embolism, though presence of right ventricular hypertrophy is suggestive of chronic disease. Echocardiography also allows assessment of left ventricular function and evaluation for the presence of intracardiac shunts.

Electrocardiogram may reveal right axis deviation, right ventricular hypertrophy, and a right bundle-branch block. Chest radiography may be normal; however, more advanced disease often yields dilation of central pulmonary arteries and enlargement of the right heart.¹⁶ Pulmonary function testing can be used to exclude other underlying pulmonary pathology. Severe reductions in carbon monoxide-diffusing capacity suggest that the pulmonary capillary bed is severely compromised and an alternate diagnosis should be considered as CTEPH affects the precapillary pulmonary vasculature.¹⁶

Radioisotope ventilation–perfusion scans along with computed tomography may aid in the diagnosis and determine suitability of the disease for surgical correction. Compared with computed tomography, ventilation–perfusion scans have a higher sensitivity but lower specificity for detecting CTEPH (96 vs. 51% and 90 to 95 vs. 99%, respectively).¹⁷ Magnetic resonance imaging may also be used, but the incremental benefit of applying this technology remains in question and requires further investigation.¹⁸

CTEPH Medical Management

Medical management of pulmonary hypertension is often instituted before surgery. However, crucial to the management of patients with CTEPH is an understanding that

surgical correction is the only potentially curative intervention. The use of medical therapy as a bridge-to-surgery is unproven and should not delay surgical intervention.¹⁹

Four groups of patients have been described as candidates for medical treatment.^{3,20} These include patients with systemic disease processes who limit their candidacy for PTE, those with surgically inaccessible disease, and those with residual pulmonary hypertension after PTE. More relevant to the anesthesiologist is another subset of patients with surgically accessible disease and severe pulmonary hypertension defined as PVR greater than $1,000 \text{ dyne s}^{-1} \text{ cm}^{-5}$ and mean pulmonary arterial pressure greater than 50 mmHg. Medical therapy functions to stabilize this patient population until surgery can be performed; therefore, an understanding of the various medical therapies available is mandatory.

Traditionally, CTEPH medical therapy has focused on preventing thromboembolic recurrence and minimizing pulmonary vasoconstriction. Lifelong anticoagulation with warfarin titrated to a goal international normalized ratio of 2.0 to 3.0 is common.²¹ Dihydropyridine calcium-channel blockers such as amlodipine and nifedipine are commonly administered for their pulmonary vasodilator properties, and diuretics including furosemide and hydrochlorothiazide are often used to minimize volume overload.⁸

Several therapies have been introduced for the treatment of idiopathic pulmonary arterial hypertension including prostacyclin analogs, endothelin-receptor antagonists, and phosphodiesterase inhibitors (fig. 2).^{8,22} Because of some similarities in pathophysiology, a discussion of these agents is warranted because they may also find use in the treatment of CTEPH.⁸

Bosentan, an endothelin-receptor antagonist, has been evaluated as a means of reducing PVR and possibly inhibiting vascular remodeling. The “Bosentan Effects in iNoperable Forms of chronic Thromboembolic pulmonary hypertension” trial evaluated the safety and efficacy of bosentan as a target medical therapy.²³ In 157 patients with either

persistent pulmonary hypertension after PTE or inoperable disease, a statistically significant decrease in PVR and improved cardiac index occurred during 16 weeks of observation. However, no improvement was observed in quality of life measures or exercise tolerance. The authors hypothesized that this discrepancy is due to a lag between improvement in hemodynamics and symptomatic improvement. In addition, 14.5% of patients receiving bosentan developed a three-fold increase in alanine and aspartate aminotransferase levels. At this time, the utility of bosentan remains in question for patients with operable disease, but the use of bosentan for refractory pulmonary hypertension after PTE and inoperable CTEPH is promising.

Prostacyclin analogs such as epoprostenol, treprostinil, and iloprost induce vasodilation and inhibit both platelet activation and vascular proliferation, thus targeting several pathophysiologic mechanisms of CTEPH. Intravenous,⁷ subcutaneous,²⁴ oral,²⁵ and inhalation²⁶ administrations have all demonstrated the ability to increase functional capacity, improve World Health Organization Classification, decrease brain natriuretic peptide levels, increase cardiac output, and decrease PVR. Inhalational administration of prostacyclin analogs is associated with rapid (<5 min) reduction of PVR and maintenance of systemic blood pressure and is an attractive method for intraoperative administration.²⁶ A preliminary, open-label study of the effect of preprocedural infusion of prostacyclin demonstrated a reduction of PVR and improved cardiac output in high-risk patients (PVR > $1,200 \text{ dyne s}^{-1} \text{ cm}^{-5}$) before CTEPH, but this therapeutic strategy has yet to be proven in randomized, controlled trials.⁷ Because prostanoid discontinuation is associated with rebound hypertension, oral therapy is often continued until the day of surgery and infusion therapy is continued through induction and weaned before instituting cardiopulmonary bypass.

The phosphodiesterase type 5 inhibitors sildenafil and tadalafil stabilize cyclic guanosine monophosphate levels,

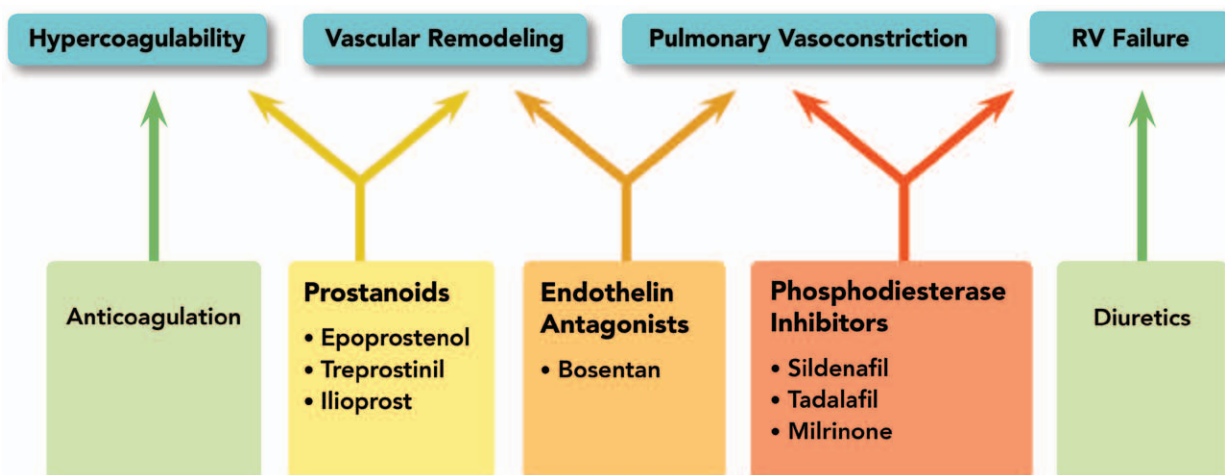


Fig. 2. Medical management of chronic thromboembolic pulmonary hypertension. Several agents affect disease progression by inhibiting multiple pathophysiologic elements of the disease. RV = right ventricle.

thereby augmenting nitric oxide–mediated pulmonary vasodilation and ventricular ionotropy. These agents have been shown to reduce PVR, increase cardiac output, improve right ventricular function, and improve exercise tolerance among patients with chronic pulmonary hypertension including patients with CTEPH.^{27,28} Their use is generally continued into the perioperative period.

Anesthetic Management

Patients with CTEPH typically present for surgery after extensive medical evaluation and therapy. A thorough review of existing records is necessary with an emphasis on previous catheterization data to evaluate cardiac output, pulmonary arterial pressures, PVR, and right ventricular performance. Preoperatively increased right ventricular end-diastolic pressures (>14 mmHg), severe tricuspid regurgitation, and PVR greater than 1,000 dyne $s^{-1} cm^{-5}$ are signs of imminent cardiovascular collapse, and in such instances, institution of inotropic support may be considered before induction.²⁹

Sedative-induced respiratory depression may critically increase PVR and is best avoided. A combination of benzodiazepines, opioids, and etomidate is a common selection though many other induction agents may be successfully used. In the setting of right ventricular hypertrophy, perfusion of the right ventricle is limited to diastole and dependent on diastolic blood pressure similar to left ventricular coronary perfusion. Adequate systemic vascular resistance is therefore necessary to maintain coronary blood flow to the right ventricle and can be maintained by various catecholamine derivatives or vasopressin if necessary. PVR is relatively fixed in CTEPH, and vasodilators used in the hope of reducing PVR may not augment right ventricular function.

Pulmonary arterial catheterization is generally performed after anesthetic induction and is valuable both for hemodynamic management and assessing the response to PTE. Transesophageal echocardiogram may reveal the presence of right atrial, right ventricular, or pulmonary arterial thrombus and allows monitoring of both right and left ventricular function. Color-flow Doppler and agitated saline should also be used to detect intracardiac shunts that may affect surgical management.

Surgical Management

Median sternotomy is performed and cardiopulmonary bypass is established by means of ascending aortic and bicaval cannulation. Pulmonary arterial and venous vents are placed. Intermittent circulatory arrest is essential to obtain a bloodless field due to the significant amount of collateral and bronchial blood flow present in these patients.

Typically, the right arteriotomy is performed first. The endarterectomy plane is identified and dissection proceeds. Circulatory arrest is initiated when blood obscures the surgical field and usually does not exceed 20 min. On completion of the right pulmonary endarterectomy, bypass is resumed

and the arteriotomy is closed. Left-sided endarterectomy is performed in a similar manner with circulatory arrest initiated when necessary.

Limited evidence exists regarding the appropriate management of patients immediately before circulatory arrest. In our institution, hypothermia in addition to phenobarbital 10 mg/kg IV, lidocaine 1 mg/kg IV, and magnesium sulfate 2 mg IV is administered for myocardial protection and cerebral quiescence. Cerebral oximetry is used for monitoring oxygenation of the ischemic brain. Thomson *et al.*³⁰ reported the successful use of antegrade cerebral perfusion to avoid total circulatory arrest during PTE though 9% of patients in their series required conversion to complete arrest. There is limited evidence demonstrating the superiority of alternative techniques over the traditional technique of using cardiopulmonary bypass and deep hypothermic circulatory arrest.³¹

A patent foramen ovale is present in up to 25% of the general population and may contribute to hypoxemia in the setting of increased right atrial pressures.³² Conversely, right-to-left interatrial shunting may improve left ventricular filling and systemic cardiac output in the setting of right ventricular dysfunction.³³ If detected on echocardiography, repair of a patent foramen ovale should be individualized based on the patient's hemodynamic status and oxygenation.

Postoperative Management

Successful PTE results in an immediate decrease in right ventricular afterload. Cardiac output is generally dependent on optimization of right ventricular function. Maintaining appropriate right ventricular preload, sinus rhythm and heart rate are important to achieve optimization of right ventricular function.³⁴ Pericardial effusion and tamponade are common complications and can be prevented by creating a posterior pericardial window or by placing a posterior pericardial drain. On removal of drains and pacemaker wires, anticoagulation with warfarin is started.

Most patients experience some degree of reperfusion injury ranging in severity from mild to life threatening. Onset is typically within 24 to 72 h of surgery, though reperfusion injury can occur immediately after cessation of cardiopulmonary bypass. Mild reperfusion injury typically results in pulmonary edema and postoperative hypoxemia for which supportive care typically allows resolution while severe reperfusion injury presents as profound alveolar hemorrhage with persistently increased pulmonary artery pressure. The use of inhaled nitric oxide to improve oxygenation and gas exchange has been described, but subsequent clinical trials have not demonstrated significant benefit.³⁴ In addition, long-term use of nitric oxide may lead to rebound pulmonary hypertension. Inhaled and intravenous prostacyclin analogues have been reported in case series as a successful, short-term treatment option, but evidence is limited and long-term efficacy has not been demonstrated.³⁵ Extracorporeal membrane oxygenation may be used for hemodynamic or respiratory support in

Table 1. Risk Factors for CTEPH Development

Principle
Multiple pulmonary embolic events
Younger age
Idiopathic pulmonary embolism
Associated medical conditions
Chronic inflammatory states
Ventriculoatrial shunts
Malignancy
Indwelling central venous catheters
Splenectomy
Recurrent episodes of venous thromboembolism
Thyroid hormone replacement therapy
Thrombotic factors
Lupus anticoagulant
Antiphospholipid antibodies
Increased levels of factor VIII
Dysfibrinogenemia
Genetic factors
ABO blood groups other than O
HLA polymorphisms
Abnormal endogenous fibrinolysis

CTEPH = chronic thromboembolic pulmonary hypertension; HLA = human leukocyte antigen.

severe cases. Current management strategies include diuretic administration, avoidance of inotropes and vasodilators, and lung-protective ventilatory strategies including the early use of positive end-expiratory pressure.³⁴

Pulmonary arterial steal occurs as blood flow from previously perfused alveoli is shunted to the newly perfused areas of the lung. Severe hypoxemia develops when these lung segments are not yet contributing to oxygenation. This phenomenon decreases over time, suggesting that remodeling of the pulmonary vasculature and improved ventilation–perfusion matching occurs.³⁴ Studies using inhaled nitric oxide and iloprost have produced moderate improvements in oxygenation, and inhaled nitric oxide has been successfully used in the treatment of right ventricular dysfunction attributed to pulmonary hypertension in a variety of postoperative settings.^{36,37} However, no proven benefit on long-term outcome has been demonstrated in this patient population.

PTE Outcomes

Postoperative mortality strongly correlates with the degree of residual PVR. Individuals with a postoperative PVR greater than 500 dynes $s^{-1} cm^{-5}$ have a mortality of 30.6%, whereas patients below this threshold have a mortality of 0.9%.¹¹ The Jamieson classification (table 2) divides CTEPH based upon *intraoperative* observation of thrombus location and evolution of vascular changes.³⁸ Four categories exist that are useful for describing both disease progression and prognosis. Type IV patients have 1-month mortality rates approaching 15%, and surgery has the least effect on their PVR.

Significant improvement has been made in the surgical management of CTEPH over the last 4 decades. From 1970

Table 2. Jamieson Classification

Classification	Description	One-month Survival (%)
Type I	Fresh thrombus in main lobar pulmonary arteries.	98.7
Type II	No major vessel thrombus is present. Intimal thickening and fibrosis proximal to segmental arteries.	97.5
Type III	Fibrosis, intimal webbing, and thickening with or without thrombus in distal segmental arteries.	86.8
Type IV	Inoperable, microscopic distal arteriolar disease without visible thrombus.	85.7

to 1990, operative mortality after PTE was 17%.¹¹ A more recent review of an international registry from 2007 to 2009 showed an in-hospital mortality of 4.7% after PTE.³⁹ One series of 157 patients demonstrated a 4-yr cumulative survival of 84%.⁴⁰ This same series reported significant improvements in New York Heart Association class, hemodynamics, and Pao_2 in the first 3 postoperative months which persisted throughout the follow-up period. Up to 35% of patients with PTE will experience some degree of persistent pulmonary hypertension likely due to distal disease not accessible during surgery. These patients typically demonstrate worse preoperative hemodynamics compared with that in patients undergoing successful PTE.²⁰

Conclusion

In summary, PTE is currently the most viable treatment option for surgically accessible CTEPH. Though medical therapy is limited, these patients often present on multiple medications that must be considered for successful perioperative management. Because of the relative infrequency and complexity of PTE, successful surgery is dependent on multidisciplinary management including medical, surgical, and anesthetic consultation.

Acknowledgments

Support was provided solely from institutional and/or departmental sources.

Competing Interests

The authors declare no competing interests.

Correspondence

Address correspondence to Dr. Shenoy: Department of Anesthesiology, Metrowest Anesthesia Care, 921 Gessner Rd., Suite 226, Houston, Texas 77024. shenoyvikram@yahoo.com. Information on purchasing reprints may be found at www.anesthesiology.org or on the masthead page at the beginning of this issue. ANESTHESIOLOGY's articles are made freely accessible to all readers, for personal use only, 6 months from the cover date of the issue.

References

- Piazza G, Goldhaber SZ: Chronic thromboembolic pulmonary hypertension. *N Engl J Med* 2011; 364:351–60
- Pengo V, Lensing AW, Prins MH, Marchiori A, Davidson BL, Tiozzo F, Albanese P, Biasiolo A, Pegoraro C, Illiceto S, Prandoni P; Thromboembolic Pulmonary Hypertension Study Group: Incidence of chronic thromboembolic pulmonary hypertension after pulmonary embolism. *N Engl J Med* 2004; 350:2257–64
- Lewczuk J, Piszko P, Jagas J, Porada A, Wójciak S, Sobkowicz B, Wrabec K: Prognostic factors in medically treated patients with chronic pulmonary embolism. *Chest* 2001; 119:818–23
- Bonderman D, Wilkens H, Wakounig S, Schäfers HJ, Jansa P, Lindner J, Simkova I, Martischinig AM, Dudczak J, Sadushi R, Skoro-Sajer N, Klepetko W, Lang IM: Risk factors for chronic thromboembolic pulmonary hypertension. *Eur Respir J* 2009; 33:325–31
- Auger WR, Kim NH, Trow TK: Chronic thromboembolic pulmonary hypertension. *Clin Chest Med* 2010; 31:741–58
- Morris TA, Marsh JJ, Chiles PG, Auger WR, Fedullo PF, Woods VL Jr: Fibrin derived from patients with chronic thromboembolic pulmonary hypertension is resistant to lysis. *Am J Respir Crit Care Med* 2006; 173:1270–5
- Nagaya N, Sasaki N, Ando M, Ogino H, Sakamaki F, Kyotani S, Nakanishi N: Prostacyclin therapy before pulmonary thromboendarterectomy in patients with chronic thromboembolic pulmonary hypertension. *Chest* 2003; 123:338–43
- Bresser P, Pepke-Zaba J, Jaïs X, Humbert M, Hoepfer MM: Medical therapies for chronic thromboembolic pulmonary hypertension: An evolving treatment paradigm. *Proc Am Thorac Soc* 2006; 3:594–600
- Reesink HJ, Meijer RC, Lutter R, Boomsma F, Jansen HM, Kloek JJ, Bresser P: Hemodynamic and clinical correlates of endothelin-1 in chronic thromboembolic pulmonary hypertension. *Circ J* 2006; 70:1058–63
- Moser KM, Bloor CM: Pulmonary vascular lesions occurring in patients with chronic major vessel thromboembolic pulmonary hypertension. *Chest* 1993; 103:685–92
- Jamieson SW, Kapelanski DP, Sakakibara N, Manecke GR, Thistlethwaite PA, Kerr KM, Channick RN, Fedullo PF, Auger WR: Pulmonary endarterectomy: Experience and lessons learned in 1,500 cases. *Ann Thorac Surg* 2003; 76:1457–62; discussion 1462–4
- Hartz RS, Byrne JG, Levitsky S, Park J, Rich S: Predictors of mortality in pulmonary thromboendarterectomy. *Ann Thorac Surg* 1996; 62:1255–9; discussion 1259–60
- Hoepfer MM, Lee SH, Voswinckel R, Palazzini M, Jaïs X, Marinelli A, Barst RJ, Ghofrani HA, Jing ZC, Opitz C, Seyfarth HJ, Halank M, McLaughlin V, Oudiz RJ, Ewert R, Wilkens H, Kluge S, Bremer HC, Baroke E, Rubin LJ: Complications of right heart catheterization procedures in patients with pulmonary hypertension in experienced centers. *J Am Coll Cardiol* 2006; 48:2546–52
- Auger WR, Fedullo PF, Moser KM, Buchbinder M, Peterson KL: Chronic major-vessel thromboembolic pulmonary artery obstruction: Appearance at angiography. *Radiology* 1992; 182:393–8
- Menzel T, Wagner S, Kramm T, Mohr-Kahaly S, Mayer E, Braeuninger S, Meyer J: Pathophysiology of impaired right and left ventricular function in chronic embolic pulmonary hypertension: Changes after pulmonary thromboendarterectomy. *Chest* 2000; 118:897–903
- Auger WR, Kerr KM, Kim NH, Fedullo PF: Evaluation of patients with chronic thromboembolic pulmonary hypertension for pulmonary endarterectomy. *Pulm Circ* 2012; 2:155–62
- Tunari N, Gibbs SJ, Win Z, Gin-Sing W, Graham A, Gishen P, Al-Nahhas A: Ventilation-perfusion scintigraphy is more sensitive than multidetector CTPA in detecting chronic thromboembolic pulmonary disease as a treatable cause of pulmonary hypertension. *J Nucl Med* 2007; 48:680–4
- Bradlow WM, Gibbs JS, Mohiaddin RH: Cardiovascular magnetic resonance in pulmonary hypertension. *J Cardiovasc Magn Reson* 2012; 14:6
- Jensen KW, Kerr KM, Fedullo PF, Kim NH, Test VJ, Ben-Yehuda O, Auger WR: Pulmonary hypertensive medical therapy in chronic thromboembolic pulmonary hypertension before pulmonary thromboendarterectomy. *Circulation* 2009; 120:1248–54
- Condliffe R, Kiely DG, Gibbs JS, Corris PA, Peacock AJ, Jenkins DP, Hodgkins D, Goldsmith K, Hughes RJ, Sheares K, Tsui SS, Armstrong IJ, Torpy C, Craddock R, Carlin CM, Das C, Coghlan JG, Pepke-Zaba J: Improved outcomes in medically and surgically treated chronic thromboembolic pulmonary hypertension. *Am J Respir Crit Care Med* 2008; 177:1122–7
- Wilkens H, Lang I, Behr J, Berghaus T, Grohe C, Guth S, Hoepfer MM, Kramm T, Krüger U, Langer F, Rosenkranz S, Schäfers HJ, Schmidt M, Seyfarth HJ, Wahlers T, Worth H, Mayer E: Chronic thromboembolic pulmonary hypertension (CTEPH): Updated Recommendations of the Cologne Consensus Conference 2011. *Int J Cardiol* 2011; 154(suppl 1):S54–60
- Smith I, Jackson I: Beta-blockers, calcium channel blockers, angiotensin converting enzyme inhibitors and angiotensin receptor blockers: Should they be stopped or not before ambulatory anaesthesia? *Curr Opin Anaesthesiol* 2010; 23:687–90
- Jaïs X, D'Armini AM, Jansa P, Torbicki A, Delcroix M, Ghofrani HA, Hoepfer MM, Lang IM, Mayer E, Pepke-Zaba J, Perchenet L, Morganti A, Simonneau G, Rubin LJ; Bosentan Effects in inoperable Forms of chronic Thromboembolic pulmonary hypertension Study Group: Bosentan for treatment of inoperable chronic thromboembolic pulmonary hypertension: BENEFIT (Bosentan Effects in inoperable Forms of chronic Thromboembolic pulmonary hypertension), a randomized, placebo-controlled trial. *J Am Coll Cardiol* 2008; 52:2127–34
- Skoro-Sajer N, Bonderman D, Wiesbauer F, Harja E, Jakowitsch J, Klepetko W, Kneussl MP, Lang IM: Treprostinil for severe inoperable chronic thromboembolic pulmonary hypertension. *J Thromb Haemost* 2007; 5:483–9
- Vizza CD, Badagliacca R, Sciomer S, Poscia R, Battagliese A, Schina M, Agati L, Fedele F: Mid-term efficacy of beraprost, an oral prostacyclin analog, in the treatment of distal CTEPH: A case control study. *Cardiology* 2006; 106:168–73
- Voswinckel R, Enke B, Reichenberger F, Kohstall M, Kreckel A, Krick S, Gall H, Gessler T, Schmehl T, Ghofrani HA, Schermuly RT, Grimminger F, Rubin LJ, Seeger W, Olschewski H: Favorable effects of inhaled treprostinil in severe pulmonary hypertension: Results from randomized controlled pilot studies. *J Am Coll Cardiol* 2006; 48:1672–81
- Reichenberger F, Voswinckel R, Enke B, Rutsch M, El Fechtali E, Schmehl T, Olschewski H, Schermuly R, Weissmann N, Ghofrani HA, Grimminger F, Mayer E, Seeger W: Long-term treatment with sildenafil in chronic thromboembolic pulmonary hypertension. *Eur Respir J* 2007; 30:922–7
- Galiè N, Brundage BH, Ghofrani HA, Oudiz RJ, Simonneau G, Safdar Z, Shapiro S, White RJ, Chan M, Beardsworth A, Frumkin L, Barst RJ; Pulmonary Arterial Hypertension and Response to Tadalafil (PHIRST) Study Group: Tadalafil therapy for pulmonary arterial hypertension. *Circulation* 2009; 119:2894–903
- Manecke GR Jr: Anesthesia for pulmonary endarterectomy. *Semin Thorac Cardiovasc Surg* 2006; 18:236–42
- Thomson B, Tsui SS, Dunning J, Goodwin A, Vuylsteke A, Latimer R, Pepke-Zaba J, Jenkins DP: Pulmonary endarterectomy is possible and effective without the use of complete circulatory arrest—The UK experience in over 150 patients. *Eur J Cardiothorac Surg* 2008; 33:157–63

31. Madani MM, Auger WR, Pretorius V, Sakakibara N, Kerr KM, Kim NH, Fedullo PF, Jamieson SW: Pulmonary endarterectomy: Recent changes in a single institution's experience of more than 2,700 patients. *Ann Thorac Surg* 2012; 94:97–103; discussion 103
32. Meissner I, Khandheria BK, Heit JA, Petty GW, Sheps SG, Schwartz GL, Whisnant JP, Wiebers DO, Covalt JL, Petterson TM, Christianson TJ, Agmon Y: Patent foramen ovale: Innocent or guilty? Evidence from a prospective population-based study. *J Am Coll Cardiol* 2006; 47:440–5
33. Amsel BJ, Rodrigus I, De Paep R, De Raedt H, Moulijn AC: Right-to-left flow through a patent foramen ovale in acute right ventricular infarction. Two case reports and a proposal for management. *Chest* 1995; 108:1468–71
34. Adams A, Fedullo PF: Postoperative management of the patient undergoing pulmonary endarterectomy. *Semin Thorac Cardiovasc Surg* 2006; 18:250–6
35. Hsu HH, Chen JS, Chen YS, Ko WJ, Kuo SW, Lee YC: Short-term intravenous iloprost for treatment of reperfusion lung oedema after pulmonary thromboendarterectomy. *Thorax* 2007; 62:459–61
36. Kramm T, Eberle B, Krummenauer F, Guth S, Oelert H, Mayer E: Inhaled iloprost in patients with chronic thromboembolic pulmonary hypertension: Effects before and after pulmonary thromboendarterectomy. *Ann Thorac Surg* 2003; 76:711–8
37. Imanaka H, Miyano H, Takeuchi M, Kumon K, Ando M: Effects of nitric oxide inhalation after pulmonary thromboendarterectomy for chronic pulmonary thromboembolism. *Chest* 2000; 118:39–46
38. Thistlethwaite PA, Mo M, Madani MM, Deutsch R, Blanchard D, Kapelanski DP, Jamieson SW: Operative classification of thromboembolic disease determines outcome after pulmonary endarterectomy. *J Thorac Cardiovasc Surg* 2002; 124:1203–11
39. Pepke-Zaba J, Delcroix M, Lang I, Mayer E, Jansa P, Ambroz D, Treacy C, D'Armini AM, Morsolini M, Snijder R, Bresser P, Torbicki A, Kristensen B, Lewczuk J, Simkova I, Barberà JA, de Perrot M, Hoeper MM, Gaine S, Speich R, Gomez-Sanchez MA, Kovacs G, Hamid AM, Jaïs X, Simonneau G: Chronic thromboembolic pulmonary hypertension (CTEPH): Results from an international prospective registry. *Circulation* 2011; 124:1973–81
40. Corsico AG, D'Armini AM, Cerveri I, Klersy C, Ansaldo E, Niniano R, Gatto E, Monterosso C, Morsolini M, Nicolardi S, Tramontin C, Pozzi E, Viganò M: Long-term outcome after pulmonary endarterectomy. *Am J Respir Crit Care Med* 2008; 178:419–24