

# Bilateral Suprazygomatic Maxillary Nerve Block for Cleft Palate Repair in Children

## *A Prospective, Randomized, Double-blind Study versus Placebo*

Julien Chiono, M.D., Olivier Raux, M.D., Sophie Bringuier, Pharm.D., Ph.D., Chrystelle Sola, M.D., Michèle Bigorre, M.D., Xavier Capdevila, M.D., Ph.D., Christophe Dadure, M.D., Ph.D.

### ABSTRACT

**Background:** The authors investigated the efficacy of bilateral suprazygomatic maxillary nerve block (SMB) for postoperative pain relief in infants undergoing cleft palate repair.

**Methods:** In this prospective, double-blind, single-site, randomized, and parallel-arm controlled trial, 60 children were assigned to undergo bilateral SMB with general anesthesia with either 0.15 ml/kg of 0.2% ropivacaine (Ropi group) or 0.15 ml/kg of isotonic saline (Saline group) on each side. The primary endpoint was total postoperative morphine consumption at 48 h. Pain scores and respiratory- and SMB-related complications were noted.

**Results:** The overall dose of intravenous morphine after 48 h (mean [95% CI]) was lower in the Ropi group compared with that in the Saline group (104.3 [68.9 to 139.6] *vs.* 205.2 [130.7 to 279.7]  $\mu\text{g}/\text{kg}$ ;  $P = 0.033$ ). Continuous morphine infusion was less frequent in the Ropi group compared with that in the Saline group (1 patient [3.6%] *vs.* 9 patients [31%];  $P = 0.006$ ). Three patients in the Saline group had an episode of oxygen desaturation requiring oxygen therapy. There were no technical failures or immediate complications of the SMB. Intraoperative hemodynamic parameters, doses of sufentanil, pain scores, and postoperative hydroxyzine requirements were not different between the two groups.

**Conclusion:** Bilateral SMB is an easy regional anesthesia technique that reduces total morphine consumption at 48 h after cleft palate repair in children and the use of continuous infusion of morphine and may decrease postoperative respiratory complications. (**ANESTHESIOLOGY 2014; 120:1362-9**)

CLEFT palate (CP) is a common congenital malformation, with an incidence ranging from 0.1 to 1.1 per 1,000 births depending on the population group.<sup>1</sup> Early surgery is necessary to reduce phonation and feeding difficulties and reduce complications such as frequent sinusitis and other respiratory tract infections.<sup>2</sup> CP repair is painful, necessitating high doses of intravenous (IV) opioids.<sup>3,4</sup> Therefore, the risk of postoperative respiratory depression and airway obstruction is important, and continuous monitoring is required during the initial 24-h postoperative period.<sup>3</sup>

The maxillary nerve (MN) provides sensory innervation of the anterior and posterior palate, the upper dental arch, the maxillary sinus, and the posterior nasal cavity. One of its terminal branches, the infraorbital nerve, provides sensory innervation of the upper lip, lower eyelid, cheek, and nasal ala. In infants, infraorbital nerve block promotes effective analgesia for cleft lip surgery,<sup>5</sup> better than IV fentanyl,<sup>6</sup> placebo,<sup>7</sup> or surgical infiltration.<sup>8</sup> However, this technique does not provide effective analgesia in cases of associated CP repair because of its limited territory of innervation.<sup>5,7</sup> MN block through the infrazygomatic route, used for the treatment of trigeminal neuralgia in adults, permits anesthesia of the entire palatine territory.

#### What We Already Know about This Topic

- Cleft palate repair in children is a painful procedure. The optimal approach to postoperative analgesia has not been determined.

#### What This Article Tells Us That Is New

- The results of this randomized blinded study show that the suprazygomatic approach to maxillary nerve block substantially reduces morphine requirements during the first 48 h.
- By reducing opioid requirements, use of suprazygomatic maxillary nerve blocks may reduce the likelihood of oxygen desaturation from occurring.

However, this nerve block has led to complications such as orbital puncture, intracranial injection, maxillary artery puncture, or posterior pharyngeal wall injury.<sup>9,10</sup> In adults, approach to the suprazygomatic MN block (SMB) seems to minimize the risks of the infrazygomatic route,<sup>9,11</sup> providing effective anesthesia of the entire sensory territory of the MN and its terminal branches. Furthermore, a recent computed tomography scan study on infants<sup>12</sup> examined SMB with regard to patient comfort and postoperative analgesia after CP repair compared with IV opioids in a retrospective control group.<sup>13</sup>

This article is featured in "This Month in Anesthesiology," page 1A.

Submitted for publication May 31, 2013. Accepted for publication January 8, 2014. From the Department of Anesthesiology and Critical Care Medicine, University Montpellier I, and Lapeyronie University Hospital, Montpellier, France.

Copyright © 2014, the American Society of Anesthesiologists, Inc. Lippincott Williams & Wilkins. Anesthesiology 2014; 120:1362-9

The primary aim of this prospective, randomized, double-blind study was to evaluate the efficacy of bilateral SMB for postoperative pain relief in infants scheduled for CP repair. A decrease in total morphine consumption at 48 h is considered as the primary hypothesis. Respiratory- and SMB-related complications were investigated.

## Materials and Methods

In this single-site study, patients were enrolled prospectively after institutional ethical committee approval (CPP Sud Méditerranée IV, October 03, 2008, N° 080805, Montpellier, France), registration in the French Database for Clinical Trials (*EDRACT number: 2008-004179-24*), and written parental informed consent. All children younger than 5 yr of age scheduled for CP repair with general anesthesia (associated or not with cleft lip repair) in the pediatric surgery ward of Montpellier University Hospital, Montpellier, France, were screened during preanesthesia consultation. The design and description of the current trial adhered to the guidelines of the Consolidated Standards of Reporting Clinical Trials statement. Every patient file of this trial was overseen by an independent data safety monitoring board from Montpellier University Hospital Biostatistics Department. Exclusion criteria included presence of a bleeding disorder, peripheral neuropathy or chronic pain syndrome, local infection or injury at the needle entry point, allergy to local anesthetics, concomitant rhinoplasty, current treatment for pain relief, and participation in another clinical trial. We also excluded children with airway obstructive syndrome attested by polysomnography.

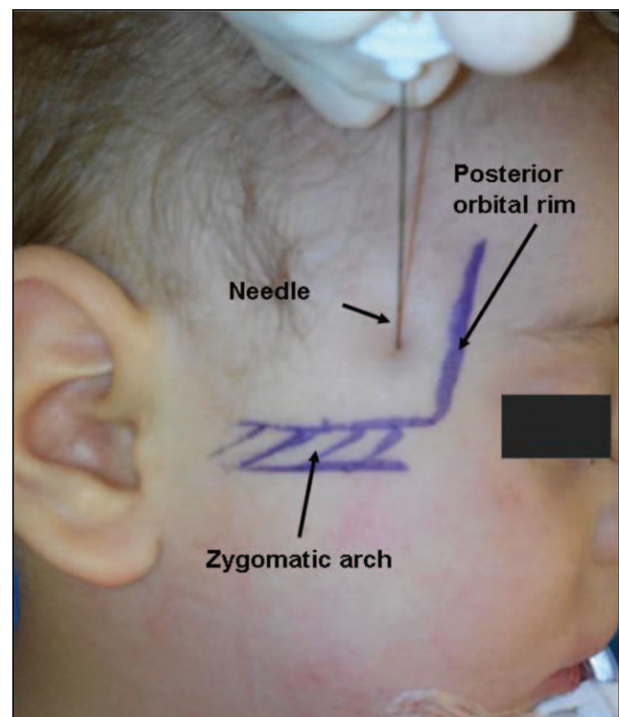
Children were randomly assigned, in a 1:1 ratio, in two parallel arms to receive either 0.15 ml/kg of 0.2% ropivacaine (Ropi group) or 0.15 ml/kg of isotonic saline (Saline group) on each side. We used a simple randomization generated by our institutional biostatistics department using a computer-generated random sequence. All injected solutions were prepared in identical syringes by a nurse anesthetist not involved in clinical management and were presented to the anesthesiologist in a blinded manner. The patient, surgeon, anesthesiologist, and clinical research assistant collecting the data were all blinded to the solution administered.

Patients were premedicated with rectal midazolam (0.5 mg/kg) and atropine (20 µg/kg) 30 min before anesthesia. Noninvasive blood pressure, electrocardiography, oxygen saturation, end-tidal carbon dioxide, and rectal temperature were continuously monitored intraoperatively. General anesthesia was induced with sevoflurane (inspired fraction of 6% in a 50% oxygen–nitrous oxide mixture), and 0.1 to 0.2 µg/kg IV sufentanil, and completed with 3 to 5 mg/kg of IV propofol if oral intubation conditions were judged insufficient. Cuffed endotracheal tubes were used and cuff pressure was monitored. Mechanical ventilation was adjusted to maintain 30 to 35 mmHg end-tidal carbon dioxide. Anesthesia was maintained with 1 minimum alveolar concentration of sevoflurane in a 50% oxygen–nitrous oxide mixture.

Intraoperatively, patients received an infusion of glucose 1% crystalloid solution at 4 ml kg<sup>-1</sup> h<sup>-1</sup>.

According to our previous studies, bilateral SMB was performed before surgery in anesthetized infants, after aseptic preparation of the skin.<sup>12,13</sup> The patient was in supine position with the head in neutral position. The puncture site was at the frontozygomatic angle, at the junction of the upper edge of the zygomatic arch and the frontal process as shown in figure 1. The needle (50 mm, 25 gauge; Pajunk, nanoLine, Geisingen, Germany) was inserted perpendicular to the skin. It was advanced to reach the greater wing of sphenoid at approximately 20 mm depth, then withdrawn a few millimeters and redirected toward the nasolabial fold in a 20° forward and 10° downward direction.<sup>12,13</sup> The progression in the pterygopalatine fossa was 35 to 45 mm. Loss of resistance after passing through the temporalis muscle assisted in determining the puncture depth, and real-time ultrasound guidance was used to see the spread of local anesthetic in the pterygopalatine fossa.<sup>14</sup> After a negative blood aspiration test, 0.15 ml/kg of the blinded solution (0.2% ropivacaine in SMB or saline in sham block) was injected on each side. Immediate complications related to regional anesthesia were investigated: systemic toxicity related to local anesthetics (seizures, heart rhythm, or conduction disorder), bleeding at puncture site, pupil alteration, and ocular lesion.

Before surgical incision, the surgeon injected 0.9% saline with epinephrine 1/200,000 under the palatine mucosa. After incision, 0.1 µg/kg of sufentanil was injected if the



**Fig. 1.** Suprazygomatic maxillary nerve block landmarks. The needle entry point is situated at the angle formed by the superior edge of the zygomatic arch below and the posterior orbital rim forward.

mean arterial pressure or heart rate increased more than 15% over the preoperative baseline values. Before the end of surgery, IV paracetamol 15 mg/kg and methylprednisolone 2 mg/kg were systematically administered. Paracetamol (15 mg/kg four times daily) and methylprednisolone (1 mg/kg twice daily) were administered IV over 15 min to all children for 48 h. The demographic characteristics of the patients, the type and duration of surgery, and intraoperative sufentanil requirements were recorded. Patients were extubated in the operating room after pharyngeal aspiration and recovery of airway-protective reflexes.

Total postoperative morphine consumption after 48 h was the primary outcome. During the first 48 h postoperatively, pain was assessed with the Children and Infants Postoperative Pain Scale (CHIPPS) score<sup>15</sup> every 10 min in the postanesthesia care unit (PACU) and every 2 h in the surgical ward. Pain control was considered insufficient when CHIPPS score was greater than 3/10. If CHIPPS score was between 3 and 5 on admission to the PACU, the child received 1 mg/kg of IV hydroxyzine to discriminate between pain and postoperative agitation. Then if necessary, IV morphine (20 µg/kg) was titrated every 2 min to obtain a CHIPPS score of 3 or less, with a maximal dose of 0.25 mg/kg. If the initial CHIPPS score was greater than 5, IV morphine titration was given first. If morphine titration exceeded 0.1 mg/kg, a continuous IV morphine infusion was started at 20 µg kg<sup>-1</sup> h<sup>-1</sup>. In the pediatric ward, rescue analgesia consisted of morphine administered by a nurse-controlled analgesia with a bolus dose of 20 µg/kg and modulation of continuous infusion according to the requirement: if more than two bolus doses were injected in 1 h, continuous infusion was started at (or increased by) 10 µg kg<sup>-1</sup> h<sup>-1</sup>. Conversely, if no bolus was injected during 4 consecutive hours, continuous infusion was decreased by 10 µg kg<sup>-1</sup> h<sup>-1</sup>. Analgesic medication was managed to obtain a CHIPPS score of 3 or less. Continuous monitoring of electrocardiography, respiratory rate, and oxygen saturation were maintained in the surgical ward. In the case of adverse events in relation to morphine use (excessive drowsiness, respiratory depression defined as oxygen saturation <90%, or respiratory rate <10 min<sup>-1</sup>), morphine administration was discontinued until normalization, and oxygen supplementation was delivered if needed. Morphine consumption was recorded every 2 h. Delay in feeding and postoperative nausea and vomiting (PONV) were recorded during the study period. At 5 days and 3 months postoperatively, delayed complications of the blocks were also investigated: hematoma, restricted mouth opening, vision, sensory or motor deficit, eating disorder, and local infection. Pain scores and respiratory- and SMB-related complications were considered as secondary endpoints.

### Statistical Analysis

The primary endpoint was a reduction in total morphine consumption at 48 h postoperatively. This trial was methodologically designed to identify superiority. According to

a previous retrospective study on 20 patients scheduled for CP repair in our institution, nalbuphine consumption in the first 48 h postoperatively was 1.4 ± 0.9 mg/kg. We considered a 50% reduction in opioid consumption to be clinically relevant. Assuming a two-sided type I error protection of 0.05 and a power of 0.80, 26 patients were required in the ropivacaine and saline groups to reveal a clinically significant difference. This number was increased to 30 patients per group. Continuous data were expressed as mean (SD), mean (CI), or median (range) as appropriate and frequencies (%) for categorical data. Data were analyzed by independent comparisons using the Student *t* test or the Mann–Whitney *U* test (two-tailed) as appropriate. Categorical variables were compared with the chi-square test or the Fisher test. For multiple comparisons, a Bonferroni correction was applied. *P* value less than 0.05 was considered significant. Statistical analysis was performed by using SAS software version 8.02 (SAS Institute, Cary, NC).

### Results

Sixty children (28 boys and 32 girls), with American Society of Anesthesiologists scores ranging from I to III, were included from December 2008 to July 2011. Three patients were excluded because of protocol violation: one patient in the Ropi group because of a neurological disease with chronic consumption of analgesics, which impeded reliable pain evaluation; two patients (in Ropi and Saline group) because of failure to maintain IV line, requiring switch of IV morphine to intrarectal nalbuphine. Regarding the 57 remaining patients, no data or measurements were missing or lost.

A flow chart of the study is presented in figure 2. The two groups were comparable for demographic data, except for a higher mean age in the Ropi group *versus* the Saline group (18 ± 11.8 and 12 ± 7.6 months, respectively). The demographic and surgical characteristics are reported in table 1.

The Mann–Whitney *U* test has shown that the overall dose of IV morphine (mean [95% CI]) at 48 h was lower in the Ropi group compared with that in the Saline group (104.3 [68.9 to 139.6] *vs.* 205.2 [130.7 to 279.7] µg/kg; *P* = 0.033). Figure 3 shows morphine consumptions per time interval in the two groups. The use of continuous morphine infusion was less frequent in the Ropi group compared with that in the Saline group (1 patient [3.6%] *vs.* 9 patients [31%]; *P* = 0.006). Three patients in the Saline group (including the two who were receiving a continuous infusion of morphine) presented an episode of oxygen desaturation requiring oxygen therapy in the ward (*P* = 0.24); none of the patients in the Ropi group needed oxygen therapy. No excessive drowsiness was noted in either group.

Intraoperative hemodynamic parameters, doses of sufentanil (0.28 ± 0.12 µg/kg in the Ropi group *vs.* 0.3 ± 0.13 µg/kg in the Saline group; *P* = 0.691), and postoperative hydroxyzine requirement (1 ± 1.16 mg/kg in the Ropi group *vs.* 1.13 ± 1.13 mg/kg in

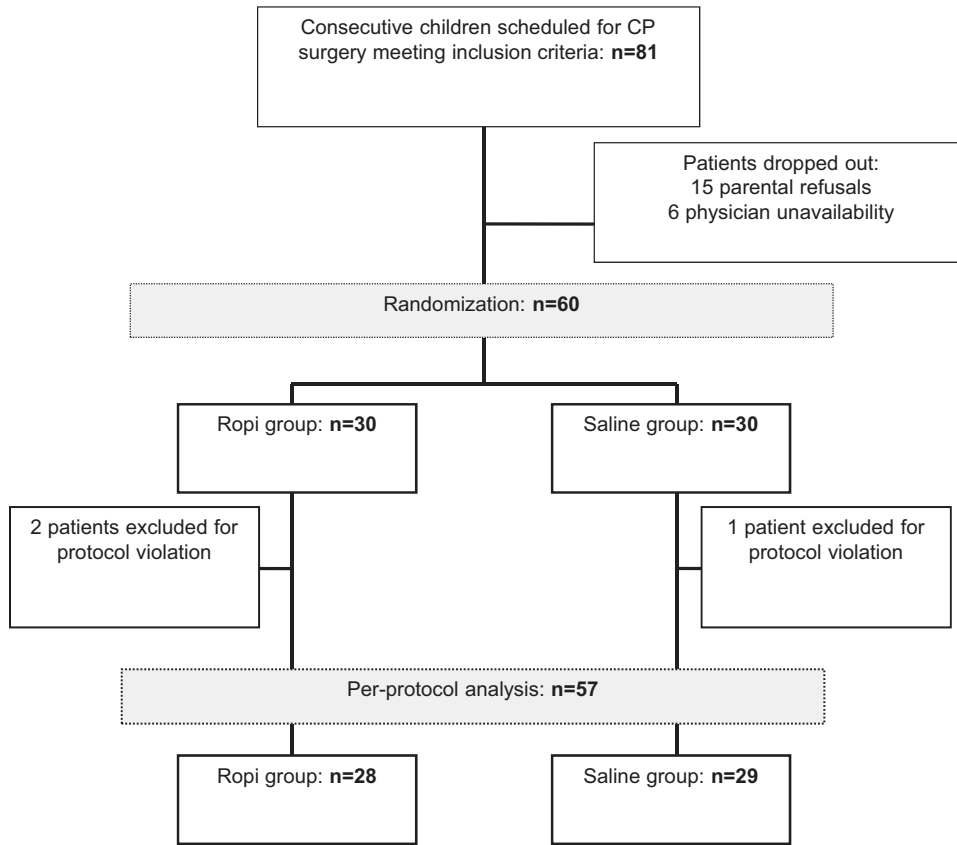


Fig. 2. Flow chart of the study. CP = cleft palate.

Table 1. Demographic and Surgical Characteristics

Variable	Ropi Group (n = 28)	Saline Group (n = 29)	P Value
<b>Demographic characteristics</b>			
Male/female ratio	12/16	16/13	0.35
Age, mo (mean ± SD)	18 ± 11.8	12 ± 7.6	0.03
Weight, kg (mean ± SD)	9.2 ± 2.48	8.7 ± 2.2	0.47
ASA scores I/II/III	18/9/1	20/6/3	0.42
<b>Surgical characteristics</b>			
Surgical time, min (mean ± SD)	92.6 ± 23.4	85.1 ± 23.6	0.23
Type of surgery, n (%)			
Hard palate	14 (50)	14 (48.5)	0.90
Soft palate	8 (29)	10 (34.5)	0.63
Both	6 (21)	5 (17)	0.69

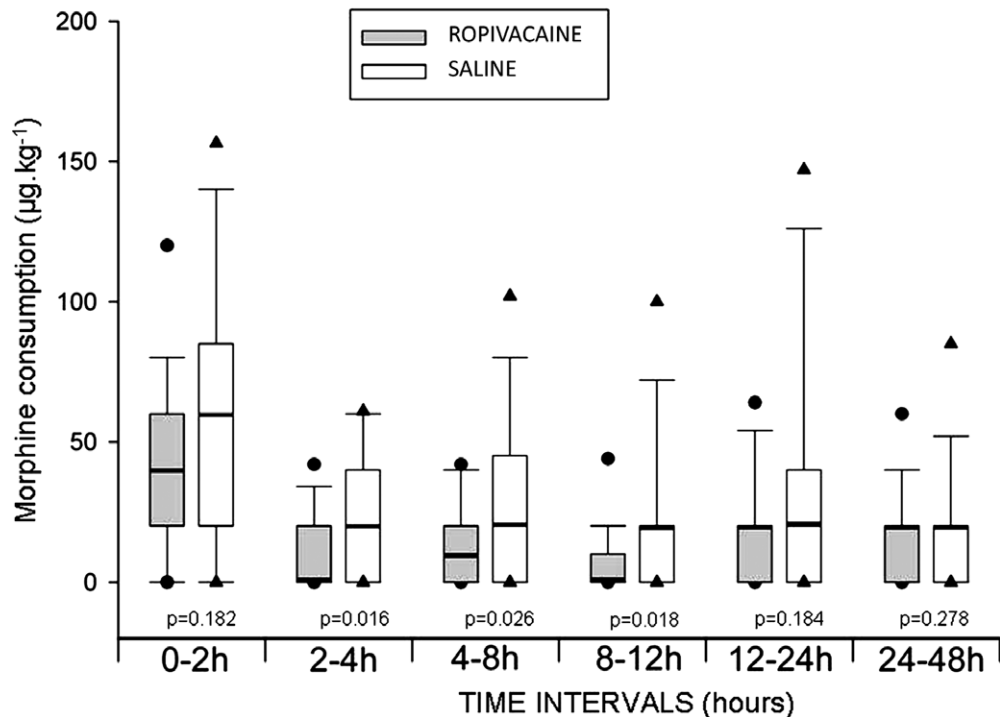
ASA = American Society of Anesthesiologists.

the Saline group;  $P = 0.64$ ) were not different between groups (mean ± SD). There was no statistically significant difference in Pain scores (CHIPPS) in the immediate postoperative period 0 to 4 h (fig.4). After 4h, CHIPPS score still did not differ and median values were always equal to zero.

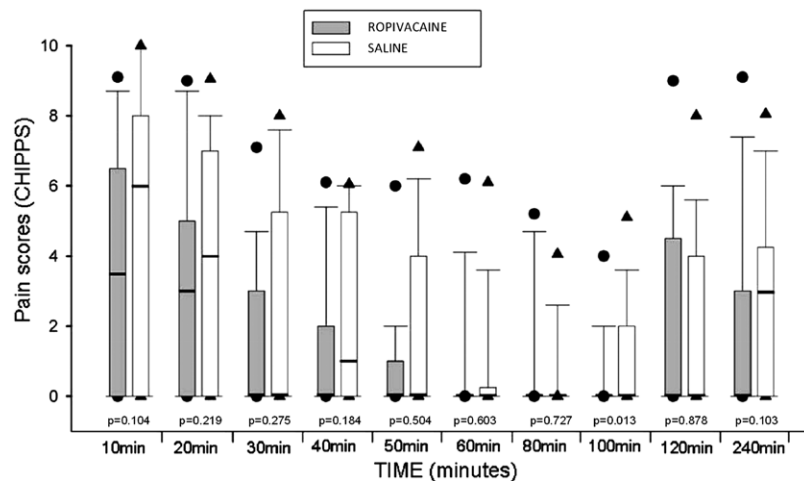
There was no statistically significant difference between Ropi and Saline groups for mean delay before feeding (respectively  $15.5 \pm 6.8$  vs.  $13.3 \pm 8.8$  h). Four patients in the Ropi group had PONV in the PACU and one patient in the ward, but there was no statistically significant difference between the two groups.

Two minor occurrences of bleeding related to the nerve block procedure were noted. These were immediate venous bleeding at the puncture site, which stopped after gentle external compression for less than a minute. On the second postoperative day, one patient in the Ropi group had a cheek hematoma in the infrazygomatic area. It was approximately 1 cm diameter, palpable extra- and intraorally. There was no mouth opening restriction and no dysphagia. At day 5 visit, it was spontaneously resolved. No complications related to SMB were noted at 5 days and 3 months postoperatively.





**Fig. 3.** Morphine consumption per time interval over 48 h. Medians, 25–75th percentiles (boxes), 10–90th percentiles (bars), and extremes (circles and triangles).  $P < 0.008$  was considered significant after Bonferroni correction (multiple comparisons).



**Fig. 4.** Pain scores (Children and Infants Postoperative Pain Scale [CHIPPS]) during the first 4 h. Medians, 25–75th percentiles (boxes), 10–90th percentiles (bars), and extremes (circles and triangles).  $P < 0.005$  was considered significant after Bonferroni correction (multiple comparisons).

## Discussion

This prospective, randomized, double-blind study demonstrated for the first time that bilateral SMB in anesthetized children allows statistically significant reduction in postoperative morphine consumption in the 48 h after CP repair *versus* placebo. Morphine consumption decreased by 50% in the Ropi group (104.3 [68.9 to 139.6] *vs.* 205.2 [130.7 to 279.7]  $\mu\text{g}/\text{kg}$ ;  $P = 0.033$ ) and the use of continuous IV morphine was lower in this group (1 patient [3.6%] *vs.* 9 patients [31%];  $P = 0.006$ ).

Few studies have been published on the use of opioids in CP repair in children. Rouleau *et al.*<sup>4</sup> noted a mean cumulative dose of sufentanil of 0.59  $\mu\text{g}/\text{kg}$  and a mean cumulative postoperative morphine consumption of 400  $\mu\text{g}/\text{kg}$  in 40 children undergoing CP surgery. Fenlon and Somerville<sup>16</sup> compared IV morphine (50  $\mu\text{g}/\text{kg}$ ) and intramuscular codeine (1 mg/kg) in 40 children after CP repair. Mean morphine consumption in PACU was 320 and 420  $\mu\text{g}/\text{kg}$  in the morphine and codeine groups, respectively. Both groups of patients received between 0.2 and 0.4 mg/kg of oral morphine in the surgical ward.

In our study, the mean cumulative doses of morphine were lower than those previously reported. At 48 h, the Saline group received 205.2 (130.7 to 279.7)  $\mu\text{g}/\text{kg}$  of morphine, that is, near than two times less than that in Roulleau's study.<sup>4</sup> This emphasizes good pain control related to the association of paracetamol and methylprednisolone. Moreover, the administration of morphine with nurse-controlled analgesia is designed to provide safe, potent, convenient, and flexible pain control, allowing a reduction in morphine administration.<sup>17</sup> Our protocol of postoperative morphine administration (see Materials and Methods) was designed to avoid unwarranted administration of morphine. Our results are in accordance with this goal, emphasizing the analgesic efficacy of SMB. SMB allowed the overall 48-h morphine consumption to decrease to 104.3 (68.9 to 139.6)  $\mu\text{g}/\text{kg}$ . This decrease in the consumption occurred in the Ropi group essentially between 2 to 12 h postoperatively. The number of patients included in the study was too low to have a statistically significant difference between the two groups during this time interval after Bonferroni multiple comparisons correction. After the 12th hour, there is a rebound of morphine consumption in Ropi group, probably related to the ending of the analgesic block. Difficulty to differentiate pain and anxiety in young children in the first postoperative hours<sup>18</sup> and occurrence of emergence delirium after sevoflurane anesthesia<sup>19</sup> may have lead to unwarranted administration of morphine despite effective analgesia in Ropi group, thereby partly blunting the real benefit of SMB. However, pain assessment with CHIPPS score has a good interrater reliability and guarantees that personal bias such as interindividual subjectivity was limited.<sup>18</sup>

Infants have an unpredictable sensitivity to opiates<sup>20</sup>; therefore, it is mandatory to spare morphine consumption to reduce the incidence of morphine-related respiratory depression. CP repair can lead to postoperative hypoxemia episodes because it reduces the airflow in the upper airway which has a small diameter in infants. According to Takemura *et al.*,<sup>2</sup> the risk of airway obstruction after CP surgery is increased in patients receiving opiates as a continuous infusion, justifying closer monitoring in the PACU or intensive care unit. Doyle and Hudson<sup>3</sup> reported three cases of severe respiratory depression among 143 CP repairs. One case was directly attributable to opiate consumption and the other two to Pierre–Robin syndrome. A regional anesthesia technique that allows sparing morphine consumption may decrease the occurrence of respiratory complications. In our study, three episodes of respiratory depression and oxygen desaturation requiring oxygen therapy occurred in the Saline group. Two of these children received continuous IV infusion of morphine, with high cumulative consumption at 48 h (495 and 640  $\mu\text{g}/\text{kg}$ ); both had Pierre–Robin syndrome. The third child also had Pierre–Robin syndrome but received low doses of morphine (40  $\mu\text{g}/\text{kg}$ ). Conversely, there was no oxygen desaturation in the Ropi group.

Increased occurrence of PONV in the Ropi group, although not statistically significant and despite a lesser postoperative consumption of morphine, is an unexpected result. It occurred in PACU, when sufentanil and morphine consumption were not yet different between the two groups. Among others, stimulation of sympathetic or vagal afferent fibers from pharynx or gastrointestinal tract is a known causative factor of PONV. A direct effect of ropivacaine on the vegetative afferent fibers of MN, distally to pterygopalatine ganglion, could explain this result. Alternatively, improved verbalization in slightly older patients ( $18 \pm 12$  vs.  $12 \pm 8$  months in Ropi and Saline groups, respectively) may explain the increased PONV in Ropi group. However, most of the patients were aged less than 3 yr, which is usually considered as the lower limit above which PONV increases.<sup>21</sup> However, absence of improvement in delay of first postoperative feeding in Ropi group may be explained by the weight of usual practice in wards, aiming to protection of intraoral sutures.

In this study, two minor immediate bleeding at puncture site were noted, they were easily stopped after external compression and one delayed cheek hematoma at day 2 that spontaneously resorbed. None of these children had complications or sequelae attributable to SMB 3 months after surgery. By adding this series of SMB with our previous studies,<sup>13,14</sup> we have a total of 116 patients, that is, 232 blocks. Although this number remains probably insufficient to make a definitive conclusion about safety, these data are in favor of a block without high risk. Local anesthetics (or saline) were injected under real-time ultrasound guidance to ensure injection in the pterygopalatine fossa.<sup>16</sup> This probably contributes to reduce the risk of serious complications such as extrasite injection and diffusion to other neural structures, especially for children with abnormal anatomy. Moreover, the low injected volumes of local anesthetics impeded diffusion out of the pterygopalatine fossa.

Different techniques have been described to block the MN and its terminal branches, but the suprazygomatic approach seems to be the safest and easiest way. Jonnavithula *et al.*<sup>22</sup> evaluated the efficacy of palatal block with 0.25% of bupivacaine *versus* a placebo for CP surgery in 45 children. These authors did not record any statistically significant difference in analgesic consumption and postoperative pain scores between the two groups. Kamath *et al.*<sup>23</sup> compared palatal blocks and systemic analgesia by IV pethidine in 50 children undergoing CP repair. Children with palatal blocks required lower rescue analgesia administration, but there was no difference in postoperative pain scores. Alternatively, Muthukumar *et al.*<sup>24</sup> reported better pain scores only in the 2 first postoperative hours, and saving of rescue analgesia only in the immediate postoperative period after local infiltration of lidocaine in cleft lip and/or palate repair. This may reflect rapid systemic absorption of local anesthetics injected in the palatal mucosa. Moreover, 20% of patients were being operated only for cleft lip repair.

In our study, intraoperative consumption of sufentanil was not different between the two groups. Several factors can explain this result. First, mouth spacers resulted in painful stress on the temporomandibular joints, some unblocked areas by SMB. Second, palatal epinephrine infiltration is a confounding factor for hemodynamic changes in case of resorption.

Some limitations in the current study must be taken into account. First, we chose to perform a sham block with saline in control group. Such procedures have been recently argued for ethical reasons.<sup>25</sup> Unfortunately, most of these recommendations have been edited subsequent to the writing of our study protocol and its approval by ethical committee (2008). At that time, doing a block with saline in control group appeared to us the most convenient method to ensure double-blind design throughout the study, an issue of paramount importance to make valid conclusion in view of the subjectivity and pitfalls of pain assessment in children.

Although age difference of 6 months between the two groups is a limitation of our study, we do not think that this difference reach clinical significance, because pain perception and analgesic pharmacology may be considered equivalent at these close ages on one hand. However, the CHIPPS pain score has been established and fully validated to evaluate postoperative pain in children from birth to 5 yr old, whatever the age of patients within this range.<sup>15</sup> Therefore, we do not think that age difference between the groups could make a bias in the assessment of pain, and therefore in our results, because protocol of morphine administration was exclusively based on the assessment of pain by the CHIPPS score.

Otherwise, we were not able to factually evaluate the success rate of the blocks because the patients were with general anesthesia. As for all peripheral nerve blocks, the technique has an inherent failure rate. In the absence of recognition of these failures, and because of the bilateral nature of the block, our results likely underestimate the real benefit of SMB in the quality of postoperative analgesia.

In conclusion, this study demonstrates that bilateral SMB performed with general anesthesia reduces total consumption of morphine at 48 h after CP repair in children. It also results in a statistically significant reduction in the use of continuous infusion of morphine and may decrease postoperative respiratory complications. Beyond this efficacy on acute postoperative pain, benefits in terms of chronic pain incidence and behavior disorders might be expected in future studies.

### Acknowledgments

Support was provided solely from institutional and/or departmental sources.

### Competing Interests

The authors declare no competing interests.

### Correspondence

Address correspondence to Dr. Chiono: Department of Anesthesiology and Critical Care Medicine, Lapeyronie University

Hospital, Avenue du Doyen G Giraud, Montpellier, France. j-chiono@chu-montpellier.fr. This article may be accessed for personal use at no charge through the Journal Web site, www.anesthesiology.org.

### References

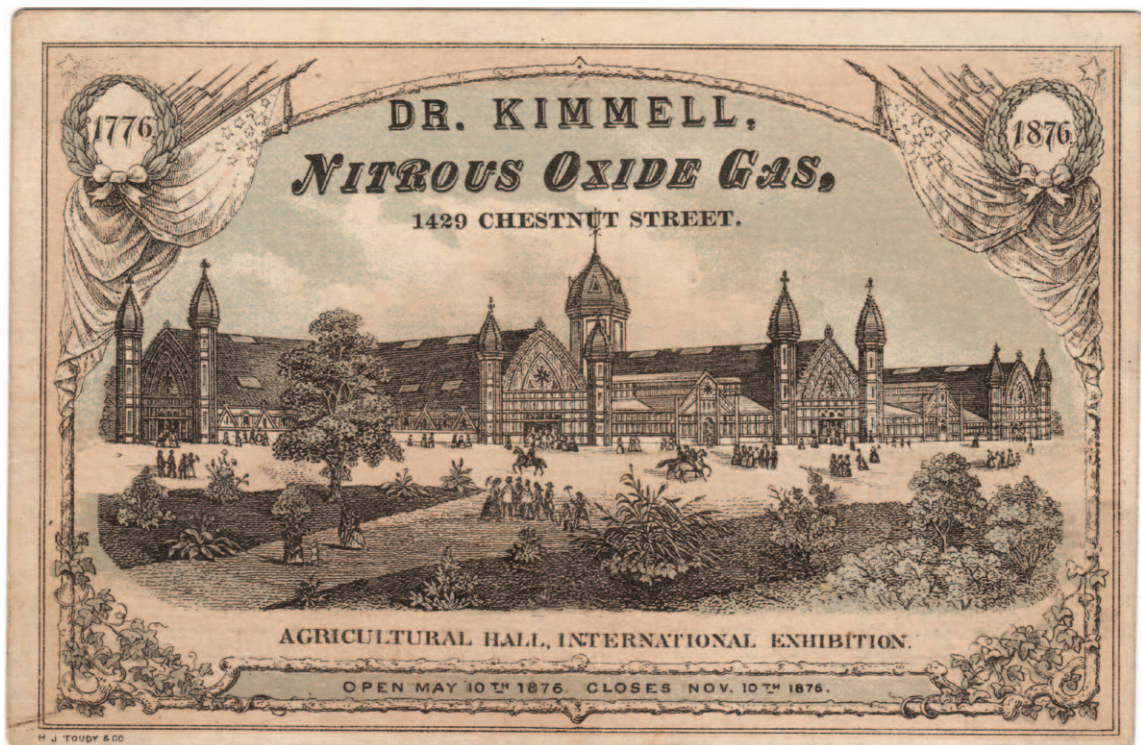
- Liau JY, Sadove AM, van Aalst JA: An evidence-based approach to cleft palate repair. *Plast Reconstr Surg* 2010; 126:2216–21
- Takemura H, Yasumoto K, Toi T, Hosoyamada A: Correlation of cleft type with incidence of perioperative respiratory complications in infants with cleft lip and palate. *Paediatr Anaesth* 2002; 12:585–8
- Doyle E, Hudson I: Anaesthesia for primary repair of cleft lip and cleft palate: A review of 244 procedures. *Paediatr Anaesth* 1992; 2:139–45
- Roulleau P, Gall O, Desjeux L, Dagher C, Murat I: Remifentanyl infusion for cleft palate surgery in young infants. *Paediatr Anaesth* 2003; 13:701–7
- Bösenberg AT, Kimble FW: Infraorbital nerve block in neonates for cleft lip repair: Anatomical study and clinical application. *Br J Anaesth* 1995; 74:506–8
- Rajamani A, Kamat V, Rajavel VP, Murthy J, Hussain SA: A comparison of bilateral infraorbital nerve block with intravenous fentanyl for analgesia following cleft lip repair in children. *Paediatr Anaesth* 2007; 17:133–9
- Ahuja S, Datta A, Krishna A, Bhattacharya A: Infra-orbital nerve block for relief of postoperative pain following cleft lip surgery in infants. *Anaesthesia* 1994; 49:441–4
- Prabhu KP, Wig J, Grewal S: Bilateral infraorbital nerve block is superior to peri-incisional infiltration for analgesia after repair of cleft lip. *Scand J Plast Reconstr Surg Hand Surg* 1999; 33:83–7
- Okuda Y, Okuda K, Shinohara M, Kitajima T: Use of computed tomography 2000; 25:417–9
- Singh B, Srivastava SK, Dang R: Anatomic considerations in relation to the maxillary nerve block. *Reg Anesth Pain Med* 2001; 26:507–11
- Stajčić Z, Todorović L: Blocks of the foramen rotundum and the oval foramen: A reappraisal of extraoral maxillary and mandibular nerve injections. *Br J Oral Maxillofac Surg* 1997; 35:328–33
- Captier G, Dadure C, Leboucq N, Sagintaah M, Canaud N: Anatomic study using three-dimensional computed tomographic scan measurement for truncal maxillary nerve blocks *via* the suprazygomatic route in infants. *J Craniofac Surg* 2009; 20:224–8
- Mesnil M, Dadure C, Captier G, Raux O, Rochette A, Canaud N, Sauter M, Capdevila X: A new approach for peri-operative analgesia of cleft palate repair in infants: The bilateral suprazygomatic maxillary nerve block. *Paediatr Anaesth* 2010; 20:343–9
- Sola C, Raux O, Savath L, Macq C, Capdevila X, Dadure C: Ultrasound guidance characteristics and efficiency of suprazygomatic maxillary nerve blocks in infants: A descriptive prospective study. *Paediatr Anaesth* 2012; 22: 841–6
- Büttner W, Finke W: Analysis of behavioural and physiological parameters for the assessment of postoperative analgesic demand in newborns, infants and young children: A comprehensive report on seven consecutive studies. *Paediatr Anaesth* 2000; 10:303–18
- Fenlon S, Somerville N: Comparison of codeine phosphate and morphine sulphate in infants undergoing cleft palate repair. *Cleft Palate Craniofac J* 2007; 44:528–31
- Howard RF, Lloyd-Thomas A, Thomas M, Williams DG, Saul R, Bruce E, Peters J: Nurse-controlled analgesia (NCA) following major surgery in 10,000 patients in a children's hospital. *Paediatr Anaesth* 2010; 20:126–34



18. Bringuier S, Picot MC, Dadure C, Rochette A, Raux O, Boulhais M, Capdevila X: A prospective comparison of post-surgical behavioral pain scales in preschoolers highlighting the risk of false evaluations. *Pain* 2009; 145:60–8
19. Vljakovic GP, Sindjelic RP: Emergence delirium in children: Many questions, few answers. *Anesth Analg* 2007; 104: 84–91
20. Chu YC, Lin SM, Hsieh YC, Chan KH, Tsou MY: Intraoperative administration of tramadol for postoperative nurse-controlled analgesia resulted in earlier awakening and less sedation than morphine in children after cardiac surgery. *Anesth Analg* 2006; 102:1668–73
21. Kranke P, Eberhart LH, Tokar H, Roewer N, Wulf H, Kiefer P: A prospective evaluation of the POVOC score for the prediction of postoperative vomiting in children. *Anesth Analg* 2007; 105:1592–7
22. Jonnavithula N, Durga P, Madduri V, Ramachandran G, Nuvvula R, Srikanth R, Damalcheruvu MR: Efficacy of palatal block for analgesia following palatoplasty in children with cleft palate. *Paediatr Anaesth* 2010; 20:727–33
23. Kamath MR, Mehandale SG, Us R: Comparative study of greater palatine nerve block and intravenous pethidine for postoperative analgesia in children undergoing palatoplasty. *Indian J Anaesth* 2009; 53:654–61
24. Muthukumar M, Arya VK, Mathew PJ, Sharma RK: Comparison of haemodynamic responses following different concentrations of adrenaline with and without lignocaine for surgical field infiltration during cleft lip and cleft palate surgery in children. *Anaesth Intensive Care* 2012; 40:114–9
25. Fahy C, Costi D, Cyna A: Invasive ‘placebo’ controls: Have we lost sight of whom we are blinding? *Paediatr Anaesth* 2011; 21:1089–91

## ANESTHESIOLOGY REFLECTIONS FROM THE WOOD LIBRARY-MUSEUM

### Kimmell’s Nitrous Oxide near the Centennial Exposition



H. J. Toudy & Co. were lithographers and printers of this trade card, the obverse of which depicted the Agricultural Hall in the International Exhibition of the Centennial Exposition of 1876. As the first official World's Fair in the United States, the Exposition celebrated the 100th anniversary of the signing of the Declaration of Independence. This trade card advertised dentist Samuel Kimmell and his use of “Nitrous Oxide Gas” in Philadelphia, the site of the Centennial Exposition. (See reverse of trade card in *Anesthesiology Reflections*, this issue, p. 1490.) This trade card is part of the Wood Library-Museum’s Ben Z. Swanson Collection. (Copyright © the American Society of Anesthesiologists, Inc.)

*George S. Bause, M.D., M.P.H., Honorary Curator, ASA’s Wood Library-Museum of Anesthesiology, Park Ridge, Illinois, and Clinical Associate Professor, Case Western Reserve University, Cleveland, Ohio. UJYC@aol.com.*