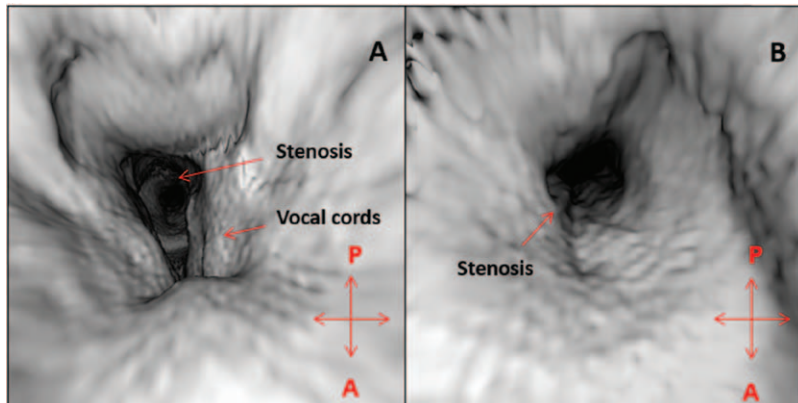


# Images in Anesthesiology: Endoluminal Computed Tomography

## *A Novel Technology for Assessment of Large Airway Pathologies*

Shvetank Agarwal, M.D., William B. Bates, M.D., Manuel R. Castresana, M.D.



**A**IRWAY management of patients with laryngeal and tracheal pathologies remains a challenge for the anesthesiologist. These may not be obvious during a routine physical examination and almost always warrant a formal radiological assessment.

Multidetector computed tomography is the imaging modality of choice for large airways.<sup>1</sup> Image acquisition allows for advanced reconstruction including surface and three-dimensional volume-rendered endoluminal viewing,<sup>2</sup> aptly called “virtual laryngo-tracheo-bronchoscopy” which provides an anatomical perspective to the structures for the observer.

We present the unique usefulness of endoluminal viewing in a 55-yr-old patient with severe nondynamic tracheal stenosis scheduled for tracheal dilatation. “Virtual direct laryngoscopy” mimicking an anesthesiologist’s view clearly displayed the tracheal stenosis through the vocal cords (fig. A). Placing the “camera” below the vocal cords allowed a zoomed-in view of the circular, smooth, uniform narrowing of the luminal surface of the mid-trachea (fig. B). This information enabled the anesthesiologist to choose the proper anesthetic induction while planning to place a 5.5 reinforced endotracheal tube through the narrowed segment of the trachea.

Endoluminal three-dimensional reconstruction can help the anesthesiologist devise a safe anesthetic plan in a variety of airway pathologies.<sup>3</sup> As many such patients undergo computed tomography of the neck and chest and most modern computed tomography scanners do not need any special software, this imaging modality will be more available in the future, to help the anesthesiologist decide the type of anesthetic induction and necessary maneuvers for securing a definitive airway, including the type, size, and depth of the endotracheal tube placement. The only limitation is the time required for postprocessing which decreases significantly with operator experience.

To our knowledge, prospective research on the predictive value of this three-dimensional reconstruction with regard to managing the airway is lacking; however, this relatively uncharted advanced reconstruction modality may facilitate safer anesthesia in patients with large airway pathologies.

### Competing Interests

The authors declare no competing interests.

### Correspondence

Address correspondence to Dr. Agarwal: [sagarwal@gru.edu](mailto:sagarwal@gru.edu)

### References

1. Ferretti GR, Bithigoffer C, Righini CA, Arbib F, Lantuejoul S, Jankowski A: Imaging of tumors of the trachea and central bronchi. *Radiol Clin North Am* 2009; 47:227–41
2. Silverman PM, Cooper CJ, Weltman DI, Zeman RK: Helical CT: Practical considerations and potential pitfalls. *Radiographics* 1995; 15:25–36
3. Horton KM, Horton MR, Fishman EK: Advanced visualization of airways with 64-MDCT: 3D mapping and virtual bronchoscopy. *AJR Am J Roentgenol* 2007; 189:1387–96

This article is featured in “This Month in Anesthesiology,” page 3A.

From the Department of Anesthesiology and Perioperative Medicine, Medical College of Georgia, Georgia Regents University, Augusta, Georgia (S.A.).

Copyright © 2014, the American Society of Anesthesiologists, Inc. Lippincott Williams & Wilkins. Anesthesiology 2014; 121:170