

## Avian Hemosporidian Parasite Lineages in Four Species of Free-ranging Migratory Waterbirds from Mongolia, 2008

Tracie A. Seimon,<sup>1,5</sup> Martin Gilbert,<sup>1</sup> Scott Neabore,<sup>1,4</sup> Charlotte Hollinger,<sup>1</sup> Ania Tomaszewicz,<sup>1</sup> Alisa Newton,<sup>1</sup> Tylis Chang,<sup>2,3</sup> and Denise McAloose<sup>1</sup> <sup>1</sup>Wildlife Conservation Society, 2300 Southern Blvd., Bronx, New York 10460, USA; <sup>2</sup>The Albert Einstein College of Medicine of Yeshiva University, 1300 Morris Park Ave., Bronx, New York 10461, USA; <sup>3</sup>Current address: Hofstra-North Shore LIJ School of Medicine, 500 Hofstra Blvd., Hempstead, New York 11549, USA; <sup>4</sup>Current address: Red Bank Veterinary Hospital, 197 Hance Ave., Tinton Falls, New Jersey 07724, USA; <sup>5</sup>Corresponding author (email: tseimon@wcs.org)

**ABSTRACT:** Avian hemosporidian parasites have been detected in Asia, but little information is known about the hemosporidian parasite lineages that circulate in waterbirds that migrate along the East Asian and Central Asian migratory flyways to breed in Mongolia. To gather baseline data on hemosporidian parasite presence in Mongolian waterbirds, 151 blood-spot samples (81 hatch year [HY] and 70 after hatch year [AHY]) from Bar-headed Goose (*Anser indicus*), Ruddy Shelduck (*Tadorna ferruginea*), Great Cormorant (*Phalacrocorax carbo*), and Mongolian Gull (*Larus mongolicus*) were screened for three genera of apicomplexan parasites, *Plasmodium*, *Haemoproteus*, and *Leucocytozoon*, using nested PCR. Of these, 17 samples (11%, 95% confidence interval: 7.1–17.4%), representing all four species, were positive. We identified 10 species (six *Plasmodium*, one *Haemoproteus*, and three *Leucocytozoon*) through mitochondrial DNA sequencing of the cytochrome *b* gene and BLAST analysis. One lineage shared 100% nucleotide identity to a hemosporidian parasite lineage that has been previously identified as *Plasmodium relictum* (SGS1). Six lineages were found in AHY birds and five in HY birds, the latter confirming that infection with some of the identified hemosporidian parasites occurred on the breeding grounds. Our data provide important baseline information on hemosporidian parasite lineages found in AHY waterbirds that breed and migrate through Mongolia as well as in HY offspring.

**Key words:** *Anser indicus*, *Haemoproteus*, *Larus mongolicus*, *Leucocytozoon*, *Phalacrocorax carbo*, *Plasmodium*, *Tadorna ferruginea*.

*Plasmodium*, *Haemoproteus*, and *Leucocytozoon* are Apicomplexan hemosporidian parasites that can infect birds and have the potential to cause clinical disease. Several authors have investigated blood parasites in Asian waterbirds (Manwell and Kuntz 1966; Ishtiaq et al. 2007; Yoshimura et al. 2014), but

none have focused on hemosporidian parasites in migratory birds in Mongolia. Wetlands in the mountainous region of Khovsgol Aimag Mongolia serve as a breeding ground and stopover location for migratory birds (BirdLife International 2004). Our study areas included three lakes (Erhel Nuur, 49°57'33"N, 99°54'08"E; Tsangiyn Dalai Nuur, 49°14'00"N, 99°03'00"E; and Tsengel Nuur, 49°44'54"N, 101°01'01"E) and a wetland complex of rivers, ponds, and lakes (Darkhad Valley, 51°13'00"N, 99°24'00"E) where waterbirds are known to breed and congregate during migration. We screened migratory waterbirds in these wetlands for hemosporidian parasites and examined hatch year (HY) bird samples to determine if parasite transmission occurs locally.

We captured birds 17 July 2008 to 3 September 2008 using hand nets and a spotlight, either from the shore or from a boat at night (geese, cormorants, and shelducks), or during the day on the breeding grounds (gulls; Fig. 1 and Supplementary Table), as described by Gilbert et al. (2012). Blood samples were collected from 151 birds. Species sampled included the Bar-headed Goose (*Anser indicus*; 30 after hatch year [AHY] birds), Great Cormorant (*Phalacrocorax carbo*; 25 AHY, 28 HY), Mongolian Gull (*Larus mongolicus*; 15 AHY, 23 HY), and Ruddy Shelduck (*Tadorna ferruginea*; 0 AHY, 30 HY) (see Supplementary Table). All birds appeared healthy when captured and were released after sampling.

Blood was drawn from the jugular vein and approximately 200  $\mu$ L of blood from each bird was transferred on to an individual Whatman

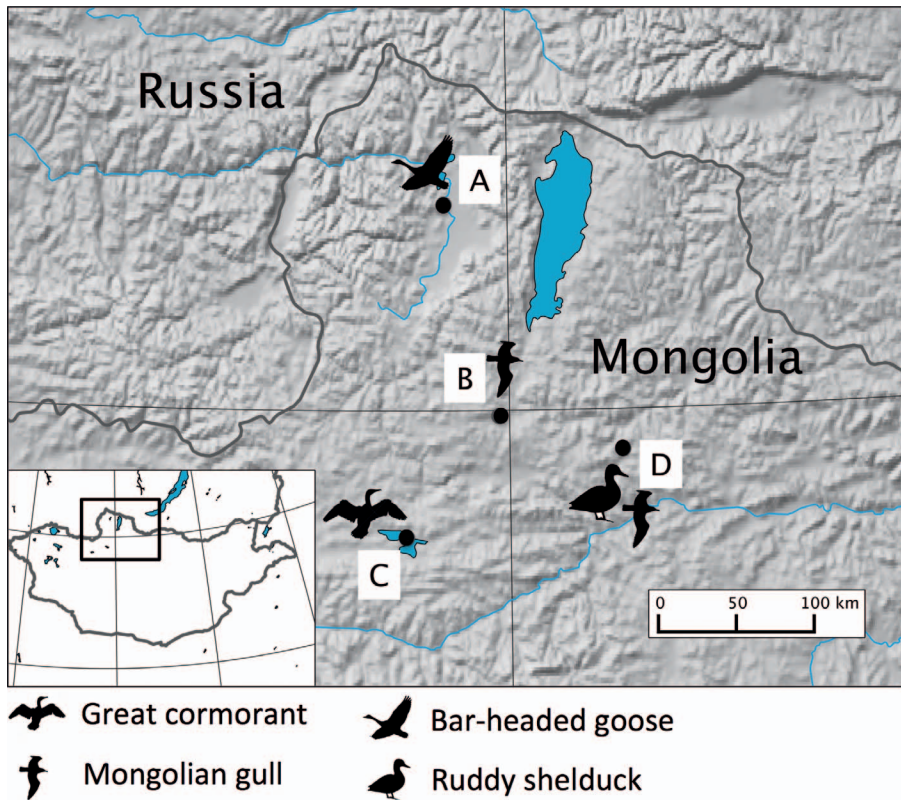


FIGURE 1. Four locations and corresponding shadow icons of each species of bird and where they were captured for blood collection in northern Mongolia, 17 July to 3 September 2008. A=Darkhad Valley (Bar-headed Goose, *Anser indicus*); B=Erhel Nuur (Mongolian Gull, *Larus mongolicus*); C=Tsangiyin Dalai Nuur (Great Cormorant, *Phalacrocorax carbo*); D=Tsengel Nuur (Mongolian Gull and Ruddy Shelduck, *Larus mongolicus* and *Tadorna ferruginea*, respectively).

903 Protein Saver Card (GE Healthcare, Piscataway Township, New Jersey, USA), air-dried, and stored at room temperature. For hemosporidian parasite PCR testing, DNA was extracted from a 6-mm filter paper punch using the QIAmp® DNA Mini Kit (Qiagen, Valencia, California, USA). Nested PCR amplification of a 478-base pair (bp) portion of the hemosporidian parasite cytochrome *b* gene was performed with HotStarTaq™ Master Mix (Qiagen) using previously described methods (Hellgren et al. 2004). Negative (no template) and positive controls for *Plasmodium*, *Haemoproteus*, and *Leucocytozoon* were run with each reaction. As an internal amplification control, all DNA extracts were tested for amplification of a 457-bp product of the avian host cytochrome *b* gene (Townzen et

al. 2008). All DNA extracts yielded positive amplification of the internal amplification control. The PCR products of the expected molecular weight from the hemosporidian parasite cytochrome *b* amplification were purified using ExoSAP-IT® (Affymetrix, Santa Clara, California, USA) and directly sequenced in the forward and reverse directions (Genewiz Inc., South Plainfield, New Jersey, USA). All sequences were trimmed of their primers to 476 bp, and sequences were subjected to BLAST analysis using GenBank, National Center for Biotechnology Information (<http://blast.ncbi.nlm.nih.gov/Blast.cgi>), and the MalAvi database (Bensch et al. 2009). Final sequences were deposited in GenBank under accessions KJ577823–KJ577838 and KU361371. Blood smears were

prepared from fresh whole blood immediately after collection. Once dry, the slides were fixed in methanol and stained with a Romanowsky-type stain within 12 h of collection. Samples PCR-positive for hemosporidian parasites, with the exception of one slide that was missing (MN08 B-0333B, Great Cormorant), were independently examined by two certified wildlife pathologists, microscopically, for hemosporidian parasites. Pathologists independently scanned each of the 16 blood films at 100 $\times$ , 200 $\times$ , and 400 $\times$  and performed focused parasite screening for 3 to 5 min at 630 $\times$  (Leica DM 2500 microscope, Leica Microsystems Inc., Buffalo Grove, Illinois, USA). Additionally, one pathologist reviewed 100 fields of each blood film under 1,000 $\times$  oil immersion (Nikon Eclipse 55i, Nikon Instruments Inc., Melville, New York, USA; Valkiūnas 2005). Cytologic preparations were of good quality with well-spread erythrocytes and insignificant cell lysis. The slide staining varied mildly, with regional basophilia or pallor affecting  $\leq 50\%$  of the slide in approximately 25% of cases, but there was adequate cytoplasmic and nuclear differentiation in all slides, and morphologic details of all cell types were apparent.

Apicomplexan hemosporidian parasites were identified in 17 of 151 samples by PCR (11%, 95% Adjusted Wald confidence interval: 7.1–17.4%). The percentages of each avian species that were positive were as follows: AHY Bar-headed Goose (7%, 2/30), HY Great Cormorant (11%, 3/28), AHY Great Cormorant (20%, 5/25), HY Mongolian Gull (4%, 1/23), AHY Mongolian Gull (7%, 1/15), and HY Ruddy Shelduck (17%, 5/30). No HY or AHY Bar-headed Geese were tested. No organisms were identified microscopically in any of the PCR-positive slides. The absence of hemosporidian parasites on blood smears may reflect low levels of infection. Alternatively, infection could be limited to exoerythrocytic stages (prepatent period) or parasitism of deep vascular or organ sites (latent stage), as has been suggested in penguins (Cranfield et al. 1994); or these lineages could undergo abortive development in these birds, resulting

in an absence of gametocytes (Valkiūnas et al. 2014).

Six *Plasmodium* lineages were identified in six birds (Table 1). One of the sequences, from a HY Mongolian Gull (A860), was 100% identical to a P\_SGS1 lineage, identified from a Hawfinch (*Coccothraustes coccothraustes*) in Russia, which was morphologically and genetically characterized as *Plasmodium relictum* (Palinauskas et al. 2007). The sequence from an AHY Great Cormorant (B280) was 100% identical to a P\_SW2 lineage previously found in a Common Grasshopper Warbler (*Locustella naevia*) from Russia (Ilgūnas et al. 2013). The sequences from samples A-0812 and A-0712 (HY Ruddy Shelduck), and B-0263 (AHY Great Cormorant) were submitted to the MalAvi database as new lineages: P-TADFER01, P-TADFER02, and P-PHACAR01.

One *Haemoproteus* lineage was recovered from seven birds: one AHY Bar-headed Goose, three HY Ruddy Shelduck, and two HY and an AHY Great Cormorant; it did not match morphologically characterized species from the MalAvi in GenBank. This lineage was submitted to the MalAvi database as ANSIND01.

Three *Leucocytozoon* lineages were recovered from four birds. Two of the samples, an AHY Bar-headed Goose (A235) and an AHY Great Cormorant (B298), were 100% identical to TUSW04 lineage found in Tundra Swans (*Cygnus columbianus*) from Alaska (GenBank JQ314223; Ramey et al. 2012). The second *Leucocytozoon* lineage from an AHY Mongolian Gull (A706) was 100% identical to CIAE02 lineage (GenBank EF607287) found in a Western Marsh Harrier (*Circus aeruginosus*) in Germany (Krone et al. 2008). The third *Leucocytozoon* lineage from an HY Great Cormorant (B-0256) did not match a known sequence and was submitted to the MalAvi database as PHACAR02.

In conclusion, we identified 10 lineages of hemosporidian parasites in migratory waterbirds that breed in Mongolia, and a hemosporidian parasite prevalence of 11%, in apparently healthy AHY and HY birds. Hemosporidian parasites in adult birds could

TABLE 1. GenBank accession numbers, sample identification number (ID), and corresponding hemosporidian parasite lineage identified in migratory waterbirds from Mongolia, 17 July to 3 September 2008. Ages of birds are categorized as after hatch year (AHY) or hatch year (HY).

GenBank accession no.	Sample ID MN-08-	Hemosporidian parasite	Cytochrome <i>b</i> lineage name according to MalAvi (=100% nucleotide identity)	Avian host species common name	Avian host species scientific name	Sample site	Age class
KJ577823	A-0235	<i>Leucocytozoon</i>	TUSW04	Bar-headed Goose	<i>Anser indicus</i>	Darkhad Valley	AHY
KJ577824	A-0242	<i>Haemoproteus</i>	ANSIND01	Bar-headed Goose	<i>A. indicus</i>	Darkhad Valley	AHY
KJ577825	B-0263	<i>Plasmodium</i>	PHACAR01	Great Cormorant	<i>Phalacrocorax carbo</i>	Tsangiyin Dalai Nuur	AHY
KJ577826	B-0280	<i>Plasmodium</i>	SW2	Great Cormorant	<i>P. carbo</i>	Tsangiyin Dalai Nuur	AHY
KJ577827	B-0298	<i>Leucocytozoon</i>	TUSW04	Great Cormorant	<i>P. carbo</i>	Tsangiyin Dalai Nuur	AHY
KJ577828	B-0305	<i>Haemoproteus</i>	ANSIND01	Great Cormorant	<i>P. carbo</i>	Tsangiyin Dalai Nuur	AHY
KJ577829	B-0333	<i>Plasmodium</i>	ORW1	Great Cormorant	<i>P. carbo</i>	Tsangiyin Dalai Nuur	AHY
KU361371	B-0250	<i>Haemoproteus</i>	ANSIND01	Great Cormorant	<i>P. carbo</i>	Tsangiyin Dalai Nuur	HY
KJ577830	B-0251	<i>Haemoproteus</i>	ANSIND01	Great Cormorant	<i>P. carbo</i>	Tsangiyin Dalai Nuur	HY
KJ577831	B-0256	<i>Leucocytozoon</i>	PHACAR02	Great Cormorant	<i>P. carbo</i>	Tsangiyin Dalai Nuur	HY
KJ577832	A-0706	<i>Leucocytozoon</i>	CIAE02	Mongolian Gull	<i>Larus mongolicus</i>	Tsengel Nuur	AHY
KJ577833	A-0860	<i>Plasmodium</i>	SGS1	Mongolian Gull	<i>L. mongolicus</i>	Erhel Nuur	HY
KJ577834	A-0676	<i>Haemoproteus</i>	ANSIND01	Ruddy Shelduck	<i>Tadorna ferruginea</i>	Tsengel Nuur	HY
KJ577835	A-0712	<i>Plasmodium</i>	TADFER01	Ruddy Shelduck	<i>T. ferruginea</i>	Tsengel Nuur	HY
KJ577836	A-0729	<i>Haemoproteus</i>	ANSIND01	Ruddy Shelduck	<i>T. ferruginea</i>	Tsengel Nuur	HY
KJ577837	A-0740	<i>Haemoproteus</i>	ANSIND01	Ruddy Shelduck	<i>T. ferruginea</i>	Tsengel Nuur	HY
KJ577838	A-0812	<i>Plasmodium</i>	TADFER02	Ruddy Shelduck	<i>T. ferruginea</i>	Tsengel Nuur	HY

represent various stages of infection and, because organisms were not identified in blood films, further characterization was not possible. All four bird species included in this study follow distinct migratory routes from their boreal breeding grounds in the wetlands of Mongolia to wintering areas in the milder climates of the Indian subcontinent, Southeast Asia, China, or the Korean Peninsula. For example, the Bar-headed Goose overwinters from the Tibetan Plateau south through much of the Indian Subcontinent (Newman et al. 2012). The wintering distribution of Mongolian Great Cormorants is poorly known but could include areas of the Indian Subcontinent, Southeast Asia, and China (Orta et al. 2016). Mongolian Gulls migrate to coastal China and the Korean Peninsula (Brazil 2009). Mongolian breeding populations of Ruddy Shelducks migrate to eastern and northeastern India, Myanmar, and possibly areas of China (Prosser et al. 2009; Newman et al. 2012; Carboneras and Kirwan 2016). While adult birds could have become infected at any point along the migration route, infection in HY birds would have occurred at the breeding grounds. Our results expand the known range of hemosporidian parasite lineages and provide important baseline data that contribute to a better understanding of the geographic range and types of hemosporidian parasites that infect waterbirds along their migratory routes and at their breeding grounds in northern Mongolia.

We thank the Wildlife Conservation Society's Wildlife Health and Health Policy Program for providing samples. This project was funded by donors supporting the Wildlife Conservation Society Zoological and Wildlife Health and Health Policy Programs, and funding was provided by the National Institute of Allergy and Infectious Diseases, National Institutes of Health, and the Department of Health and Human Services under contract HHSN266200700007C.

#### SUPPLEMENTARY MATERIAL

Supplementary material for this article is online at <http://dx.doi.org/10.7589/2015-11-311>.

#### LITERATURE CITED

- Bensch S, Hellgren O, Pérez-Tris J. 2009. MalAvi: A public database of malaria parasites and related haemosporidians in avian hosts based on mitochondrial cytochrome *b* lineages. *Mol Ecol Resour* 9:1353–1358.
- Brazil M. 2009. *Field guide to the birds of East Asia: China, Taiwan, Korea, Japan, and Russia*. A and C Black Publishers, London, UK, 206 pp.
- Carboneras C, Kirwan GM. 2016. Ruddy Shelduck (*Tadorna ferruginea*). In: *Handbook of the birds of the world alive*, del Hoyo J, Elliott A, Sargatal J, Christie DA, de Juana E. editors. Lynx Edicions, Barcelona, Spain. <http://www.hbw.com/node/52835>. Accessed January 2016.
- BirdLife International. 2004. Important bird areas in Asia: Key sites for conservation. *BirdLife Conservation Series No. 13*. BirdLife International, Cambridge, UK, 191 pp.
- Cranfield MR, Graczyk TK, Beall FB, Ialeggio DM, Shaw ML, Skjoldager ML. 1994. Subclinical avian malaria infections in African Black-footed Penguins (*Spheniscus demersus*) and induction of parasite recrudescence. *J Wildl Dis* 30:372–376.
- Gilbert M, Jambal L, Karesh WB, Fine A, Shilegdamba E, Dulam P, Sodnomdarjaa R, Ganzorig K, Batchuluun D, Tseveenmyadag N, et al. 2012. Highly pathogenic avian influenza virus among wild birds in Mongolia. *PLoS One* 7:e44097.
- Hellgren O, Waldenström J, Bensch S. 2004. A new PCR assay for simultaneous studies of *Leucocytozoon*, *Plasmodium*, and *Haemoproteus* from avian blood. *J Parasitol* 90:797–802.
- Ilgūnas M, Palinauskas V, Iezhova TA, Valkiūnas G. 2013. Molecular and morphological characterization of two avian malaria parasites (*Haemosporida: Plasmodiidae*), with description of *Plasmodium homonucleophilum* n. sp. *Zootaxa* 3666:49–61.
- Ishitaq F, Gering E, Rappole JH, Rahmani AR, Jhala YV, Dove CJ, Milensky C, Olson SL, Peirce MA, Fleischer RC. 2007. Prevalence and diversity of avian hematozoan parasites in Asia: A regional survey. *J Wildl Dis* 43:382–398.
- Krone O, Waldenström J, Valkiūnas G, Lessow O, Muller K, Iezhova TA, Fickel J, Bensch S. 2008. Haemosporidian blood parasites in European birds of prey and owls. *J Parasitol* 94:709–715.
- Manwell R, Kuntz R. 1966. *Plasmodium hegneri* n. sp. from the European teal *Anas c. crecca* in Taiwan. *J Protozool* 13:437–440.
- Newman SH, Hill NJ, Spragens KA, Janies D, Voronkin IO, Prosser DJ, Yan B, Lei F, Batbayar N, Natsagdorj T, et al. 2012. Eco-virological approach for assessing the role of wild birds in the spread of avian influenza H5N1 along the central Asian flyway. *PLoS One* 7:e30636.
- Orta J, Garcia E, Jutglar F, Kirwan G, Boesman P. 2016. Great Cormorant (*Phalacrocorax carbo*). In: *Handbook of the birds of the world alive*, del Hoyo J, Elliott

- A, Sargatal J, Christie DA, de Juana E, editors. Lynx Edicions, Barcelona, Spain. <http://www.hbw.com/node/52629>. Accessed January 2016.
- Palinauskas V, Kosarev V, Shapoval A, Bensch S, Valkiūnas G. 2007. Comparison of mitochondrial cytochrome-b lineages and morphospecies of two avian malaria parasites of the subgenera *Haemamoeba* and *Giovannolaia* (Haemosporida: Plasmodiidae). *Zootaxa* 1626:39–50.
- Prosser D, Takekawa J, Newman S, Yan B, Douglas DC, Hou Y, Xing Z, Zhang D, Li T, Zhao D, et al. 2009. Satellite-marked waterfowl reveal migratory connection between H5N1 outbreak areas in China and Mongolia. *Ibis* 151:568–576.
- Ramey AM, Ely CR, Schmutz JA, Pearce JM, Heard DJ. 2012. Molecular detection of hematozoa infections in Tundra Swans relative to migration patterns and ecological conditions at breeding grounds. *PLoS One* 7:e45789.
- Townzen JS, Brower AVZ, Judd DD. 2008. Identification of mosquito bloodmeals using mitochondrial cytochrome oxidase subunit I and cytochrome b gene sequences. *Med Vet Entomol* 22:386–393.
- Valkiūnas G. 2005. Methods of collection and investigation. In: *Avian malaria parasites and other haemosporidia*. CRC Press, New York, New York, pp. 213–224.
- Valkiūnas G, Palinauskas V, Ilgūnas M, Bukauskaitė D, Dimitrov D, Bernotienė R, Zehtindžiev P, Ilieva M, Iezhova TA. 2014. Molecular characterization of five widespread avian haemosporidian parasites (Haemosporida), with perspectives on the PCR-based detection of haemosporidians in wildlife. *Parasitol Res* 113:2251–2263.
- Yoshimura A, Koketsu M, Bando H, Saiki E, Suzuki M, Watanabe Y, Kanuka H, Fukumoto S. 2014. Phylogenetic comparison of avian haemosporidian parasites from resident and migratory birds in northern Japan. *J Wildl Dis* 50:235–242.

*Submitted for publication 18 November 2015.*

*Accepted 8 February 2016.*