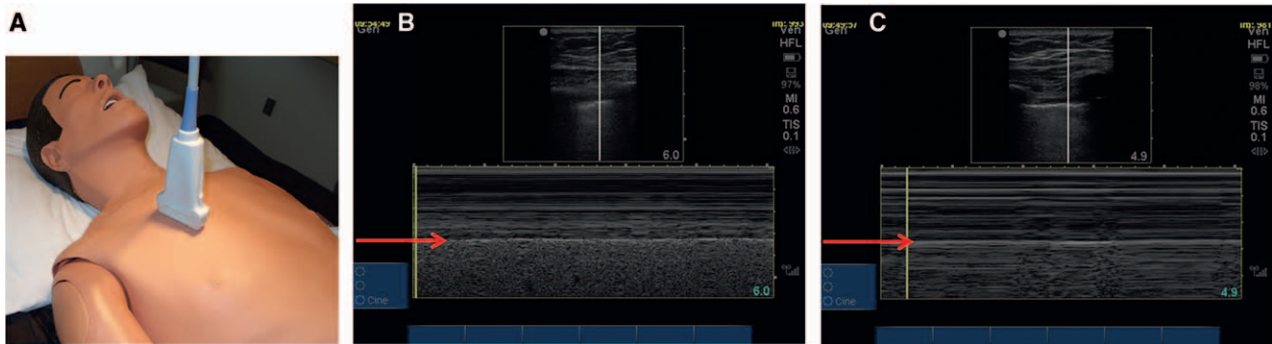


Charles D. Collard, M.D., Editor  
 Alan Jay Schwartz, M.D., M.S. Ed., Associate Editor

## Images in Anesthesiology: Bedside Lung Ultrasonography A Tool for Rapid Assessment of Pneumothorax

David W. Barbara, M.D.



**L**UNG ultrasound is a valuable diagnostic modality that allows for rapid assessment of pneumothorax. Compared to chest radiographs, lung ultrasound is more sensitive for pneumothorax.<sup>1–3</sup> Presence of lung sliding can be assessed with 2D or M-mode ultrasound and excludes pneumothorax at the intercostal space of the properly orientated ultrasound transducer (fig. A). M-mode displays structures encountered (vertical axis) across a single scan line in relation to time (horizontal axis). Figure B demonstrates normal lung sliding appearing as a granular homogenous pattern representing normal lung motion deep to the pleural line (arrow). Figure C shows replacement of the normal granular lung pattern with horizontal lines, which represent motionless artifacts in cases of pneumothorax. Horizontal lines superficial to the pleura in both figures represent normal (static) chest wall. Sonographic lung sliding accurately rules-out for pneumothorax, but imaging of multiple intercostal spaces in various lung fields is required.<sup>1,2</sup> Additionally, lack of lung sliding is not specific for pneumothorax, as it may be absent in other conditions such as mainstem intubation, apnea, acute respiratory distress syndrome, atelectasis, pneumonia, adhesions, contusion, and decreased lung compliance.

Lung ultrasound is highly specific for pneumothorax when the “lung point” is visualized.<sup>3</sup> The lung point is observed when both static lung field representing pneumothorax and lung motion are noted at the same intercostal space (Supplemental Digital Content 1, <http://links.lww.com/ALN/B103>; lung motion noted on right/caudal side of this video). The lung motion represents lung sliding at the visceral and parietal pleural layers’ interface. When obvious, sliding is true to name, and layers appear to slide across each other. When their movement is subtle, the sliding appears as a thin scintillating layer. With the ubiquitous nature of ultrasound in clinical practices, lung ultrasound provides an invaluable diagnostic tool for anesthesiologists that is more accurate and rapid than radiographic plain films.

### Competing Interests

The author declares no competing interests.

### Correspondence

Address correspondence to Dr. Barbara: [barbara.david@mayo.edu](mailto:barbara.david@mayo.edu)

### References

1. Alrajab S, Youssef AM, Akkus NI, Caldito G: Pleural ultrasonography *versus* chest radiography for the diagnosis of pneumothorax: Review of the literature and meta-analysis. *Crit Care* 2013; 17:R208
2. Lichtenstein DA, Mezière G, Lascols N, Biderman P, Courret JP, Gepner A, Goldstein I, Tenoudji-Cohen M: Ultrasound diagnosis of occult pneumothorax. *Crit Care Med* 2005; 33:1231–8
3. Volpicelli G: Sonographic diagnosis of pneumothorax. *Intensive Care Med* 2011; 37:224–32

Supplemental Digital Content is available for this article. Direct URL citations appear in the printed text and are available in both the HTML and PDF versions of this article. Links to the digital files are provided in the HTML text of this article on the Journal’s Web site ([www.anesthesiology.org](http://www.anesthesiology.org)).

From the Department of Anesthesiology, Mayo Clinic College of Medicine, Rochester, Minnesota.

Copyright © 2014, the American Society of Anesthesiologists, Inc. Wolters Kluwer Health, Inc. All Rights Reserved. *Anesthesiology* 2015; 122:921