

Opioid Half-lives and Hemlines

The Long and Short of Fashion

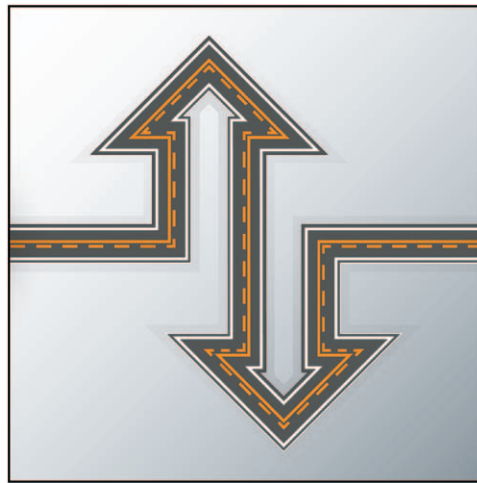
Evan D. Kharasch, M.D., Ph.D.

IN fashion, the most variable style element is the hemline, ranging from ultra-short (hip-high miniskirt) to ultra-long (floor-length).^{*} In anesthesiology, there has been similar fashion in opioid use, with the most variable element being the elimination half-life, ranging from ultra-short (remifentanyl) to ultra-long (methadone). Nominally, the former is 0.6 h, whereas that of the latter is 24 to 36 h.

Opioid use in cardiac surgery has been a particular focus.¹⁻⁴ The pioneering work of Lowenstein *et al.*¹ introduced high-dose morphine anesthesia for cardiac surgery. Since then, opioid-based anesthetic techniques for on-pump and off-pump coronary artery and valvular cardiac surgery have become *de rigueur*. Fentanyl largely supplanted morphine due to greater cardiovascular stability.^{2,3} The introduction of “fast-track” cardiac surgery created a new focus on rapid recovery, earlier extubation, and faster discharge from the intensive care unit and hospital. Coinciding with this trend was the introduction of fentanyl analogues with faster and faster elimination. Fentanyl (8- to 10-h elimination half-life) was followed by sufentanil (6 to 9 h), alfentanil (2 h), and remifentanyl.^{4,5} Thus, begat the fashion toward opioids with shorter and shorter half-lives.

Nevertheless, postoperative pain is a significant problem after cardiac surgery.⁶ The use of intraoperative opioids with faster elimination causes diminished postoperative analgesia. Various routes and modalities of administering opioids to achieve postoperative analgesia (*e.g.*, nurse-administered, patient-controlled, neuraxial) have been evaluated.⁷⁻⁹

In this issue of ANESTHESIOLOGY, Murphy *et al.*¹⁰ report a vastly different approach, and one that also departs substantially from the decades-long “fashion” of using opioids with faster elimination. For patients undergoing cardiac surgery, rather than using short-duration intraoperative and postoperative



“... Murphy *et al.* [demonstrate] the value of intraoperative methadone use in adult cardiac surgery.... Will it start a new trend?”

opioids, Murphy *et al.*¹⁰ used a single dose of methadone at induction, to confer intraoperative and postoperative analgesia. Methadone, in addition to use for treating opiate addiction and acute and chronic pain, is an excellent intraoperative opioid, which confers substantial postoperative analgesia for various surgical procedures.¹¹ The novel and well-performed clinical investigation by Murphy *et al.*¹⁰ demonstrates the value of intraoperative methadone use in adult cardiac surgery, extending its application and utility.

The study evaluated 156 patients undergoing cardiac surgery (coronary artery bypass and/or valve surgery, or atrial septal defect repair, *via* median sternotomy) with cardiopulmonary bypass. Patients were randomized to receive approximately equieffective doses of

methadone (0.3 mg/kg) or fentanyl (12 µg/kg), with half the dose given at induction and the remainder infused over the next 2 h. Patients postoperatively received intravenous morphine on request, and then oral opioids as soon as possible. The investigation is remarkable methodologically, for the frequency and thoroughness of intraoperative and postoperative data collection, including patient characteristics, operative and postoperative metrics, hemodynamics, postoperative troponin I and B-type natriuretic peptide concentrations, and postoperative complications, in addition to postoperative pain, analgesic requirements, and opioid-related complications.

The results are similarly notable. In patients receiving methadone (*vs.* fentanyl), the time until first postoperative morphine dose was longer, the 0- to 24-h and 0- to 72-h morphine requirements were lower, far fewer patients needed more than 20-mg morphine in the first 24 h, and more patients left the hospital needing no postoperative morphine. In addition, despite the availability

Image: ©Thinkstock.

Corresponding article on page 1112.

Accepted for publication December 29, 2014. From the Department of Anesthesiology, Division of Clinical and Translational Research and the Department of Biochemistry and Molecular Biophysics, Washington University in St. Louis, St. Louis, Missouri.

* Available at: <http://en.wikipedia.org/wiki/Hemline>. Accessed December 15, 2014.

Copyright © 2015, the American Society of Anesthesiologists, Inc. Wolters Kluwer Health, Inc. All Rights Reserved. Anesthesiology 2015; 122:969-70

of as-needed morphine, pain scores (at rest and with coughing) were lower in the group of patients receiving methadone. In patients who received a single dose of methadone at induction, compared with those receiving fentanyl, postoperative pain severity was reduced 30 to 40%, postoperative morphine requirements were diminished \approx 40%, and patients' satisfaction with pain management was significantly greater. There were no differences between methadone- and fentanyl-treated patients in the incidence of opioid-related side effects, extubation time, duration of intensive care unit or hospital stay, or complications.

All clinical benefit, without any apparent disadvantage. As identified by Murphy *et al.*,¹⁰ methadone in cardiac surgery patients can simplify perioperative opioid administration, enhance clinical recovery, and increase patient satisfaction. Methadone in cardiac surgery is definitely "antifashion." Will it start a new trend?

Acknowledgments

Supported by National Institutes of Health (Bethesda, Maryland) grants R01-DA14211 and R01-DA25931.

Competing Interests

The author is not supported by, nor maintains any financial interest in, any commercial activity that may be associated with the topic of this article.

Correspondence

Address correspondence to Dr. Kharasch: kharasch@wustl.edu

References

1. Lowenstein E, Hallowell P, Levine FH, Daggett WM, Austen WG, Laver MB: Cardiovascular response to large doses of intravenous morphine in man. *N Engl J Med* 1969; 281:1389–93
2. Bovill JG, Sebel PS, Stanley TH: Opioid analgesics in anesthesia: With special reference to their use in cardiovascular anesthesia. *ANESTHESIOLOGY* 1984; 61:731–55
3. Scott BH: Opioids in cardiac surgery: Cardiopulmonary bypass and inflammatory response. *Int J Cardiol* 1998; 64(Suppl 1):S35–41
4. Ahonen J, Olkkola KT, Hynynen M, Seppälä T, Ikävalko H, Remmerie B, Salmenperä M: Comparison of alfentanil, fentanyl and sufentanil for total intravenous anaesthesia with propofol in patients undergoing coronary artery bypass surgery. *Br J Anaesth* 2000; 85:533–40
5. Greco M, Landoni G, Biondi-Zoccai G, Cabrini L, Ruggeri L, Pasculli N, Giacchi V, Sayeg J, Greco T, Zangrillo A: Remifentanyl in cardiac surgery: A meta-analysis of randomized controlled trials. *J Cardiothorac Vasc Anesth* 2012; 26:110–6
6. Mueller XM, Tinguely F, Tevæarai HT, Revelly JP, Chioléro R, von Segesser LK: Pain location, distribution, and intensity after cardiac surgery. *Chest* 2000; 118:391–6
7. Roediger L, Larbuisson R, Lamy M: New approaches and old controversies to postoperative pain control following cardiac surgery. *Eur J Anaesthesiol* 2006; 23:539–50
8. Chaney MA: Intrathecal and epidural anesthesia and analgesia for cardiac surgery. *Anesth Analg* 2006; 102:45–64
9. Bainbridge D, Martin JE, Cheng DC: Patient-controlled *versus* nurse-controlled analgesia after cardiac surgery—a meta-analysis. *Can J Anaesth* 2006; 53:492–9
10. Murphy GS, Szokol JW, Avram MJ, Greenberg SB, Marymont JH, Shear T, Parikh KN, Patel SS, Gupta DK: Intraoperative methadone for the prevention of postoperative pain: A randomized, double-blinded clinical trial in cardiac surgical patients. *ANESTHESIOLOGY* 2015; 122:1112–22
11. Kharasch ED: Intraoperative methadone: Rediscovery, reappraisal, and reinvigoration? *Anesth Analg* 2011; 112:13–6