

## A Mortality Event in Elk (*Cervus elaphus nelsoni*) Calves Associated with Malnutrition, Pasteurellosis, and Deer Adenovirus in Colorado, USA

Karen A. Fox,<sup>1,4</sup> Levi Atwater,<sup>1</sup> Laura Hoon-Hanks,<sup>2</sup> and Myrna Miller<sup>3</sup> <sup>1</sup>Colorado Division of Parks and Wildlife, Wildlife Health Program, 4330 Laporte Ave., Fort Collins, Colorado 80521, USA; <sup>2</sup>Colorado State University Diagnostic Laboratory, 300 W Drake Rd., Fort Collins, Colorado 80526, USA; <sup>3</sup>Wyoming State Diagnostic Laboratory, 1174 Snowy Range Rd., Laramie, Wyoming 82070, USA; <sup>4</sup>Corresponding author (email: karen.fox@state.co.us)

**ABSTRACT:** This report describes clinical, necropsy, and ancillary diagnostic findings for a mortality event in Rocky Mountain elk (*Cervus elaphus nelsoni*) calves attributed to malnutrition, pasteurellosis, and an alimentary presentation of adenovirus hemorrhagic disease.

During the winter of 2015–16, a mortality event involving free-ranging Rocky Mountain elk (*Cervus elaphus nelsoni*) calves occurred in Garfield County, Colorado, US (39°39'31"N, 107°45'49"W). The mortalities occurred at a cattle ranch where, despite regulations, elk were allowed access to hay by the rancher during winter months when heavy snow covered the ground (supplemental feeding of big game species is illegal in Colorado). From January through early February, two adult elk cows and 15 elk calves were found dead or were euthanized due to clinical signs including emaciation, excessive salivation, and immobility. No cattle mortalities were reported. Four of the elk calves found dead or euthanized were submitted to the Colorado Division of Parks and Wildlife for evaluation.

Postmortem findings in all four calves included emaciation with marked depletion of fat stores and serous atrophy of femoral bone marrow fat. Dry rumen contents ( $n=4$ ) indicated dehydration. Ascites and pleural effusion ( $n=4$ ) indicated hypoproteinemia and/or sepsis. Fibrinous peritonitis and epicardial hemorrhages ( $n=3$ ) indicated sepsis. Bronchopneumonia was present in two calves. Gastrointestinal lesions included severe ruminal ulcerations (Fig. 1A) in two calves and multifocal hepatic necrosis and/or abscessation in two calves. Ancillary diagnostics for all animals included aerobic culture of lung,

aerobic culture of liver, histopathology, and PCR (see Supplementary Material), and immunohistochemistry (IHC; Woods et al. 1997) of various tissues for *Odocoileus* adenovirus-1 (OdAdV-1, deer adenovirus); the causative agent of adenovirus hemorrhagic disease (AHD) as described by Woods et al. (1996).

Bacterial isolates from pneumonic lung tissues included *Pasteurella multocida* ( $n=2$ ), and *Mannheimia hemolytica* ( $n=1$ ), whereas isolates from nonpneumonic lung tissues included *Trueperella pyogenes* ( $n=1$ ), *Escherichia coli* ( $n=1$ ), *Micrococcus* sp. ( $n=1$ ), and *Bacillus* sp. ( $n=1$ ). Aerobic isolates from liver tissues included *P. multocida* ( $n=1$ ), *M. hemolytica* ( $n=1$ ), *E. coli* ( $n=1$ ), *T. pyogenes* ( $n=1$ ), *Staphylococcus* sp. ( $n=1$ ), and *Streptococcus* sp. ( $n=1$ ).

Histologic findings included subacute suppurative bronchopneumonia ( $n=2$ ), regionally extensive pulmonary hemorrhage and edema ( $n=3$ ), multifocal to coalescing suppurative hepatitis ( $n=2$ ), bronchitis associated with nematodes consistent with *Dictyocaulus* species ( $n=1$ ), and mild multifocal necrotizing myocarditis ( $n=1$ ). The rumen ulcers found in two calves were associated with severe necrotizing arteritis in all layers of the rumen wall, with thrombosis and infarction resulting in ulcerations seen grossly.

For one of the two calves with rumen ulcers, arterioles at the margins of the infarcted tissue were lined by plump endothelial cells with frequent intranuclear basophilic inclusion bodies (Fig. 1B). Similar endothelial inclusions were rarely encountered in sections of lung from this animal. Immunohistochemical staining confirmed OdAdV-1 in rumen and lung.

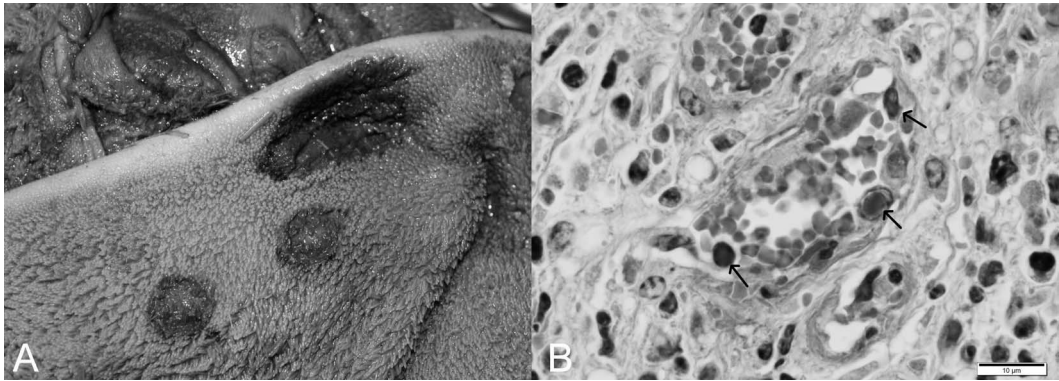


FIGURE 1. Rocky Mountain elk (*Cervus elaphus nelsoni*) from a mortality event in Colorado, USA during winter 2015–16, that was suspected to be associated with adenovirus hemorrhagic disease. Rumen ulcers were observed grossly (A), often associated with ruminal pillars. Histopathology (B) demonstrated necrotizing arteritis within multiple layers of the rumen wall, with arterioles lined by plump endothelial cells with frequent intranuclear basophilic inclusion bodies (arrows), consistent with deer adenovirus. Bar=10  $\mu$ m.

Lung, retropharyngeal lymph node, spleen, and liver from this animal were positive for OdAdV-1 by PCR. Virus isolation, BA5V-5 fluorescent antibody staining, and negative contrast electron microscopy confirmed the presence of adenovirus in the lung (see Supplementary Material).

One of the two calves with rumen ulcers lacked viral inclusions in all tissues examined, and all tissues tested (lung, retropharyngeal lymph node, spleen, and liver) were negative for OdAdV-1 by PCR and IHC. This is similar to findings in experimentally infected black-tailed deer (*Odocoileus hemionus columbianus*) that consistently developed localized necroulcerative lesions in the upper alimentary tract, but inconsistently demonstrated OdAdV-1 infection by identification of viral inclusions or IHC (Woods et al. 1999).

The two elk calves that lacked rumen ulcerations had AHD-like lesions of pulmonary hemorrhage and edema, although lung was IHC negative for OdAdV-1. Detection of OdAdV-1 by PCR was variable. For one calf, lung, retropharyngeal lymph node, spleen, and liver were all positive for OdAdV-1 by PCR, but only lung and retropharyngeal lymph node were positive in the second calf (spleen was not tested and liver was PCR negative). An additional real-time PCR assay performed for all tissues (see Supplementary

Material) confirmed positive PCR results and demonstrated lower levels (cycle threshold >29) of virus in tissues from these two calves than tissues from the calf with viral inclusions identified (cycle threshold <25).

We determined the cause of this mortality event to be multifactorial, with contributing factors including malnutrition, bronchopneumonia and septic disease suggestive of pasteurellosis, and an alimentary presentation of adenoviral hemorrhagic disease. Mortality events involving elk calves on winter range have been reported associated with malnutrition and pasteurellosis, including reports from the US National Elk Refuge (Thorne 1982; Franson and Smith 1988). In our cases, findings consistent with pasteurellosis included young animals affected during the winter months, profuse salivation noted antemortem, bronchopneumonia, lesions consistent with sepsis, and isolation of *Pasteurellaceae* bacteria from lung and liver tissues. Although many of these findings can also be observed with AHD, the primary lesion that prompted consideration of OdAdV-1 was rumen ulceration. Primary infections with adenovirus followed by secondary invasion by bacteria including *Pasteurellaceae* species have been reported (Woods et al. 1996), and the relative roles of the pathogens involved in this mortality event are uncertain.

Poor body condition in these elk calves was attributed to malnutrition, and was interpreted as a noninfectious stressor predisposing to disease. Unauthorized supplemental feeding in this case did not appear to mitigate poor forage availability and might have been detrimental through exacerbation of malnutrition (TWS 2006) and congregation of animals that enhanced disease spread (TWS 2006). Poor body condition is not typical for pasteurellosis, which has an acute course of disease manifested by animals found dead in good body condition (Franson and Smith 1988). Poor body condition has been associated with a chronic, localized (alimentary) presentation of AHD in mule deer with pharyngeal abscesses (Woods et al. 1997).

The findings described here could be helpful for the identification of adenovirus in elk mortalities, and to provide perspective on multifactorial causes for mortality events. Differential diagnoses for ulcerative lesions in the upper alimentary tract in elk should include OdAdV-1. Infections with OdAdV-1 that are limited to the alimentary tract can be difficult to diagnose by PCR and IHC, emphasizing the need to test multiple animals in suspected AHD-related mortality events. Lung, retropharyngeal lymph node, and spleen all appear to be representative samples for OdAdV-1 PCR testing in elk.

We thank Leslie Woods for assistance with immunohistochemical staining and interpre-

tation, and we thank Ivy LeVan and Michael Haverkate for necropsy assistance.

#### SUPPLEMENTARY MATERIAL

Supplementary material for this article is online at <http://dx.doi.org/10.7589/2016-07-167>.

#### LITERATURE CITED

- Franson JC, Smith BL. 1988. Septicemic pasteurellosis in elk (*Cervus elaphus*) on the United States National Elk Refuge, Wyoming. *J Wildl Dis* 24:715–717.
- Thorne ET. 1982. Pasteurellosis. In: *Diseases of wildlife in Wyoming*, 2nd Ed., Thorne ET, Kingston N, Jolley WR, Bergstrom RC, editors. Wyoming Game and Fish Department, Cheyenne, Wyoming, pp. 72–77.
- TWS (The Wildlife Society). 2006. Baiting and supplemental feeding of game wildlife species. *Technical Review 06 1*. The Wildlife Society, Bethesda, Maryland, 66 pp.
- Woods LW, Hanley RS, Chiu PH, Burd M, Nordhausen RW, Stillian MH, Swift PK. 1997. Experimental adenovirus hemorrhagic disease in yearling black-tailed deer. *J Wildl Dis* 33:801–811.
- Woods LW, Hanley RS, Chiu PH, Lehmkuhl HD, Nordhausen RW, Stillian MH, Swift PK. 1999. Lesions and transmission of experimental adenovirus hemorrhagic disease in black-tailed deer fawns. *Vet Pathol* 36:100–110.
- Woods LW, Swift PK, Barr BC, Horzinek MC, Nordhausen RW, Stillian MH, Patton JF, Oliver MN, Jones KR, MacLachlan NJ. 1996. Systemic adenovirus infection associated with high mortality in mule deer (*Odocoileus hemionus*) in California. *Vet Pathol* 33: 125–132.

Submitted for publication 15 July 2016.

Accepted 1 February 2017.