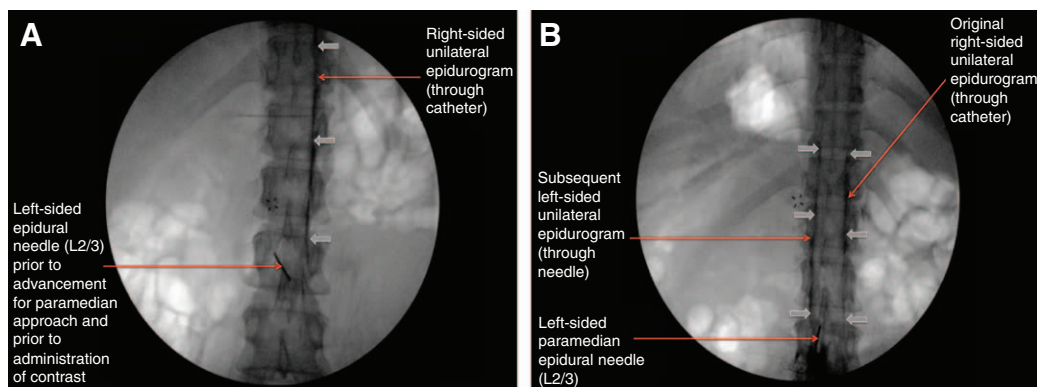


Plica Mediana Dorsalis

Unilateral Epidural Anesthesia and the Use of Bilateral Double Epidural Catheter Technique

Yehuda Ginosar, B.Sc., M.B.B.S., Elyad M. Davidson, M.D.



PLICA mediana dorsalis (PMD) has been rarely visualized but is occasionally implicated as a cause of unilateral epidural local anesthesia. Herein, we demonstrate PMD using epidurography. A normal anteroposterior epidurogram should show contrast outlining the

lateral margins of the epidural space bilaterally.¹ Herein, we show a unilateral epidurogram through a midline epidural catheter (fig. A) and a contralateral epidurogram through a second epidural needle inserted by contralateral paramedian approach under fluoroscopy (fig. B). Although computed tomography and necroscopy have demonstrated some degree of PMD in almost all patients,² this is rarely a completely intact membrane. Although generally asymptomatic, the incidence of symptoms is unclear based on the published data. In figure A and B, there is no spillover of contrast media (solid arrows) across the midline, characteristic of completely intact PMD.³

Unilateral epidural analgesia typically presents as inadequate analgesia with unilateral sympatholysis (warm, dry foot ipsilaterally; cold, clammy foot contralaterally). Most cases of unilateral anesthesia are successfully treated by an additional epidural dose after turning the patient and catheter withdrawal to a depth of 3 to 5 cm in the space. Occasionally patients present with persistent unilateral anesthesia despite these measures, where additional epidural dose further extends the unilateral block, causing ipsilateral chest wall and arm anesthesia, with ipsilateral Horner syndrome (see figure, Supplemental Digital Content 1, <http://links.lww.com/ALN/B244>). There is often a history of unilateral anesthesia or Horner syndrome in previous labor epidurals.³ Our current practice is to assume that these patients have a completely intact PMD. Accordingly, after allowing the initial block to wear off, we empirically perform contralateral paramedian epidural catheterization and manage labor analgesia with a bilateral double epidural catheter technique using two patient-controlled analgesia pumps, each using half the standard dose.

This figure highlights that PMD is a potential cause of unilateral epidural analgesia and that a bilateral double epidural catheter technique may be useful in these cases.

Competing Interests

The authors declare no competing interests.

Correspondence

Address correspondence to Dr. Ginosar: yginosar@icloud.com

References

- Rathmell JP, Song T, Torian D, Alsofrom GF: Lumbar epidurography. *Reg Anesth Pain Med* 2000; 25:540–5
- Savolaine ER, Pandya JB, Greenblatt SH, Conover SR: Anatomy of the human lumbar epidural space: New insights using CT-epidurography. *ANESTHESIOLOGY* 1988; 68:217–20
- McCrae AF, Whitfield A, McClure JH: Repeated unilateral epidural blockade. *Anaesthesia* 1992; 47:859–61

Supplemental Digital Content is available for this article. Direct URL citations appear in the printed text and are available in both the HTML and PDF versions of this article. Links to the digital files are provided in the HTML text of this article on the Journal's Web site (www.anesthesiology.org).

The figures are published with signed consent of the patient whose image was used and formal approval of the institutional review board of Hadassah Hebrew University Medical Center, Jerusalem, Israel (IRB number 0322-14-HMO).

From the Mother and Child Anesthesia Unit (Y.G.) and the Pain Relief Unit (E.M.D.), Department of Anesthesiology and Critical Care Medicine, Hadassah Hebrew University Medical Center, Jerusalem, Israel.

Copyright © 2016, the American Society of Anesthesiologists, Inc. Wolters Kluwer Health, Inc. All Rights Reserved. *Anesthesiology* 2016; 125:220