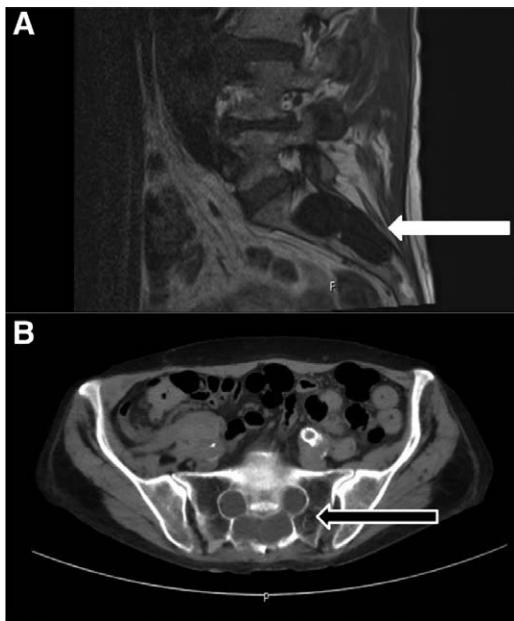


## Tarlov Cysts

### *Incidental Finding during Subarachnoid Drain Placement*

Vivek Arora, M.B.B.S., M.D., Irene Rozet, M.D.



**A**N 82-yr-old woman with Marfan syndrome presented for a thoracic aortic aneurysm repair. On review of radiological imaging, before lumbar subarachnoid drain placement, incidental cystic lesions were noted in the sacrum (fig. A and B). These were identified as perineural or Tarlov cysts (TCs). Subarachnoid drain placement was uneventful, clear cerebrospinal fluid (CSF) was drained throughout the perioperative period, and the patient made an uneventful recovery.

First described by Tarlov in 1938 as incidental autopsy findings, TCs are CSF-filled cavities that develop on the extradural components of spinal nerves between the endoneurium and the perineurium in close proximity to the dorsal root ganglion. The reported incidence of TCs is 1 to 5%, and TCs are usually noted in the sacrum although they have been described along the entire spinal column.<sup>1</sup> The etiology of TCs remains unclear, but most likely they arise from microcommunications within the subarachnoid space at the level of the dural cuff. This may function as a one-way valve causing CSF influx, cyst formation, and expansion.<sup>2</sup> TCs are mostly asymptomatic, but depending on size, location, and number, they can cause nerve root compression, pelvic/perineal pain, bowel/bladder, or sexual dysfunction.<sup>2</sup> TCs are seen on both magnetic resonance imaging (fig. A, white arrow: sagittal T1-weighted magnetic resonance image showing CSF density of cystic

lesions in the sacrum) and computed tomography (fig. B, black arrow: axial computed tomography showing bilateral sacral cystic lesions with foraminal widening) as CSF intensity, simple or loculated, cysts with occasional widening of the spinal foramina (fig. B). They must be differentiated from other cystic lesions, including intradural ectasias, subarachnoid cysts, and meningeal diverticula. In general, TCs do not require treatment, but if they are symptomatic, shunting, aspiration-injection with fibrin glue, and excision have been attempted with varying results.<sup>2</sup>

Anesthetic considerations include inadvertent puncture during caudal block, failed spinal (needle penetration in a cyst preventing intrathecal spread), and cauda equina syndrome.<sup>3</sup> With the increased use of radiological imaging, anesthesiologists should be familiar with these characteristically benign lesions. They should not preclude neuroaxial anesthesia or subarachnoid drain placement; however, they may warrant careful consideration of such techniques.

### Competing Interests

The authors declare no competing interests.

### Correspondence

Address correspondence to Dr. Arora: varora2@uw.edu

### References

- Langdown AJ, Grundy JR, Birch NC: The clinical relevance of Tarlov cysts. *J Spinal Disord Tech* 2005; 18:29–33
- Acosta FL Jr, Quinones-Hinojosa A, Schmidt MH, Weinstein PR: Diagnosis and management of sacral Tarlov cysts. Case report and review of the literature. *Neurosurg Focus* 2003; 15:E15
- Popham PA: Anatomical causes of failed spinal anaesthesia may be commoner than thought. *Br J Anaesth* 2009; 103:459; author reply 459

From the VA Puget Sound Health Care System, Seattle, Washington, and the Department of Anesthesiology and Pain Medicine, University of Washington, Seattle, Washington.

Copyright © 2016, the American Society of Anesthesiologists, Inc. Wolters Kluwer Health, Inc. All Rights Reserved. *Anesthesiology* 2016; 125:598