

# Avoiding Repeated Attempts at Tracheal Intubation

## Can Videolaryngoscopes Be the Answer?

Takashi Asai, M.D., Ph.D.

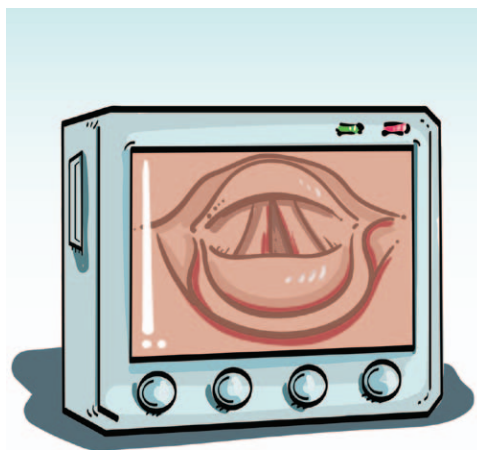
**CME**

This article has been selected for the ANESTHESIOLOGY CME Program. Learning objectives and disclosure and ordering information can be found in the CME section at the front of this issue.

**R**EPEATED attempts at tracheal intubation increase the incidence of airway obstruction, leading to serious airway complications.<sup>1,2</sup> Therefore, major guidelines for difficult airway management unanimously recommend avoiding repeated attempts at tracheal intubation.<sup>3-5</sup> Much effort has been made to reduce the incidence of difficult intubation with a conventional Macintosh or Miller laryngoscope, but the incidence seems to remain the same. Technological development allows us to use alternative intubation devices, but it is not clear which device is most suitable to minimize repeated attempts at intubation. In this issue of ANESTHESIOLOGY, Aziz *et al.*<sup>6</sup> studied which alternative intubation devices were frequently used in patients after intubation with a conventional laryngoscope had failed and compared the successful rates of intubation with the following alternative “rescue” devices: a videolaryngoscope, a fiberoptic bronchoscope, a supraglottic airway (as a conduit for tracheal intubation), a lighted stylet, and an optical stylet.

### Main Findings of Aziz *et al.*

Aziz *et al.*<sup>6</sup> retrospectively studied 1,427 patients in whom one of the five rescue devices was used after intubation using a conventional direct laryngoscope had failed. As a result, a videolaryngoscope, which was most frequently chosen among the five devices, was associated with a significantly higher success rate (92%) than the other devices: a supraglottic airway (78%), a fiberoptic bronchoscope (78%),



***“When tracheal intubation using a conventional laryngoscope has failed, a ‘rescue’ intubation device should be used at an early stage. It may be reasonable to regard videolaryngoscopes as the first choice, to minimize repeated intubation attempts.”***

a lighted stylet (77%), and an optical stylet (67%).

### Which Devices Are Effective?

With numerous anecdotal reports of the successful use of videolaryngoscopes in patients in whom tracheal intubation with conventional laryngoscopes had failed, several major studies have shown the usefulness of videolaryngoscopes in patients with difficult airways,<sup>7-9</sup> and Aziz *et al.*<sup>6</sup> have confirmed the usefulness. It may be difficult to make a definite conclusion from this nonrandomized study as to which device is the most effective because there would have been a selection bias (*e.g.*, videolaryngoscopes would not have been chosen in a patient with severely limited mouth opening). Nevertheless, videolaryngoscopes have several advantages over the other alternative intubation devices, and thus it may be reasonable to regard videolaryngoscopes as the first choice, to minimize repeated intubation attempts.

So, should we always use a videolaryngoscope when tracheal intubation is found difficult? The answer is no. In the study by Aziz *et al.*,<sup>6</sup> tracheal intubation could not be achieved with a videolaryngoscope in 10% of patients. Videolaryngoscopes may fail when there is a limited mouth opening, a large tongue, a tumor in the oropharynx or laryngospasm, when vision is blurred (by fogging, secretions, blood, or vomitus), or when cricoid pressure is being applied.<sup>7-10</sup> If videolaryngoscopes are chosen in patients with these problems, it may only increase the number of

ImagePower Productions, John Ursino.

Corresponding article on page 656.

Accepted for publication June 28, 2016. From the Department of Anesthesiology, Dokkyo Medical University Koshigaya Hospital, Minamikoshigaya, Koshigaya City, Saitama, Japan.

Copyright © 2016, the American Society of Anesthesiologists, Inc. Wolters Kluwer Health, Inc. All Rights Reserved. Anesthesiology 2016; 125:615-7

attempts at tracheal intubation, leading to a higher risk of serious airway complications.

How then should we judge which “rescue” intubation device is most suitable in each patient? Because the causes of difficult intubation differ among the patients and because there are differences in the efficacy of each intubation device for different causes of difficulty, we need to judge which device is most suitable by identifying the cause of difficult intubation in each patient. For example, when the cause of difficult intubation is severely limited mouth opening, a fiberoptic bronchoscope, rather than a videolaryngoscope or a supraglottic airway, is suitable. The problem we are facing is that we still do not know well about which intubation devices are likely to fail in each patient. For example, it is not known whether or not the causes of difficult intubation with a videolaryngoscope or other intubation devices differ from the causes for Macintosh blade. In addition, the efficacies of various videolaryngoscopes or supraglottic airways are likely to be different, but it is not known which device is more suitable.

We should also consider about the risk associated with the use of each device. If the intubation device injures the upper airway, its use would increase the risk of hypoxia due to airway obstruction. Generally, any blind method, such as insertion of a lighted stylet or a blind attempt at tracheal intubation through a supraglottic airway, should be regarded as less suitable than the other intubation methods, such as the use of a videolaryngoscope or a fiberscope. In the report of Aziz *et al.*,<sup>6</sup> injury to the upper airway occurred in some patients by the use of a videolaryngoscope. For some videolaryngoscopes that do not have a tube guide, a tracheal tube (with a stylet inside) is advanced blindly until the tip of the tube comes into the view on a video screen, and thus the use of a videolaryngoscope with a tube guide has a theoretical advantage.

Another factor that we should consider is the time required to intubate the trachea. For example, tracheal intubation using a fiberoptic bronchoscope may take a considerably long time. Tracheal intubation with a videolaryngoscope may also take a longer time than with a conventional laryngoscope. A prolonged apnea time may cause hypoxia in patients with reduced oxygen store, such as in obese patients, in obstetric women and children, and in patients who already have desaturation during repeated attempts at laryngoscopy. In fact, in the study by Aziz *et al.*,<sup>6</sup> hypoxia (defined as arterial hemoglobin oxygen saturation of less than 90%, for more than 1 min) occurred in 25% (372 of 1,511) of patients during the use of a rescue intubation device.

### When to Use?

Failed tracheal intubation in itself is not life threatening, as far as ventilation *via* a facemask is adequate.<sup>11,12</sup> The problem here is that mask ventilation is more likely to be difficult in the patient in whom tracheal intubation was difficult, and that repeated attempts at tracheal intubation can frequently make mask ventilation difficult. Aziz *et al.*<sup>6</sup> have shown that in patients in whom tracheal intubation using a conventional

direct laryngoscope had failed, mask ventilation was also either difficult or impossible in 10% of them (145 of 1427 patients). This incidence is much higher than in the general population (less than 1%).<sup>13</sup> In the report by Aziz *et al.*,<sup>6</sup> repeated attempts at tracheal intubation using a conventional laryngoscope were avoided in the majority of the patients, and thus the high incidence of difficult mask ventilation in their report was likely to be the coexistence of difficult intubation and difficult mask ventilation in those patients. Had intubation been attempted repeatedly, the incidence and the severity of hypoxia would have been greater.

If “cannot intubate, cannot oxygenate” situation occurs, guidelines recommend to insert a supraglottic airway, and if that also fails, to carry out cricothyrotomy or tracheostomy.<sup>3–5</sup> The problem here is that even these may frequently fail.<sup>14–16</sup> In fact, one report indicates that the availability of videolaryngoscopes and supraglottic airways did not seem to reduce the incidence of “cannot intubate, cannot oxygenate” situations after repeated attempts at tracheal intubation.<sup>2</sup>

### Conclusions

It is now clear that when tracheal intubation using a conventional laryngoscope has failed, a “rescue” intubation device, such as a videolaryngoscope, should be used at an early stage. In addition, multiple attempts using “rescue” intubation devices should also be avoided. Because there is still uncertainty as to which device to use, we need to carry out formal randomized controlled studies to assess which intubation devices can effectively reduce the number of repeated attempts at intubation to establish their roles in patients with difficult airways.

### Competing Interests

The author is not supported by, nor maintains any financial interest in, any commercial activity that may be associated with the topic of this article.

### Correspondence

Address correspondence to Dr. Asai: [asaita@dokkyomed.ac.jp](mailto:asaita@dokkyomed.ac.jp)

### References

1. Cook TM, Woodall N, Frerk C; Fourth National Audit Project: Major complications of airway management in the UK: Results of the Fourth National Audit Project of the Royal College of Anaesthetists and the Difficult Airway Society. Part 1: Anaesthesia. *Br J Anaesth* 2011; 106:617–31
2. Tachibana N, Niiyama Y, Yamakage M: Incidence of cannot intubate-cannot ventilate (CICV): Results of a 3-year retrospective multicenter clinical study in a network of university hospitals. *J Anesth* 2015; 29:326–30
3. Apfelbaum JL, Hagberg CA, Caplan RA, Blitt CD, Connis RT, Nickinovich DG, Hagberg CA, Caplan RA, Benumof JL, Berry FA, Blitt CD, Bode RH, Cheney FW, Connis RT, Guidry OF, Nickinovich DG, Ovassapian A; American Society of Anesthesiologists Task Force on Management of the Difficult Airway: Practice guidelines for management of the difficult airway: An updated report by the American Society of Anesthesiologists Task Force on Management of the Difficult Airway. *ANESTHESIOLOGY* 2013; 118:251–70

4. Frerk C, Mitchell VS, McNarry AF, Mendonca C, Bhagrath R, Patel A, O'Sullivan EP, Woodall NM, Ahmad I; Difficult Airway Society Intubation Guidelines Working Group: Difficult Airway Society 2015 guidelines for management of unanticipated difficult intubation in adults. *Br J Anaesth* 2015; 115:827–48
5. Japanese Society of Anesthesiologists: JSA airway management guideline 2014: To improve the safety of induction of anesthesia. *J Anesth* 2014; 28: 482–93.
6. Aziz MF, Brambrink AM, Healy DW, Willett AW, Shanks A, Tremper T, Jameson L, Ragheb J, Biggs DA, Paganelli WC, Rao J, Epps JL, Colquhoun DA, Bakke P, Kheterpal S: Success of intubation rescue techniques after failed direct laryngoscopy in adults: A retrospective comparative analysis from the Multicenter Perioperative Outcomes Group. *ANESTHESIOLOGY* 2016; 125:656–66.
7. Asai T: Videolaryngoscopes: Do they truly have roles in difficult airways? *ANESTHESIOLOGY* 2012; 116:515–7
8. Asai T, Liu EH, Matsumoto S, Hirabayashi Y, Seo N, Suzuki A, Toi T, Yasumoto K, Okuda Y: Use of the Pentax-AWS in 293 patients with difficult airways. *ANESTHESIOLOGY* 2009; 110:898–904
9. Aziz MF, Dillman D, Fu R, Brambrink AM: Comparative effectiveness of the C-MAC video laryngoscope *versus* direct laryngoscopy in the setting of the predicted difficult airway. *ANESTHESIOLOGY* 2012; 116:629–36
10. Komazawa N, Kido H, Miyazaki Y, Tatsumi S, Minami T: Cricoid pressure impedes tracheal intubation with the Pentax-AWS Airwayscope®: A prospective randomized trial. *Br J Anaesth* 2016; 116:413–6
11. Isono S, Ishikawa T: Oxygenation, not intubation, does matter. *ANESTHESIOLOGY* 2011; 114:7–9
12. Liu EH, Asai T: Cannot intubate cannot ventilate—focus on the ‘ventilate’. *J Anesth* 2015; 29:323–5
13. Kheterpal S, Healy D, Aziz MF, Shanks AM, Freundlich RE, Linton F, Martin LD, Linton J, Epps JL, Fernandez-Bustamante A, Jameson LC, Tremper T, Tremper KK; Multicenter Perioperative Outcomes Group (MPOG) Perioperative Clinical Research Committee: Incidence, predictors, and outcome of difficult mask ventilation combined with difficult laryngoscopy: A report from the Multicenter Perioperative Outcomes Group. *ANESTHESIOLOGY* 2013; 119:1360–9
14. Asai T: Is it safe to use supraglottic airway in children with difficult airways? *Br J Anaesth* 2014; 112:620–2
15. Siddiqui N, Arzola C, Friedman Z, Guerina L, You-Ten KE: Ultrasound improves cricothyrotomy success in cadavers with poorly defined neck anatomy: A randomized control trial. *ANESTHESIOLOGY* 2015; 123:1033–41
16. Asai T: Emergency cricothyrotomy: Toward a safer and more reliable rescue method in “cannot intubate, cannot oxygenate” situation. *ANESTHESIOLOGY* 2015; 123:995–6

## ANESTHESIOLOGY REFLECTIONS FROM THE WOOD LIBRARY-MUSEUM

### From Ferdinand and Courtezan: Shakespearean Ecstasy and Colton Gas



A Shakespearean scholar, New York's G. Q. Colton (1814 to 1898) promoted nitrous oxide as a super-oxygenating and resuscitating stimulant, the recreational use of which contributed to health and even ecstatic happiness. Perhaps laughing gas reminded Colton of characters' quotes from two of Shakespeare's comedies. In *Love's Labour's Lost*, King Ferdinand inquired, "What zeal, what fury hath inspired thee now?" And referring to one of the Antipholus twins (above, from an 1879 Broadway poster) in *The Comedy of Errors*, innkeeper Courtezan exclaimed, "Mark how he trembles in his ecstasy!" Sadly, Colton equated the jactitations and seizures observed with his hypoxic "Colton gas" administrations to ecstatic trembling, which he attributed incorrectly to excessive stimulation by oxygen. (Copyright © the American Society of Anesthesiologists' Wood Library-Museum of Anesthesiology.)

George S. Bause, M.D., M.P.H., Honorary Curator, ASA's Wood Library-Museum of Anesthesiology, Schaumburg, Illinois, and Clinical Associate Professor, Case Western Reserve University, Cleveland, Ohio. UJYC@aol.com.