

Vasculitis and Thrombosis due to the Sea Lion Lungworm, *Parafilaroides decorus*, in a Guadalupe Fur Seal (*Arctocephalus philippii townsendi*)

Mauricio Seguel,^{1,4} Steven Nadler,² Cara Field,³ and Pdraig Duignan³ ¹Department of Pathology, College of Veterinary Medicine, University of Georgia, 501 D. W. Brooks Dr., Athens, Georgia 30602, USA; ²Department of Entomology and Nematology, University of California, Davis, One Shields Ave., Davis, California 95616, USA; ³The Marine Mammal Center, 2000 Bunker Rd., Sausalito, California 94965, USA; ⁴Corresponding author (email: maurseguel@gmail.com)

ABSTRACT: A free-ranging, male, yearling Guadalupe fur seal (*Arctocephalus philippii townsendi*) died due to multifocal verminous vasculitis with thrombosis and several embolic infarcts in liver, kidney, and brain. Nematodes extracted from lung blood vessels were identified as *Parafilaroides decorus*, a parasite normally found in alveoli of California sea lions (*Zalophus californianus*).

Parasitic infections are a common contributory factor of marine mammal strandings worldwide (Colegrove et al. 2005; Lair et al. 2016). In most cases, parasite detrimental effects are a consequence of heavy burden in young animals or concurrent bacterial, fungal, or viral infections (Lair et al. 2016). Host-parasite relationships tend to be relatively stable among marine mammals, although in some circumstances nematodes normally associated with one host species can parasitize a different species with adverse consequences (Colegrove et al. 2005). In marine mammals, the best documented example is *Otostrongylus circumlitus* infection in elephant seals (*Mirounga angustirostris*) and California sea lions (*Zalophus californianus*). This parasite usually inhabits the bronchi of harbor seals (*Phoca vitulina*) but, in elephant seals and California sea lions, the larvae migrate and feed in major blood vessels causing endothelial damage, disseminated intravascular coagulation, multiple hemorrhages, and death (Colegrove et al. 2005; Kelly et al. 2005). Whether or not other species of lungworms are capable of causing aberrant infections in pinnipeds is unknown.

The Guadalupe fur seal (*Arctocephalus philippii townsendi*) is a pinniped species considered to be threatened under the US

Endangered Species Act (Aurioles-Gamboia 2015). In the summer of 2015, the US National Oceanographic and Atmospheric Administration (NOAA) declared an Unusual Mortality Event for Guadalupe fur seals along the south and central California coast (Elorriaga-Verplancken et al. 2016; NOAA 2017). We describe a case of aberrant intravascular *Parafilaroides decorus* infection in a Guadalupe fur seal.

On 26 May 2015, a male, yearling Guadalupe fur seal was found emaciated and lethargic at Natural Bridges State Park (36°57'02"N, 122°03'28"W), Santa Cruz, California, US. The animal was stabilized with fluid therapy and transported to The Marine Mammal Center, Sausalito, California where, after 3 d of supportive care, it was euthanized due to an acute onset of lethargy with later loss of consciousness. A complete necropsy was performed immediately after euthanasia. Sections from major organs and tissues were fixed in 10% buffered formalin and routinely processed for histopathology. Sections of lung, liver, spleen, and brain were frozen (–80 C) for standard fresh tissues archives.

Significant findings at necropsy included diffuse, severe atrophy of fat stores, a well-demarcated light grey area in the right cranial pulmonary lobe, a few well-demarcated dark red areas in the liver, and a few (<20) anisakid nematodes in the stomach. Microscopically, in multiple areas of the lung there was moderate to marked lymphoplasmacytic and eosinophilic arteritis (Fig. 1A) and phlebitis with moderate villous proliferation of the intima and chronic thrombi (Fig. 1B). In approximately half of these lesions,

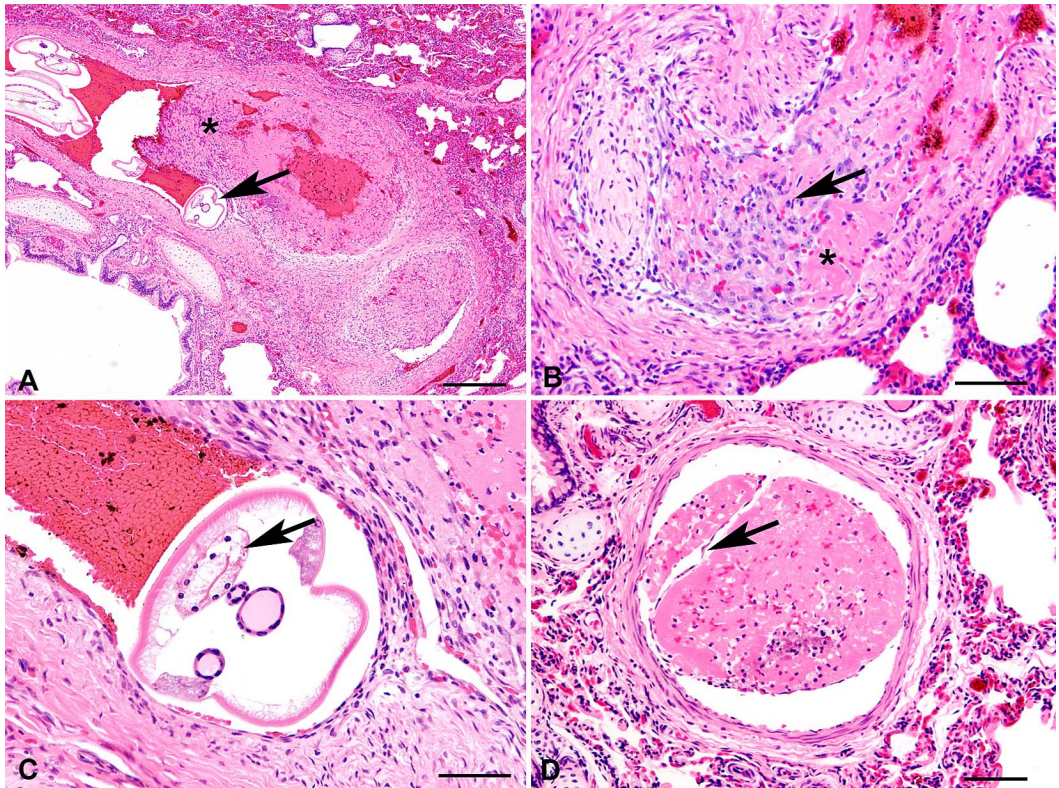


FIGURE 1. Pulmonary vasculitis and thrombosis due to aberrant *Parafilaroides decorus* infection in the lung of a Guadalupe fur seal (*Arctocephalus philippii townsendi*) found stranded on the central California, USA coast in 2015. (A) Lung. Cross sections of intravascular metastrongyle nematodes (arrow) adjacent to a partially organized thrombus (asterisk). H&E. Bar=250 μ m. (B) Lung. Detail of proliferative vasculitis and thrombosis. There is marked proliferation of tunica intima, presence of degenerate leukocytes (arrow), and small areas of necrosis (asterisk). Bar=60 μ m. (C) Higher magnification of a nematode shown in (A). Nematodes have thin cuticle, platymyarian musculature, pseudocoelom and gastrointestinal tract with vacuolated cells (arrow). H&E. Bar=80 μ m. (D) A subacute thrombus in a pulmonary vessel. Note the thin unicellular layer of endothelial cells covering the eosinophilic thrombus (arrow). H&E. Bar=100 μ m.

there were occasional 30–40 μ m cross-sections of metastrongyle nematodes with thin cuticle, platymyarian musculature, pseudocoelom, gastrointestinal tract with vacuolated cells with a small brush border, and an immature reproductive tract (Fig. 1C). In the adjacent pulmonary parenchyma, occasional lymphocytes, plasma cells, and macrophages, with moderately expanded septae and acute thrombi or emboli, partially occluded a few arterioles (Fig. 1D). In a few sections, there were larger diameter nematodes (50–60 μ m) with internal morphology as previously described and a mature reproductive tract with sperm or larvated eggs. In the brain, liver,

and kidney, acute infarcts of small to medium size (up to 20% of the slide) obscured the parenchyma. Adjacent to these areas there were rare, medium-sized blood vessels clogged with eosinophilic homogeneous material (emboli).

A frozen section of lung was thawed at room temperature and examined using a dissecting microscope. Four nematodes were collected from the lung ($n=2$) and pulmonary blood vessels ($n=2$). One adult nematode and three pieces of juvenile nematodes were processed separately for DNA extraction using a commercial kit (Masterpure, Epicentre Technologies, Madison, Wisconsin,

USA). The 5' end of the 28S (large subunit) nuclear ribosomal DNA was amplified by PCR and sequenced using methods described in Carreno and Nadler (2003). The two 28S sequences (GenBank no. MG584860, 955 base pairs) obtained from nematodes infecting the Guadalupe fur seal were 100% identical to each other and to a *Parafilaroides decorus* sequence (GenBank no. AY292802, 942 base pairs) obtained from a California sea lion collected near the central California coast (Marin County). The California sea lion nematodes were morphologically identified as *P. decorus* and vouchers deposited in the US National Parasite Collection (USNPC 92613).

The gross, histologic, and parasitologic findings suggest the Guadalupe fur seal died due to thromboembolism associated with verminous pulmonary vasculitis. The parasite associated with this condition, *P. decorus*, is a common lung nematode of California sea lions. In that species, a heavy burden of *P. decorus* is associated with histiocytic and lymphoplasmacytic pneumonia that sometimes can be complicated by secondary bacterial infections, causing severe bronchopneumonia and death (Fleishman and Squire 1970). However, vasculitis has not been reported in any pinniped species infected by *P. decorus*. There are six fully described *Parafilaroides* species in pinnipeds, and at least three of these infect *Arctocephalus philippii* fur seals (Dailey 2009; Jacobus et al. 2016). In fur seals, all studies on *Parafilaroides* sp. infection describe mild or moderate burdens with minimal inflammatory changes in the lung (Dailey 2009; Jacobus et al. 2016). Therefore, the presentation of intravascular *Parafilaroides* infection in this fur seal is quite unusual and probably related to the presence of a sea lion parasite in an unusual host, similar to the vasculitis with coagulopathy syndrome of elephant seals caused by the harbor seal lungworm, *Otostrongylus circumlitus* (Colegrove et al. 2005).

In 2015 there was a substantial increase in sea surface temperatures in the Pacific coast of the US and Mexico (Elorriaga-Verplancken et al. 2016). This phenomenon was associated

with a decrease in abundance of pelagic fish species in foraging areas of sea lions and Guadalupe fur seals; therefore, pinnipeds changed their diet toward benthopelagic species (Elorriaga-Verplancken et al. 2016). These changes could have caused higher exposure of Guadalupe fur seals to the intermediate host of *P. decorus*, the rudderfish (*Girella nigricans*; Dailey 1970), leading to the presentation of aberrant infections.

The authors thank the Working Group for Marine Mammal Unusual Mortality Events and the Unusual Mortality Event Contingency Fund for supporting the histopathology testing. This work was conducted under National Marine Fisheries Service permit 18786.

LITERATURE CITED

- Auriolos-Gamboa D. 2015. *Arctocephalus townsendi*. In: *The International Union for Conservation of Nature red list of threatened species 2015: eT2061A45224420*. <http://dx.doi.org/10.2305/IUCN.UK.2015-2.RLTS.T2061A45224420.en>. Accessed November 2017.
- Carreno RA, Nadler SA. 2003. Phylogenetic analysis of the Metastrongyloidea (Nematoda: Strongylida) inferred from ribosomal RNA gene sequences. *J Parasitol* 89:965–973.
- Colegrove KM, Greig DJ, Gulland FMD. 2005. Causes of live strandings of northern elephant seals (*Mirounga angustirostris*) and Pacific harbor seals (*Phoca vitulina*) along the central California coast, 1992–2001. *Aquat Mamm* 31:1–10.
- Dailey MD. 1970. The transmission of *Parafilaroides decorus* (Nematoda: Metastrongyloidea) in the California sea lion (*Zalophus californianus*). *Proc Helm Soc Wash* 37:215–222.
- Dailey MD. 2009. A new species of *Parafilaroides* (Nematoda: Filarioididae) in three species of fur seals (Carnivora: Otariidae) from the Southern Hemisphere. *J Parasitol* 95:156–159.
- Elorriaga-Verplancken FR, Sierra-Rodríguez GE, Rosales-Nanduca H, Acevedo-Whitehouse K, Sandoval-Sierra J. 2016. Impact of the 2015 El Niño-southern oscillation on the abundance and foraging habits of Guadalupe fur seals and California sea lions from the San Benito Archipelago, Mexico. *PLoS One* 11:e0155034.
- Fleischman RW, Squire RA. 1970. Verminous pneumonia in the California sea lion (*Zalophus californianus*). *Vet Pathol* 7:89–101.
- Jacobus K, Marigo J, Gastal SB, Taniwaki SA, Ruoppolo V, Catão-Dias JL, Tseng F. 2016. Identification of respiratory and gastrointestinal parasites of three species of pinnipeds (*Arctocephalus australis*, *Arcto-*

- cephalus gazella*, and *Otaria flavescens*) in southern Brazil. *J Zoo Wildl Med* 47:132–140.
- Kelly TR, Greig D, Colegrove KM, Lowenstine LJ, Dailey M, Gulland FM, Haulena M. 2005. Metastrongyloid nematode (*Otostrongylus circumlitus*) infection in a stranded California sea lion (*Zalophus californianus*)—A new host-parasite association. *J Wildl Dis* 41: 593–598.
- Lair S, Measures LN, Martineau D. 2016. Pathologic findings and trends in mortality in the beluga (*Delphinapterus leucas*) population of the St. Lawrence Estuary, Quebec, Canada, from 1983 to 2012. *Vet Pathol* 53:22–36.
- NOAA (National Oceanographic and Atmospheric Administration). 2017. 2015–2018 Guadalupe fur seal unusual mortality event in California. <http://www.nmfs.noaa.gov/pr/health/mmume/guadalupefurseals2015.html>. Accessed November 2017.
- Submitted for publication 30 November 2017.
Accepted 30 January 2018.