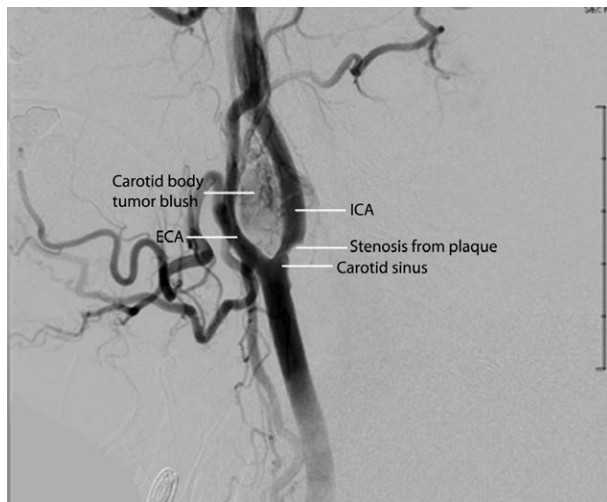


Carotid Body Paraganglioma

A Rare Tumor with Serious Anesthetic Challenges

Angela T. Truong, M.D., Sudip Thakar, B.S., Dam-Thuy Truong, M.D.



THIS carotid angiogram investigating a neck mass shows a 4×3 cm tumor splaying the carotid bifurcation (lyre sign), typical of a carotid body paraganglioma. This rare tumor has a reported incidence of 1 to 2 per 100,000.¹ Encasing the internal carotid artery (ICA) and the carotid sinus, it receives numerous branches from the external carotid artery (ECA), resulting in a dense tumor blush. A second lesion, an atheromatous plaque, is noted, causing a 70% stenosis of the ICA.

From these findings, several perioperative anesthetic implications² can be anticipated during resection. First, because a carotid body paraganglioma is a neuroendocrine tumor, release of catecholamines or association with a pheochromocytoma should be suspected. Endocrine evaluation will determine if preoperative α -blockade is needed to prevent intraoperative hypertensive crises. The tumor blush from the neoplastic vascular proliferation is indicative of an increased risk of profuse hemorrhage. Consequently, tumor biopsy is contraindicated. Preoperative tumor embolization

should be considered³ and the need for rapid blood transfusion anticipated. The ICA plaque may lead to cerebrovascular accidents by obstruction of cerebral blood flow and by embolic stroke from plaque dislodgement during ICA dissection. Finally, tumor invasion may lead to carotid sinus hypersensitivity, and carotid sinus manipulation may precipitate severe bradycardia.

Considering the conjunction of risks from the two problems (carotid body paraganglioma and carotid plaque) noted on this image, cardiac output monitoring, electroencephalography, and cerebral oximetry are indicated. As carotid body paraganglioma resection may result in baroreceptor and chemoreceptor dysfunction, postoperative monitoring enables detection of hemodynamic instability and abnormal response to hypoxia.

Competing Interests

All authors have had no conflicts of interest within the 36 months of submission.

Correspondence

Address correspondence to Dr. A. T. Truong: atruong@mdanderson.org

References

1. Sevilla García MA, Llorente Pendás JL, Rodrigo Tapia JP, García Rostán G, Suárez Fente V, Coca Pelaz A, Suárez Nieto C: Head and neck paragangliomas: Revision of 89 cases in 73 patients. *Acta Otorrinolaringol Esp* 2007; 58:94–100
2. Jagtap SR, Bakhshi RG, Khatavkar SS, Phadtare SJ, Mohite SN: Carotid body tumour excision: Anaesthetic challenges and review of literature. *Indian J Anaesth* 2013; 57:76–8
3. Jackson RS, Myhill JA, Padhya TA, McCaffrey JC, McCaffrey TV, Mhaskar RS: The effects of preoperative embolization on carotid body paraganglioma surgery: A systematic review and meta-analysis. *Otolaryngol Head Neck Surg* 2015; 153:943–50

From the Department of Anesthesiology and Perioperative Medicine (A.T.T., D.-T.T.) and Department of Plastic Surgery (S.T.), University of Texas MD Anderson Cancer Center, Houston, Texas.

Copyright © 2017, the American Society of Anesthesiologists, Inc. Wolters Kluwer Health, Inc. All Rights Reserved. *Anesthesiology* 2017; 126:1170