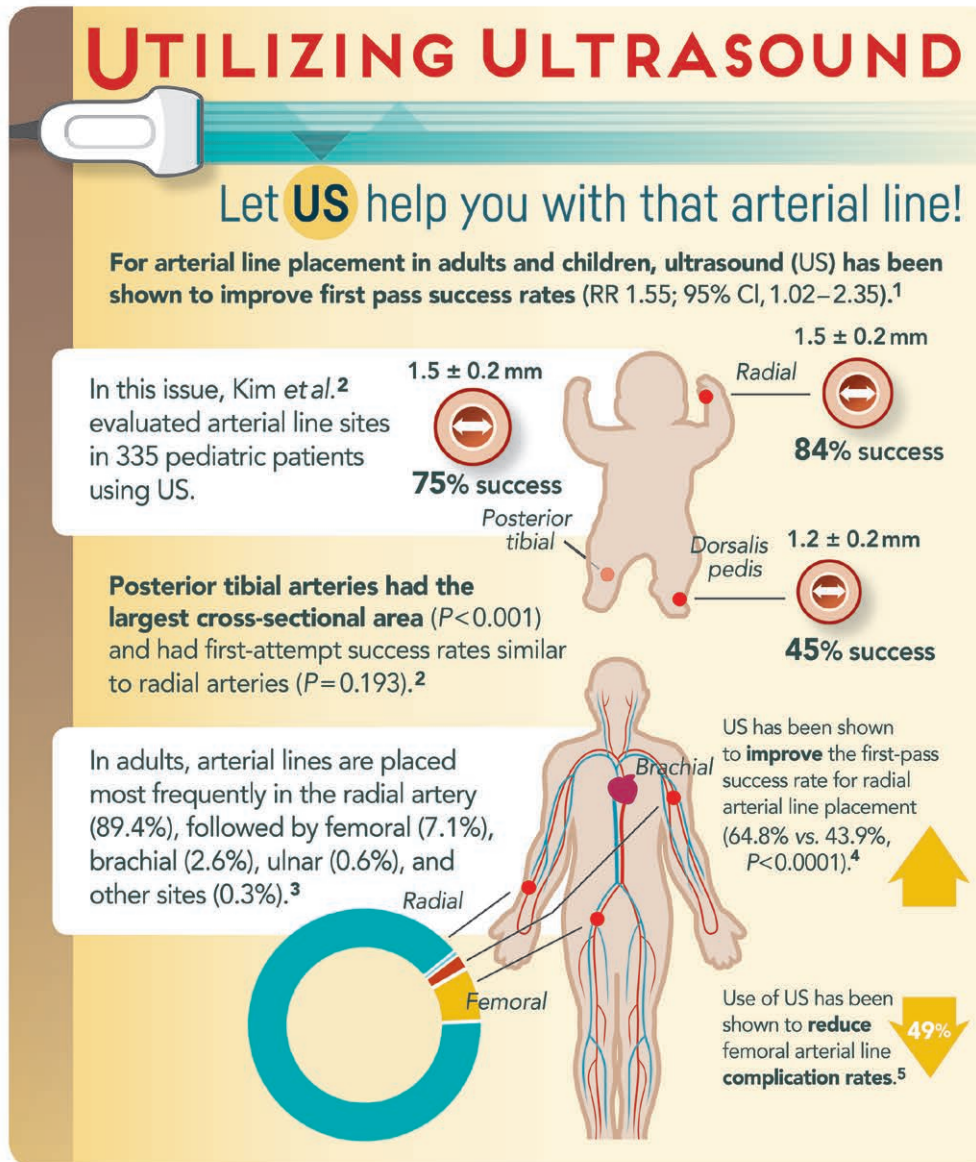


ANESTHESIOLOGY



RR = relative risk.

Infographic created by Jonathan P. Wanderer, Vanderbilt University Medical Center, and James P. Rathmell, Brigham and Women's Health Care/Harvard Medical School; illustration by Annemarie Johnson, Vivo Visuals. Address correspondence to Dr. Wanderer: jonathan.p.wanderer@vanderbilt.edu.

- Gu WJ, Tie HT, Liu JC, Zeng XT, Yuill G, Amroyan A, Millar S, Vardapetyan E, Habib AS, Owen MD: Efficacy of ultrasound-guided radial artery catheterization: A systematic review and meta-analysis of randomized controlled trials. *Crit Care* 2014; 18:R93
- Kim E-H, Lee J-H, Song I-K, Kim J-T, Lee W-J, Kim H-S: The posterior tibial artery as an alternative to the radial artery for arterial cannulation site in small children: A randomized controlled study. *ANESTHESIOLOGY* 2017; 127:423–31
- Nuttall G, Burckhardt J, Hadley A, Kane S, Kor D, Marienau MS, Schroeder DR, Handlogten K, Wilson G, Oliver WC: Surgical and patient risk factors for severe arterial line complications in adults. *ANESTHESIOLOGY* 2016; 124:590–7
- Seto AH, Roberts JS, Abu-Fadel MS, Czak SJ, Latif F, Jain SP, Raza JA, Mangla A, Panagopoulos G, Patel PM, Kern MJ, Lasic Z: Real-time ultrasound guidance facilitates transradial access: RAUST (Radial Artery access with Ultrasound Trial). *JACC Cardiovasc Interv* 2015; 8:283–91
- Sobolev M, Slovut DP, Lee Chang A, Shiloh AL, Eisen LA: Ultrasound-guided catheterization of the femoral artery: A systematic review and meta-analysis of randomized controlled trials. *J Invasive Cardiol* 2015; 27:318–23