

Management of Polyarthrititis Affecting Sea Turtles at Kélonia, the Reunion Island Sea Turtle Observatory (2013–17)

Benôit Cruciani,^{1,5} Francis Shneider,² Stéphane Ciccione,³ Mathieu Barret,³ Pascal Arné,⁴ Henri-Jean Boulouis,⁴ and Claire Vergneau-Grosset¹ ¹Faculté de Médecine Vétérinaire, Université de Montréal, 3200 Rue Sicotte, Saint-Hyacinthe, Québec, J2S 2M2, Canada; ²Clinique Vétérinaire VETORUN, 1 Allée de la Desserte Zone Industrielle N 2, 97410 Saint-Pierre, La Réunion, France; ³Kélonia, l'Observatoire des Tortues Marines, 46 Rue du Général de Gaulle, 97436 Saint-Leu, La Réunion, France; ⁴École Nationale Vétérinaire d'Alfort, Université Paris-Est, 7 Avenue du Général de Gaulle, 94700 Maisons-Alfort, France; ⁵Corresponding author (email: benoitcruciani@gmail.com)

ABSTRACT: All sea turtle species are listed on the Red List of the International Union for the Conservation of Nature due to multiple threats. Among these, disease is a frequent cause of stranded sea turtles encountered in rehabilitation centers. Since 2013, we found joint swelling in 13 sea turtles belonging to all four sea turtle species submitted to the Kélonia Sea Turtle Observatory of Reunion Island, France. Affected sea turtles presented with lameness, anorexia, and lethargy. Polyarthrititis was radiographically confirmed and lesions were characterized by progressive osteolysis of bones surrounding joints. Anterior flippers were affected in all cases and posterior flippers were also involved in some cases. We isolated several bacterial agents from blood and synovial fluid. We attempted a collective treatment with injectable florfenicol, based on sensitivity results, which was continued for 4 wk and then as needed based on radiographic evolution of the lesions. Radiographic stabilization of the lesions occurred in nine of 13 cases. We reviewed environmental conditions and optimized them to minimize stress that could predispose these rehabilitated sea turtles to opportunistic infections. Handling techniques used to move sea turtles were also improved. While we can make no conclusion regarding the cause of polyarthrititis in this population of sea turtles, we successfully managed this poorly described problem in a rehabilitation setting.

Key words: Antibiotic, arthritis, bacterium, captivity, osteomyelitis, Reunion Island, sea turtle.

All sea turtle species are currently on the Red List of the International Union for Conservation of Nature (IUCN; <http://www.iucnredlist.org/>). Septic arthritis has been reported in captive (Harms et al. 2002; Greer et al. 2003; Innis et al. 2014) and wild (Raidal et al. 2006; Guthrie et al. 2010) sea turtles involving *Mycobacterium chelonae* (Greer et al. 2003), *Enterococcus* (Innis et al. 2014), *Nocardia* (Harms et al. 2002), *Streptococcus*

(Guthrie et al. 2010), *Acinetobacter*, and *Staphylococcus* (Solano et al. 2008). While most cases have occurred in stranded or cold-stunned individuals, it is difficult to determine whether osteolytic lesions were the cause or consequence of stranding (Innis et al. 2009).

Kélonia is a rehabilitation center located on the French island of Reunion (21°6'S, 55°32'E) in the Indian Ocean east of Madagascar. Four sea turtle species, the loggerhead (*Caretta caretta*), hawksbill (*Eretmochelys imbricata*), olive ridley (*Lepidochelys olivacea*), and green (*Chelonia mydas*), have been admitted to the center since the 1980s. We detected 13 cases of osteolysis from January 2013 to March 2017 (Table 1). Initial management included empirical antibiotic treatment and dexamethasone 0.45 mg/kg intramuscularly (IM) every 15 d for three to four doses (Dexafort®, MSD Animal Health, Milton Keynes, UK). A systematic review of captive conditions, including water quality, nutrition, temperature, the tank occupied by the sea turtles, and biosecurity measures, did not highlight any major problem.

Affected sea turtles presented with articular swelling (11/13) or were incidentally diagnosed on screening radiographs (2/13). Skin wounds were often observed (10/13) and these were sometimes near affected joints. Other clinical signs observed were decreased appetite (10/13), decreased mobility (9/13), weight loss (6/13), lethargy (5/13), and buoyancy disorders (3/13). Whenever joint swelling was noted, we acquired a single dorsoventral radiographic view of each affected joint within a week and once a month thereafter (Ecoray Orange 1060 HF generator, Seoul, South Korea). Subchondral bone with heteroge-

TABLE 1. Species, age distribution, and time between arrival and osteolysis detection in four species of sea turtles affected by polyarthritis at Kélonia, the Reunion Island Sea Turtle Observatory, from January 2013 to March 2017.

Species	Immature	Mature	Median time between arrival and osteolysis detection (min-max in months)
<i>Caretta caretta</i>	4	0	7.5 (2–11)
<i>Chelonia mydas</i>	3	1	63.5 (34–329)
<i>Eretmochelys imbricata</i>	2	0	14.5 (6–23)
<i>Lepidochelys olivacea</i>	3	0	19 (1–31)

neous decreased bone opacity was noted, compatible with osteolysis (Fig. 1). Radiographic changes were of variable severity and one to four joints were affected for each of the individuals (Table 2). Anterior flippers were always affected and the elbow was also affected in 10/13 cases.

We collected blood samples from the dorsal cervical venous sinus of 9/13 cases, and hematology and serum biochemistry were submitted. There was no correlation between abnormal clinical pathology results and joint lesions except for increased white blood cell count in 3/9 individuals at 55.6, 70.9, and 85.1×10^9 cells/L, respectively (Flint et al. 2010).

We did arthrocentesis (2/13) and performed aerobic and anaerobic bacterial cultures of the aspirated fluid on blood agar, xylose-lysine-tergitol 4 agar, and bromocresol purple lactose agar at 25 C. Synovial fluid cultures were negative except one culture that grew *Morganella morganii* which was suscep-

TABLE 2. Distribution of joints affected by arthritis (in decreasing prevalence) in sea turtles at Kélonia, the Reunion Island Sea Turtle Observatory, from January 2013 to March 2017.

Joint	No. of affected joints	No. of affected individuals
Elbow	13	10/13
Stifle	4	3/13
Carpus, metacarpus, and interphalangeal joint	16	3/13
Shoulder	3	2/13

tible to florfenicol. Blood cultures were performed in 9/13 cases. Following aseptic collection, blood was placed in a peptone water tube and cultured at 25 C. The culture media used were colistin-nalidixic acid agar under a carbon dioxide-enriched atmosphere and bromocresol purple lactose agar. Blood cultures results are presented in Table 3. Overall, 10/13 affected animals received florfenicol 15 mg/kg IM once daily for at least 1 mo, then as needed based on radiographic re-evaluations (Shotaflor® Virbac, Leuven, Belgium; then Florkem® Ceva Santé Animale, Libourne, France). Dexamethasone was replaced by meloxicam (0.2 mg/kg IM once every 48 h for 10–15 d; Metacam®, Boehringer Ingelheim, Ingelheim am Rhein, Germany). Physical therapy and general supportive care were also performed including force-feeding two to three times a week.

Necropsies were performed in all deceased sea turtles (3/13). Samples of lungs, liver, kidney, and small intestine were fixed in formalin in addition to bones and peripheral muscles in two of three cases. Tissues were embedded in paraffin, sectioned at 5 μ m, and stained with hemalun-erythrosine-safran, Fite-Faraco, and periodic acid-Schiff stains. On gross necropsy, purulent discharge was found in the affected joints as well as in the adjacent muscles and bones. Histologically, a hyperacidophilic center was surrounded by activated epithelioid macrophages, heterophils, and lymphoplasmocytic cells without detectable bacterial or fungal elements. However, these histopathologic findings were consistent with an infectious etiology (Ogden

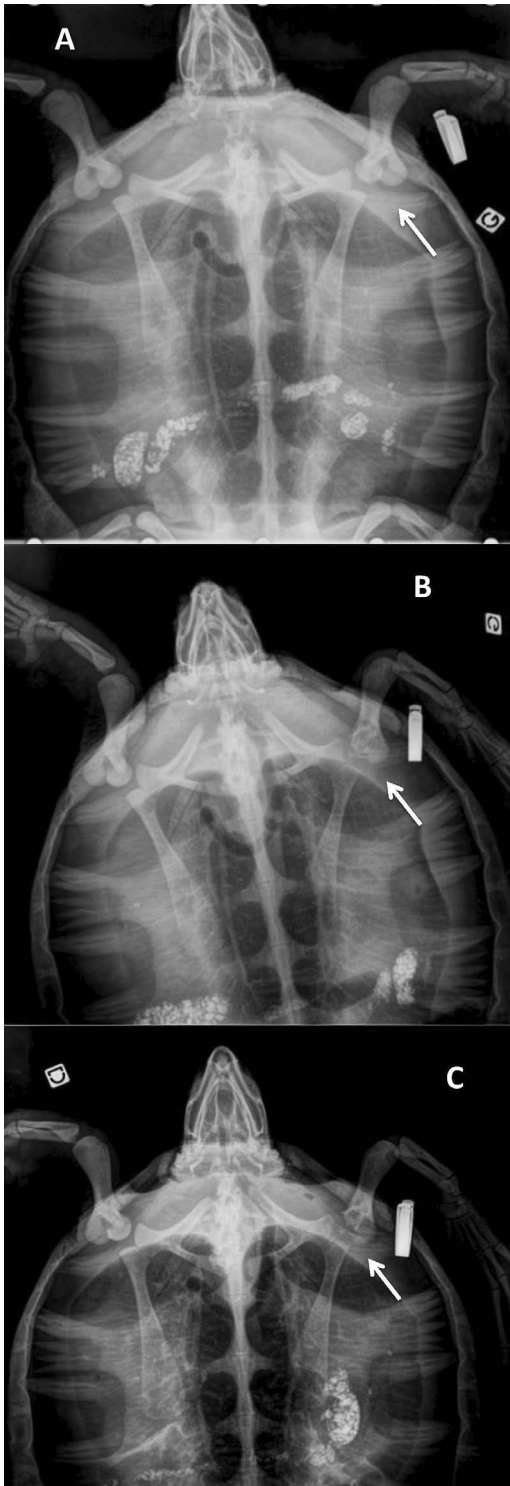


FIGURE 1. Dorsoventral radiographs showing the left scapulo-humeral joint of a hawksbill turtle (*Eretmochelys imbricata*) that developed arthritis at

et al. 1981). Disseminated multifocal pneumonia lesions including Gram-positive bacilli were also observed in two sea turtles. Death was attributed to septicemia in the first two cases and to trauma in the third.

Bone lesions resolved radiographically in the 10 remaining individuals. We observed sclerosis of the osteolytic region boundaries and improvement of bone density (Fig. 2), compatible with healing of osteomyelitis, as described by Solano et al. (2008). In May 2018, three individuals were released and seven were still in rehabilitation. Among these seven turtles, we expected that five would be releasable but the other two had a more-guarded prognosis.

Given the time lag between admission and diagnosis, we suspected that the disease started in captivity in at least nine individuals. In these cases, we hypothesized that stress associated with rehabilitation led to immune suppression favoring septic arthritis development. We confirmed bacteremia in 4/13 cases by blood culturing. However, the overall positive response to treatment which included broad spectrum antibiotics did not necessarily point toward a primary bacterial etiology, as this response could also have been due to meloxicam administration, dexamethasone discontinuation, and supportive care. In addition, it is unlikely that the short duration of treatment (4 wk) was sufficient to successfully treat osteomyelitis lesions even if it was sometimes extended for an additional 1–2 mo. Indeed, although there is no established duration for septic arthritis or osteomyelitis in mammals, a treatment of 4 wk to 3 mo is generally recommended (Mathews et al. 2010), and sea turtles are likely to benefit from longer treatments. It would have been ideal to keep a control group to ascertain

the Reunion Island Sea Turtle Observatory. (A) Appearance of the bones at the first swelling observation. (B) Follow-up 2 mo later: loss of bone density and remodeling of the left humeral proximal epiphysis (arrow). (C) Follow-up 5 mo later: complete lysis of the humeral head and lysis of the scapula cavity.

TABLE 3. Bacterial blood culture results of nine sea turtles at Kélonia, the Reunion Island Sea Turtle Observatory, which presented with osteolysis from July 2015 to November 2016.^a

Species ^b	2015				2016			
	July	January	February	April	July	August	September	November
Cc	Negative	—	—	—	—	—	—	—
Cc	Negative	—	—	—	—	—	—	—
Cc	<i>Morganella morganii</i>	—	Negative	—	—	—	—	—
Cm	Negative	—	—	—	—	—	—	—
Cm	—	—	—	—	Negative	Negative	Negative	—
Cm	—	Negative	—	—	—	—	—	—
Lo	Negative	—	—	Negative	<i>Proteus vulgaris</i>	—	—	—
Lo	—	—	—	<i>Enterococcus faecalis</i>	Negative	—	Negative	—
Lo	—	—	—	—	—	—	—	<i>Staphylococcus xylosum</i> and <i>Pantoea</i> spp.

^a — = not tested.

^b Cc = *Caretta caretta*; Cm = *Chelonia mydas*; Lo = *Lepidochelys olivacea*.

treatment efficacy but this was not possible in a rehabilitation setting.

Another predisposing factor could have been that sea turtles were usually handled and moved by the anterior flippers for tank cleaning or treatment. Handling frequency varied from twice a week in maintenance to several times a day for turtles under intensive care. This could contribute to causing unusual mechanical stress and inflammation of the forelimb joints (Guilak 2011). Less-traumatic handling techniques, such as using a stretcher or plastic container for transport, were recommended after the occurrence of these cases.

Whether polyarthritis affects mostly immature individuals is questionable even though most of our cases were detected in juveniles. Indeed, there was a strong selection bias, as only five of 250 sea turtles admitted to Kélonia rehabilitation center between 2009 and 2017 were adults.

Despite the low sensitivity of synovial fluid culture (Solano et al. 2008), *Morganella morganii* and other bacteria were isolated from blood and synovial fluid cultures of two turtles. Of note, arthritis lesions associated with *M. morganii* have been reported in a

crocodile (Heard et al. 1988). Postmortem lesions suggested a role for hematogenous bacterial spread. Innis et al. (2014) reported that sea turtles became bacteremic under chronic stress. We suspect that no single etiologic agent caused the lesions in our case series. Instead, various opportunistic agents might have been involved, and the positive response attributed to florfenicol could have been due to its wide spectrum of activity, to the discontinuation of dexamethasone, and to the improvement of handling techniques. In general, our recommendation is to base antibiotic choice on individual antimicrobial susceptibility tests.

In sea turtles, antibiotic doses are often extrapolated from pharmacokinetic studies conducted in mammals (Stamper et al. 2003). Intramuscular doses of florfenicol higher than 30 mg/kg have been recommended in sea turtles. This recommendation was based on the treatment of only two juveniles with high interindividual variability. The rapid drug clearance observed by Stamper et al. (2003) was unexpected because most drugs have a slower clearance in reptiles than in mammals. For instance, in green sea turtles, chloramphenicol, an antibiotic belonging to

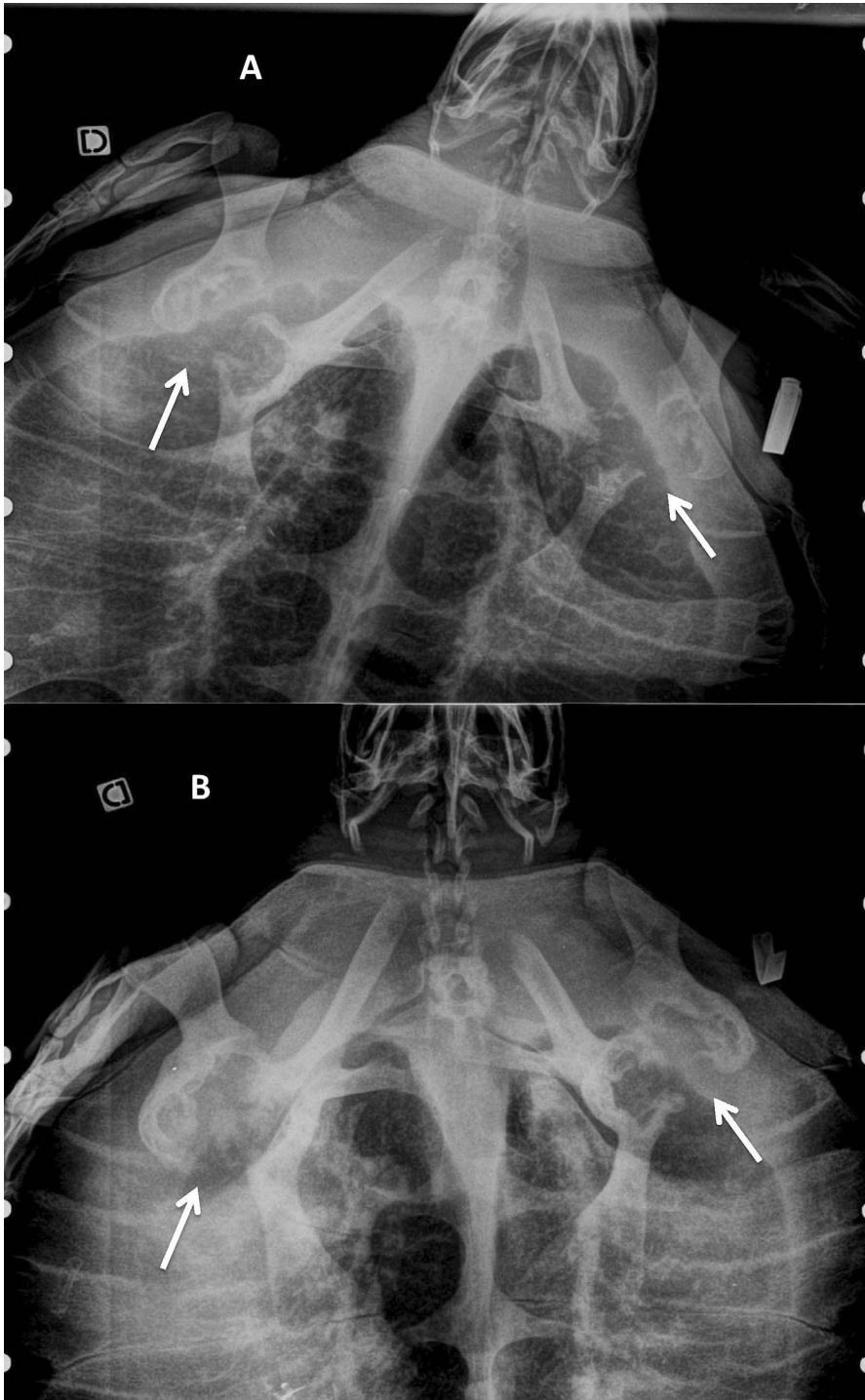


FIGURE 2. Dorsoventral radiographs showing the scapulo-humeral joints of an olive ridley turtle (*Lepidochelys olivacea*) that developed arthritis at the Reunion Island Sea Turtle Observatory. (A) Severe lysis of bilateral shoulders (humerus and scapulae) during antibiotic therapy. (B) Follow-up after 2.5 yr of treatment: sclerosis of the osteolytic region boundaries and improvement of bone density, especially of the left scapula.

the same drug family as florfenicol, has a clearance much lower than in dogs (Stamper et al. 2003; Norton and Walsh 2012). Stamper et al. (2003) suggested that lymph contamination of a blood sample could have affected measured florfenicol concentrations. In cattle (*Bos taurus*), synovial florfenicol concentration is higher for a longer duration than is plasmatic concentration after parenteral administration (Jones et al. 2015). Ideally, an experimental study should be conducted to ascertain the in vivo effect of florfenicol following experimental joint infection in sea turtles. The Stamper et al. (2003) study involved only juvenile loggerhead turtles averaging 1.25 kg while sea turtles from our study ranged from 3.9 to 109.1 kg and belonged to various species. A pharmacokinetic study conducted in older specimens of various sea turtle species would be needed to determine whether the dose used in our study was appropriate.

Dexamethasone is part of the treatment of immune-mediated polyarthritis in dogs (Johnson and Mackin 2012). As glucocorticoids are contraindicated in cases of septic arthritis, we substituted meloxicam for dexamethasone to manage pain without impacting the patient's immune status. The dose we elected was extrapolated from green iguanas (*Iguana iguana*; Divers et al. 2010) and was based on recommended doses higher than 0.1 mg/kg in sea turtles (Lai et al. 2015).

While polyarthritis etiology is elusive in sea turtles, the favorable outcome of most individuals in our study was deemed worth reporting. Although experimental studies in controlled environments are warranted in sea turtles, field reports may also carry some value to evaluate treatment efficacy in clinical situations.

This study was funded by the Kélonia Care and Rehabilitation Center with the support of the Association Française des Vétérinaires de Parcs Zoologiques (AFVPZ).

LITERATURE CITED

- Divers SJ, Papich M, McBride M, Stedman NL, Perpignan D, Koch TF, Hernandez SM, Barron GH, Pethel M, Budsberg SC. 2010. Pharmacokinetics of meloxicam following intravenous and oral administration in green iguanas (*Iguana iguana*). *Am J Vet Res* 71:1277–1283.
- Flint M, Morton JM, Limpus CJ, Patterson-Kane JC, Mills PC. 2010. Reference intervals for plasma biochemical and hematologic measures in loggerhead sea turtles (*Caretta caretta*) from Moreton Bay, Australia. *J Wildl Dis* 46:731–741.
- Greer LL, Strandberg JD, Whitaker BR. 2003. *Mycobacterium chelonae* osteoarthritis in a Kemp's ridley sea turtle (*Lepidochelys kempii*). *J Wildl Dis* 39:736–741.
- Guilak F. 2011. Biomechanical factors in osteoarthritis. *Best Pract Res Clin Rheumatol* 25:815–823.
- Guthrie A, George J, Demaar TW. 2010. Bilateral chronic shoulder infections in an adult green sea turtle (*Chelonia mydas*). *J Herpetol Med Surg* 20:105–108.
- Harms CA, Lewbart GA, Beasley J. 2002. Medical management of mixed nocardial and unidentified fungal osteomyelitis in a Kemp's ridley sea turtle (*Lepidochelys kempii*). *J Herpetol Med Surg* 12:21–26.
- Heard DJ, Jacobson ER, Clemmons RE, Campbell GA. 1988. Bacteremia and septic arthritis in a West African dwarf crocodile. *J Am Vet Med Assoc* 192:1453–1454.
- Innis C, Nyaoke AC, Williams CR III, Dunnigan B, Merigo C, Woodward DL, Weber ES, Frasca S Jr. 2009. Pathologic and parasitologic findings of cold-stunned Kemp's ridley sea turtles (*Lepidochelys kempii*) stranded on Cape Cod, Massachusetts, 2001–2006. *J Wildl Dis* 45:594–610.
- Innis CJ, Braverman H, Cavin JM, Ceresia ML, Baden LR, Kuhn DM, Frasca S Jr, McGowan JP, Hirokawa K, Weber ES III, et al. 2014. Diagnosis and management of *Enterococcus* spp. infections during rehabilitation of cold-stunned Kemp's ridley turtles (*Lepidochelys kempii*): 50 cases (2006–2012). *J Am Vet Med Assoc* 245:315–323.
- Johnson KC, Mackin A. 2012. Canine immune-mediated polyarthritis: Part 2: Diagnosis and treatment. *J Am Anim Hosp Assoc* 48:71–82.
- Jones ML, Washburn KE, Fajt VR, Rice S, Coetzee JF. 2015. Synovial fluid pharmacokinetics of tulathromycin, gamithromycin and florfenicol after a single subcutaneous dose in cattle. *BMC Vet Res* 11:26.
- Lai OR, Di Bello A, Soloperto S, Freggi D, Marzano G, Cavaliere L, Crescenzo G. 2015. Pharmacokinetic behavior of meloxicam in loggerhead turtles (*Caretta caretta*) after intramuscular and intravenous administration. *J Wildl Dis* 51:509–512.
- Mathews CJ, Weston VC, Jones A, Field M, Coakley G. 2010. Bacterial septic arthritis in adults. *Lancet* 375:846–855.
- Norton TM, Walsh MT. 2012. Sea turtle rehabilitation. In: *Zoo and wild animal medicine, current therapy*, 7th Ed., Miller RE, Fowler ME, editors. Elsevier, St. Louis, Missouri, pp. 239–246.
- Ogden JA, Rhodin AGJ, Conlogue GJ, Light TR. 1981. Pathobiology of septic arthritis and contiguous osteomyelitis in a leatherback turtle (*Dermochelys coriacea*). *J Wildl Dis* 17:277–287.

- Raidal SR, Shearer PL, Prince RIT. 2006. Chronic shoulder osteoarthritis in a loggerhead turtle (*Caretta caretta*). *Aust Vet J* 84:231–234.
- Stamper MA, Papich MG, Lewbart GA, May SB, Plummer DD, Stoskopf MK. 2003. Pharmacokinetics of florfenicol in loggerhead sea turtles (*Caretta caretta*) after single intravenous and intramuscular injections. *J Zoo Wildl Med* 34:3–8.
- Solano M, Innis C, Smith C, Merigo C, Weber ES III. 2008. Scintigraphic and radiographic evaluation of appendicular skeletal lesions in cold-stunned Kemp's ridley sea turtles. *Vet Radiol Ultrasound* 49:388–394.

Submitted for publication 16 April 2018.

Accepted 6 July 2018.