

Pyometra Caused by *Staphylococcus lentus* in a Wild European Hedgehog (*Erinaceus europaeus*)

Andreia Garcês,^{1,6,7} Patrícia Poeta,^{1,2,6} Vanessa Soeiro,³ Sara Lóio,³ Anícia Cardoso-Gomes,¹ Carmén Torres,⁴ and Isabel Pires^{1,5} ¹Department of Veterinary Sciences, University of Trás-os-Montes and Alto Douro, Quinta de Prados 5000-801, Vila Real, Portugal; ²Laboratório Associado for Green Chemistry, New University of Lisbon, 2829-516, Caparica, Portugal; ³Wildlife Rehabilitation Centre of Parque Biológico de Gaia, R. Cunha, 4430-681, Avintes, Portugal; ⁴Área de Bioquímica y Biología Molecular, Universidad de La Rioja, Avda. de La Paz 93-103, 26006 Logroño, Spain; ⁵Veterinary and Animal Research Center, University of Trás-os-Montes and Alto Douro, Quinta de Prados 5000-801, Vila Real, Portugal; ⁶These authors contributed equally to this study; ⁷Corresponding author (email: andreiamvg@gmail.com)

ABSTRACT: A severely debilitated, free-living adult female European hedgehog (*Erinaceus europaeus*) was presented for rehabilitation. It died overnight, and postmortem examination revealed a closed pyometra. Histopathology confirmed metritis with endometrial hyperplasia, and *Staphylococcus lentus* was isolated from the purulent uterine material. *Staphylococcus lentus* has not been previously reported to cause infections in European hedgehogs.

The European hedgehog (*Erinaceus europaeus*) is a common wild mammal widely distributed in Europe. It is seasonally polyestrous from March until September. Gestation lasts approximately 35 d, with births occurring from May to October (Reeve 2002; Harris and Yalden 2008).

A free-living adult female was admitted to the Wildlife Rehabilitation Center of Parque Biológico de Gaia, Avintes, Portugal, in August 2015, after being found in a suburban area during the day, suffering hypothermia, malnourishment, and making slow, uncoordinated movements. On examination, the hedgehog weighed 640 g, had poor body condition (with scarce subcutaneous and intra-abdominal fat confirmed at postmortem examination), and was dehydrated. Initial first aid procedures consisted of warming with a heat lamp, subcutaneous fluid therapy, and twice daily intramuscular antibiotics (enrofloxacin, 10–20 mg/kg). Unfortunately, the animal died during the night.

The postmortem examination was carried out on the next day, according to the techniques described for mammals and under the appropriate conditions of safety and hygiene (Garcês and Pires 2017). On external

exam, the animal presented with pallid mucosa and dirty and damaged fur, with the presence of some fleas. On internal exam, we observed an enlarged uterus and a large volume of ascitic fluid that occupied half of the volume of the abdominal cavity. The uterus had a distention of 5×2 cm of the body and 0.5 cm of lumen diameter of the uterine horns. The uterine wall was thickened and had a heterogeneous coloration with necrotic, ulcerated, and hemorrhagic areas (Fig. 1). The lumen of the uterus contained 1.5 mL of whitish purulent exudate. The cervix was closed without gross evidence of a tumor or other lesions. The lungs failed to collapse on the opening of the thoracic cavity and were diffusely swollen and wet, with a heterogeneous coloration and pallid and consolidate reddish areas in the anterior ventral region. Microscopically, the pulmonary parenchyma had scattered, whitish, and firm nodules less than 2 mm. The heart, kidney, and liver were congested. Adrenal glands were slightly enlarged in size. There was an absence of food content in the lumen of the stomach that contained mucus. The intestine had bloated segments and congestion of the mesenteric veins. There were no visible lesions in the remaining internal organs.

Sections of lung, heart, spleen, kidney, liver, uterus, stomach, small intestine, urinary bladder, and adrenal glands were fixed in 10% neutral buffered formalin, embedded in paraffin, sectioned at 3 µm, and stained with H&E for histologic examination. Histologic findings included the following: mucosal



FIGURE 1. A free-living adult female European hedgehog (*Erinaceus europaeus*) admitted to the Wildlife Rehabilitation Center of Parque Biológico de Gaia, Avintes, Portugal, in August 2015 because of hypothermia, malnourishment, and slow, uncoordinated movements. Macroscopic lesions observed in necropsy include ascites and uterine distention due to pyometra. After being retracted caudally, the uterus measured 5×2 cm of the body and 0.5-cm diameter in the uterine horns, containing purulent exudate.

hyperplasia and inflammatory infiltrates (neutrophils, macrophages, and lymphocytes) on the uterine lamina propria (Fig. 2); granulomatous pneumonia with inflammatory infiltrate of macrophages, giant cells, and septic

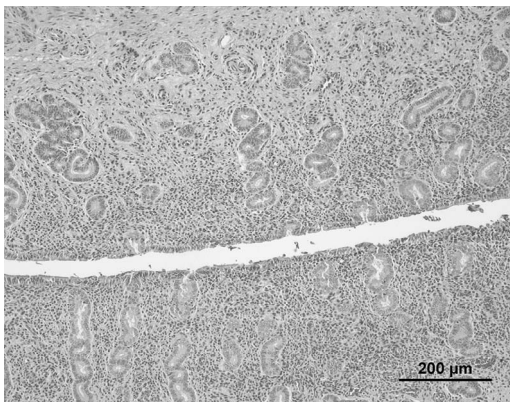


FIGURE 2. A free-living adult female European hedgehog (*Erinaceus europaeus*) admitted to the Wildlife Rehabilitation Center of Parque Biológico de Gaia, Avintes, Portugal, in August 2015 because of hypothermia, malnourishment, and slow, uncoordinated movements. Microscopic image from the uterus with hyperplasia of the uterine mucosa and inflammatory infiltrate in the lamina propria—metritis. Bar=200 μ m. H&E stain.

foci, and parasitic bronchitis; hepatic congestion, focal interstitial nephritis, splenic extramedullary hematopoiesis, and lymphoid reactivity; and bilateral diffuse hyperplasia of adrenal medulla.

Samples of purulent material from the uterus and heart blood were cultured aerobically on brain heart infusion (BHI) agar, blood BHI (5% sheep [*Ovis aries*] blood) agar, and MacConkey agar at 37 C for 24 h. Primary identification of bacterial strains was based on colony morphology, hemolysis, Gram staining, and biochemical tests. We observed Gram-positive, nonmotile, nonsporulating cocci occurring singly, in pairs, and in irregular clusters. On the blood BHI, we observed a pure heavy growth of round, raised, white, and creamy colonies of 1- to 2-mm diameter. The results of the biochemical tests were oxidase positive, mannitol positive, catalase positive, and coagulase production negative. On the basis of these results, we classified the isolates as coagulase-negative staphylococci. Also, PCR was performed on DNA obtained from the isolated bacteria by using primers specific for the 16S ribosomal (r)RNA gene. The universal primers (forward primer 5'-AGAGTTT-GATCCTGGCTCAG-3' and reverse primer 5' CTTGTGCGGGCCCCCGTCAATTC-3') were used for the amplification of the 16S rRNA gene fragment. Sequencing of the products and a search in the GenBank database revealed 99% of identity with *S. lentus* (accession no. KY992550.1). This is a commensal bacterium from animal skin and mucosal surfaces of various animals and has commonly been isolated from food-producing animals (Huber et al. 2011; Schwendener and Perreten 2012). This bacterium has been associated with subclinical mastitis in goats (*Capra aegagrus hircus*) and sheep and rarely with clinical infections in humans (Huber et al. 2011).

Pyometra is an acute or chronic inflammation of the uterus with an accumulation of purulent exudate in the lumen and consequent distension of the uterine wall and volume increase. Depending on the state of the cervix, pyometra could be classified as open or closed. In most cases, it is the

sequelum of an endometritis or metritis (Foster 2017). This lesion is described in a variety of mammals (McCain et al. 2009; Hueffer et al. 2011; Murer et al. 2015; Foster 2017). The more common clinical signs of pyometra can include vulvar discharge, lethargy, fever, anorexia, vomiting, polyuria, and polydipsia (McCain et al. 2009). Severe cases may result in sepsis and shock (Jankowski et al. 2012). Pathologic agents associated with this lesion include *Streptococcus* sp., *Staphylococcus* sp., *Pasteurella* sp., *Pseudomonas* sp., *Proteus* sp., *Escherichia coli*, *Campylobacter fetus*, and *Brucella abortus* (Schlafer and Miller 2007; Foster 2017). Pyometra has been rarely diagnosed in hedgehogs, such as the African hedgehog (*Atelerix albiventris*; Agetti Filho et al. 2014) and tenrecs (*Echinops telfairi*; Thompson et al. 2017). There is one report of endometritis reported in an African hedgehog (Raymond and White 1999). Bacteria from the genus *Staphylococcus* have not been reported as being commonly isolated from cases of pyometra, with only a few instances described in dogs (*Canis lupus familiaris*; Asa et al. 2013; Foster 2017) and ferrets (*Mustela putorius furo*; Lloyd 1999). *Staphylococcus aureus* is reported in hedgehogs in association with other lesions, such as abscesses, and as commensal in its microbiota (Bexton 2016). Here, we report the isolation of *S. lentus* from a wild European hedgehog. *Staphylococcus lentus* (part of the *Staphylococcus sciuri* group) is an uncommon and mostly opportunistic pathogen. This agent has been associated to urinary tract infections in humans and mink (*Mustela vison*; Schwarz 1994; Stepanovic et al. 2005).

Septicemia, resulting from the uterine infection, was the most probable cause of the animal's death, as *S. lentus* was isolated from a swab of heart blood. For this case, nothing is known about the route of infection or about the reproductive history of the animal. Pyometra could have been caused by infection from the urinary tract or vaginal flora, or it could have been associated with previous fetal mortality, retained fetal membranes, cervical obstruction (tumor or fibrous), or uterine tumors. Hematogenous or transactional infection is also a

possibility (Foster 2017). However, no signs of cervix tumors or other uterine findings besides pyometra were observed. The animal had no signs of recent birth and was probably in estrus (as it was admitted in August). Although it was not possible to culture urine from in this animal, we cannot exclude a previous urinary infection, which may be the most probable origin of uterus infection.

This study was funded by projects UID/CVT/00772/2013 and UID/CVT/00772/2016 supported by the Portuguese Science and Technology Foundation.

LITERATURE CITED

- Agetti Filho H, Caldas M, Vega C, Almeida de Arruda J. 2014. Cystic endometrial hyperplasia and pyometra in an African hedgehog (*Atelerix albiventris*)—Case report. In: *IV simpósio internacional de diagnóstico por imagem veterinário (SINDIV)*, Belo Horizonte, Brazil, 22–23 November, pp. 145–147. (http://www.infoteca.inf.br/sindiv/smarty/templates/arquivos_template/upload_arquivos/acervo/docs/45.pdf.)
- Asa CS, Bauman KL, Devery S, Zordan M, Gerard RC, Boutelle S, Moresco A. 2014. Factors associated with uterine endometrial hyperplasia and pyometra in wild canids: Implications for fertility. *Zoo Biol* 33:8–19.
- Bexton S. 2016. Hedgehogs. In: *BSAVA manual of wildlife casualties*, 2nd Ed., Mullineaux E, Keeble E, editors. British Small Animal Veterinary Association, Quedgeley, UK, pp. 117–136.
- Foster RA. 2017. Female reproductive system and mammae. In: *Pathologic basis of veterinary disease*, 6th Ed., Zachary JF, editor. Elsevier, St. Louis, Missouri, pp. 1147–1193.
- Garcês A, Pires I. 2017. *Manual de técnicas de necropsia em animais selvagens*. 1st Ed. Arteology, Oporto, Portugal, 152 pp.
- Harris S, Yalden D. 2008. *Mammals of the British Isles: Handbook*. 4th Ed. Mammal Society, London, UK, 800 pp.
- Huber H, Ziegler D, Pflüger V, Vogel G, Zweifel C, Stephan R. 2011. Prevalence and characteristics of methicillin-resistant coagulase-negative staphylococci from livestock, chicken carcasses, bulk tank milk, minced meat, and contact persons. *BMC Vet Res* 7:6.
- Hueffer K, Lieske CL, McGivary LM, Hare RF, Miller DL, O'Hara TM. 2011. *Streptococcus phocae* isolated from a spotted seal (*Phoca largha*) with pyometra in Alaska. *J Zoo Wildl Med* 42:108–112.
- Jankowski G, Adkesson MJ, Langan JN, Haskins S, Landolfi J. 2012. Cystic endometrial hyperplasia and pyometra in three captive African hunting dogs (*Lycan pictus*). *J Zoo Wildl Med* 43:95–100.
- Lloyd M. 1999. *Ferrets: Health, husbandry and diseases*. Blackwell Science Ltd., Oxford, UK, 208 pp.

- McCain S, Ramsay E, Allender MC, Souza C, Schumacher J. 2009. Pyometra in captive large felids: A review of eleven cases. *J Zoo Wildl Med* 40:147–151.
- Murer L, Ribeiro MB, Machado L, Sagave L, Kommer GD, Galiza GJN, Moreira N, Lovato M. 2015. Pyometra in a lion (*Panthera leo*): Case report. *Arq Bras Med Vet Zootec* 67:727–731.
- Raymond JT, White MR. 1999. Necropsy and histopathologic findings in 14 African hedgehogs (*Atelerix albiventris*): A retrospective study. *J Zoo Wildl Med* 30:273–277.
- Reeve N. 2002. *Hedgehogs*. Poyser, London, UK, 304 pp.
- Schlafer D, Miller R. 2007. Female genital system. In: *Jubb, Kennedy & Palmer's pathology of domestic animals*, Vol. 3, 5th Ed., Maxie M, editor. Elsevier, St. Louis, Missouri, pp. 431–565.
- Schwarz S. 1994. Emerging chloramphenicol resistance in *Staphylococcus lentus* from mink following chloramphenicol treatment: Characterisation of the resistance genes. *Vet Microbiol* 41:51–61.
- Schwendener S, Perreten V. 2012. New MLS_B resistance gene *erm(43)* in *Staphylococcus lentus*. *Antimicrob Agents Chemother* 56:4746–4752.
- Stepanović S, Dakić I, Morrison D, Hauschild T, Ježek P, Petráš P, Martel A, Vuković D, Shittu A, Devriese LA. 2005. Identification and characterization of clinical isolates of members of the *Staphylococcus sciuri* group. *J Clin Microbiol* 43:956–958.
- Thompson KA, Agnew D, Nofs SA, Harrison TM. 2017. Obstetrical and postpartum complications in lesser Madagascar hedgehog tenrecs (*Echinops telfairi*): Four cases. *J Zoo Wildl Med* 48:446–452.

Submitted for publication 24 June 2018.

Accepted 14 November 2018.