

# Utility of Perioperative Lung Ultrasound in Pediatric Cardiac Surgery

## A Randomized Controlled Trial

In-Kyung Song, M.D., Eun-Hee Kim, M.D., Ji-Hyun Lee, M.D., Pyoyoon Kang, M.D., Hee-Soo Kim, M.D., Ph.D., Jin-Tae Kim, M.D., Ph.D.

### ABSTRACT

**Background:** Pediatric cardiac patients are at risk for perioperative respiratory insufficiency. The objective of this study was to assess the utility of perioperative lung ultrasound examination in pediatric cardiac surgery.

**Methods:** In this randomized, controlled trial, children (5 yr old or younger) undergoing cardiac surgery were allocated into a control (n = 61) or intervention (n = 61) group. The control group received only lung ultrasound examinations at the end of surgery and 6 to 12h after surgery. The intervention group received lung ultrasound examinations and an ultrasound-guided recruitment maneuver depending on ultrasound findings after inducing anesthesia, at the end of surgery, and 6 to 12h after surgery. Primary outcomes were incidences of intra- and postoperative desaturation, and postoperative pulmonary complications. Multiple comparisons were corrected ( $P \leq 0.017$ ) in the primary outcome analysis.

**Results:** Of the 120 children included in the analysis, postoperative desaturation (64% vs. 27%;  $P < 0.001$ ; odds ratio [OR], 0.210; 95% CI, 0.097 to 0.456) occurred more in the control group. The incidences of intraoperative desaturation (36% vs. 19%;  $P = 0.033$ ; OR, 0.406; 95% CI, 0.176 to 0.939) and postoperative pulmonary complications (12% vs. 3%;  $P = 0.093$ ; OR, 0.271; 95% CI, 0.054 to 1.361) were similar between the groups. Lung ultrasound scores were better in the intervention group than in the control group. Duration of mechanical ventilation was longer in the control group than in the intervention group ( $38 \pm 43$  vs.  $26 \pm 25$  h; 95% CI of mean difference, 0 to 25;  $P = 0.048$ ).

**Conclusions:** Perioperative lung ultrasound examination followed by ultrasound-guided recruitment maneuver helped decrease postoperative desaturation events and shorten the duration of mechanical ventilation in pediatric cardiac patients.

**Visual Abstract:** An online visual overview is available for this article at <http://links.lww.com/ALN/B682>. (ANESTHESIOLOGY 2018; 128:718-27)

PEDIATRIC patients are at risk for developing respiratory insufficiency after cardiac surgery because of diminished respiratory reserve.<sup>1</sup> Furthermore, ventilatory failure may arise from several causes such as the effects of general anesthesia, median sternotomy incision, use of cardiopulmonary bypass (CPB), cooling for myocardial protection, anomalies in gas exchange, alterations in lung mechanics, neuromuscular incompetency, and impaired respiratory muscle energetics.<sup>2,3</sup> Pulmonary complications are associated with high morbidity and mortality, increased healthcare costs, and lengthened hospital stay.<sup>4</sup> Given that anesthetic management can cause, aggravate, or ameliorate pulmonary complications, optimizing perioperative respiratory care is crucial for improving outcomes after pediatric cardiac surgery.

Lung ultrasound has been gaining consensus as a noninvasive, radiation-free tool for diagnosing various pulmonary diseases in adult and pediatric patients.<sup>5-8</sup> Evidence supporting lung ultrasound use is expanding beyond emergency and critical care settings to perioperative care.<sup>9-11</sup> The performance of lung ultrasound approaches that of computed tomography and surpasses that of chest x-ray for diagnosing lung pathologies including consolidation, pleural effusion,

#### What We Already Know about This Topic

- Lung ultrasound is an emerging tool in perioperative care

#### What This Article Tells Us That Is New

- Using lung ultrasound to optimize lung recruitment improves clinical outcomes in children having cardiac surgery

pulmonary edema, and pneumothorax,<sup>7</sup> which occur frequently after cardiac surgery. Considering that pediatric patients are more sensitive to radiation hazards, position changes, and patient transfers, lung ultrasound would be a favorable perioperative option in pediatric cardiac surgery. Nevertheless, there are no guidelines or recommendations for lung ultrasound use in pediatric cardiac surgery.

We hypothesized that perioperative lung ultrasound examinations followed by interventions according to the lung ultrasound findings would benefit pediatric patients undergoing cardiac surgery with CPB and improve clinical outcomes. The objective of this study was to assess the utility of perioperative lung ultrasound and effect of ultrasound-guided recruitment maneuver in pediatric cardiac surgery.

This article is featured in "This Month in Anesthesiology," page 1A. This article has an audio podcast.

Submitted for publication March 4, 2017. Accepted for publication December 5, 2017. From the Department of Anesthesiology and Pain Medicine, Asan Medical Center, University of Ulsan College of Medicine, Seoul, Korea (I.-K.S.); and the Department of Anesthesiology and Pain Medicine, Seoul National University Hospital, Seoul National University College of Medicine, Seoul, Korea (E.-H.K., J.-H.L., P.K., H.-S.K., J.-T.K.).

Copyright © 2018, the American Society of Anesthesiologists, Inc. Wolters Kluwer Health, Inc. All Rights Reserved. Anesthesiology 2018; 128:718-27

## Materials and Methods

### Study Design and Participants

This study was designed as a randomized, controlled, single-blinded, superiority trial. The study was performed at the Seoul National University Hospital, Korea, between August 2015 and August 2016. The study protocol was approved by the Seoul National University Hospital Institutional Review Board (August 20, 2015/No.1507-062-687). The study team evaluated eligibility of patients, obtained written informed consent from parents, and enrolled the participants by individually approaching them before surgery. The inclusion criteria were pediatric patients age 5 yr old or younger who were scheduled for cardiac surgery of acyanotic congenital heart disease. The exclusion criteria were previous thoracic surgery; upper or lower airway infection; airway anomaly; pulmonary disease; genetic disease; abnormal preoperative chest x-ray findings including atelectasis, pneumothorax, pleural effusion, or pneumonia; and preoperative oxygen saturation measured by pulse oximetry ( $SpO_2$ ) of 97% or less with room air.

### Randomization

Patients were allocated by a simple randomization to either a control or intervention group at an allocation ratio of 1:1 using computer-generated randomization software (<http://www.randomization.com>; accessed August 24, 2015). Group allocations were concealed in sequentially numbered, opaque, sealed envelopes, which were opened by a member of the study team after inducing general anesthesia. Each envelope contained the group allocation with instructions for the attending anesthesiologist.

### Anesthesia and Perioperative Ventilatory Settings

An intravenous route was established before bringing the patient to the operating room. Standard monitoring for cardiac surgery included electrocardiography,  $SpO_2$ , noninvasive blood pressure, invasive arterial blood pressure, central venous pressure, rectal and nasal temperatures, cerebral near-infrared spectroscopy, and transesophageal echocardiography. All patients underwent an institutionalized general anesthetic protocol that included preoxygenation with 100% oxygen; induction with 0.02 mg/kg atropine, 0.1 mg/kg midazolam, 4 to 5 mg/kg thiopental sodium, and 5 to 10  $\mu$ g/kg fentanyl; neuromuscular blockade with 1 mg/kg rocuronium; tracheal intubation with a cuffed endotracheal tube (ETT) of proper size; and maintenance with an air-oxygen mixture.

After tracheal intubation, mechanical ventilation of the lungs was initiated in a volume-controlled mode set to deliver a tidal volume of 8 ml/kg, a positive end-expiratory pressure of 5 cm  $H_2O$ , and a fractional inspired oxygen tension ( $F_{IO_2}$ ) of 0.4. The ventilator was set to deliver 20 to 40 breaths/min depending on the patient's age<sup>12</sup> and was adjusted to end-tidal carbon dioxide of 35 to 45 mmHg, with an inspiratory:expiratory ratio of 1:2.

Anesthesia was maintained using 0.1 to 0.2 mg  $\cdot$  kg<sup>-1</sup>  $\cdot$  h<sup>-1</sup> midazolam, 2.5 to 5  $\mu$ g  $\cdot$  kg<sup>-1</sup>  $\cdot$  h<sup>-1</sup> sufentanil, and 0.05 to 0.1 mg  $\cdot$  kg<sup>-1</sup>  $\cdot$  h<sup>-1</sup> vecuronium. Surgery was performed through a standard median sternotomy and proceeded as per institutional protocol. During sternotomy, the lungs were temporarily deflated to prevent lung injury. When patients were on the CPB, the lungs were completely deflated and not ventilated. While preparing for separation from the CPB, mechanical ventilation was reinitiated as the same setting after tracheal suction and lung inflation in both groups. A subxiphoid mediastinal tube was inserted in the pericardial cavity after successful weaning from the CPB. Intraoperative arterial blood gas (ABG) analyses were performed three times: after induction of anesthesia, after weaning from CPB, and after sternal closure.

After the surgery, all patients were transferred to the pediatric intensive care unit without reversing the neuromuscular blockade. During the transfer, patients were ventilated with 100% oxygen by anesthesiologists blinded to the randomization result. In the pediatric intensive care unit, patients were mechanically ventilated in a pressure-regulated volume-controlled mode to deliver a tidal volume of 10 ml/kg, a positive end-expiratory pressure of 5 cm  $H_2O$ , a  $F_{IO_2}$  of 0.6, and a respiratory rate of 20 to 40 breaths/min with an inspiratory:expiratory ratio of 1:2. The setting was adjusted by surgeons who were blinded to the randomization result. Postoperative laboratory and chest x-ray examinations were performed immediately, 3 h, and 6 to 12 h after admission to the pediatric intensive care unit. The decision regarding when to extubate or transfer to the general ward was made by the surgeons in the pediatric intensive care unit. The criteria for extubation were  $PaO_2/F_{IO_2} \geq 200$  from ABG ( $PaO_2$  80 mmHg on  $F_{IO_2}$  0.4) with an adequate level of consciousness, spontaneous respiration, and hemodynamic stability. The criteria for pediatric intensive care unit discharge were stable hemodynamics and rhythm without inotropic support, appropriate ventilation and oxygenation without mechanical ventilatory support, and adequate diuresis and mentation.

### $SpO_2$ Monitoring

During the intraoperative and postoperative period, the same  $SpO_2$  sensor (Nellcor with OxiMax Technology Neonatal/Adult or Infant Adhesive  $SpO_2$  sensor, Covidien, USA) and monitoring device (Solar 8000M/i patient monitor, GE Medical Systems, USA) were used in the operating room and pediatric intensive care unit. According to the manufacturer, the accuracy of the  $SpO_2$  monitor was 1.5% for the  $SpO_2$  range of 90 to 100%, 2.1% for 80 to 89.9%, and 2.4% for 60 to 79.9%. Desaturation cutoff was set as  $SpO_2 < 95\%$ .<sup>12</sup>

### Lung Ultrasound Examination

Lung ultrasound examination was performed twice in the control group and three times in the intervention group. Only the intervention group underwent lung ultrasound examination

1 min after initiating mechanical ventilation of the lungs after tracheal intubation (designated as preoperative lung ultrasound examination). Both groups underwent lung ultrasound examination at the end of surgery (designated as postoperative lung ultrasound examination) and 6 to 12 h after surgery in the pediatric intensive care unit (designated as pediatric intensive care unit lung ultrasound examination).

All ultrasound scans were performed by the same anesthesiologist, who had an experience of 100 or more lung ultrasound scans in pediatric patients, using Logiq *e* US (GE Healthcare, USA) with a 4- to 10-MHz linear transducer. Patients were scanned in the supine position according to the lung ultrasound examination method described by Acosta *et al.*<sup>13</sup> Each hemithorax was divided into six regions using three longitudinal lines (parasternal, anterior, and posterior axillary) and two axial lines (one above the diaphragm and the other 1 cm above the nipples). The 12 lung regions were sequentially scanned from right to left, cranial to caudal, and anterior to posterior. Each region was assessed using a two-dimensional view with the probe placed parallel to the ribs and was evaluated for the following signs: the lung “sliding” sign, A-lines, B-lines, consolidation, air-bronchograms, pleural effusion, and pneumothorax.

The degree of consolidations and B-lines was scored from 0 to 3 following the grading method described by Song *et al.*<sup>14</sup> The degree of pleural effusion was divided into four grades and scored from 0 to 3: 0, no pleural effusion; 1, minimal pleural effusion; 2, a small amount of pleural effusion; and 3, a moderate amount of pleural effusion.<sup>15</sup> Representative lung ultrasound findings are shown in figure 1. The worst ultrasound abnormality detected was considered as the characterization for the region examined, and video clips of each region were stored. The degree of consolidations, B-lines, and pleural effusions were separately scored for each region and were summed for analysis.

### Lung Ultrasound-guided Recruitment Maneuver

In the intervention group, a recruitment maneuver was performed after each lung ultrasound examination if there was significant atelectasis, defined as a consolidation score of 2 or greater in any region.<sup>14</sup> Under real-time ultrasound guidance, a 5-cm H<sub>2</sub>O stepwise increase in airway pressure from 10 cm H<sub>2</sub>O with an F<sub>IO<sub>2</sub></sub> of 0.4 was manually applied until no collapsed lung areas were visible on the ultrasound. Each level of continuous positive airway pressure was applied for 5 s. The maximum airway pressure was limited to 40 cm H<sub>2</sub>O. After applying the lung ultrasound-guided recruitment maneuver once, the same ventilator setting was maintained. The timeline of the lung ultrasound examination and lung ultrasound-guided recruitment maneuver performed in each group is illustrated in figure 2.

### Outcome Variables and Statistics

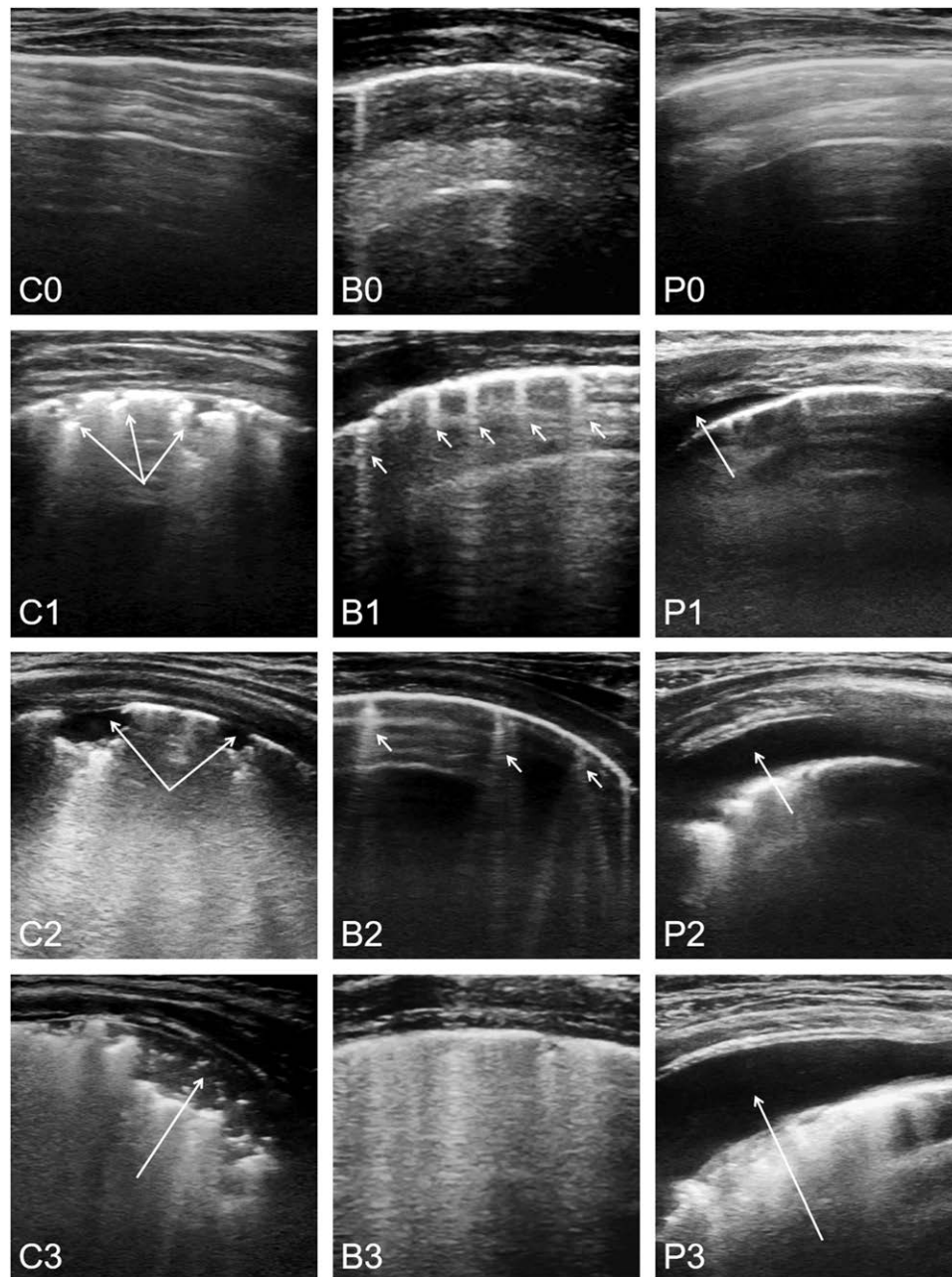
The following data were collected for every patient: age, height, weight, sex, diagnosis, pre- and postoperative chest

x-ray findings, duration of anesthesia, number of intra- and postoperative (within 24 h) desaturation (SpO<sub>2</sub> < 95%) events, intra- and postoperative (within 24 h) ABG results, duration of mechanical ventilation, and length of pediatric intensive care unit stay. The primary outcomes were the incidences of intraoperative desaturation, postoperative (within 24 h) desaturation, and postoperative (within 24 h) pulmonary complications. Postoperative pulmonary complications were defined as respiratory infection, respiratory failure, pleural effusion, atelectasis, pneumothorax, bronchospasm, and aspiration pneumonia following the description by Gallart and Canet.<sup>16</sup> The secondary outcomes included the incidence of desaturation during transfer to pediatric intensive care unit, number of intra- and postoperative desaturation events, initial SpO<sub>2</sub> upon arrival to the pediatric intensive care unit, duration of mechanical ventilation, length of pediatric intensive care unit stay, incidence of postoperative fever (body temperature ≥ 37.5°C within 24 h), intra- and postoperative (within 24 h) ratio of arterial oxygen partial pressure to F<sub>IO<sub>2</sub></sub> (PaO<sub>2</sub>/F<sub>IO<sub>2</sub></sub>) from ABG, and lung ultrasound scores of consolidations, B-lines, and pleural effusion on the postoperative and pediatric intensive care unit lung ultrasound examinations. Hemodynamic deterioration (greater than or equal to 20% baseline) during the recruitment maneuver was recorded.

Because there were no previous studies investigating the effect of perioperative lung ultrasound in patients undergoing cardiac surgery, the sample size was calculated from previous data obtained in pediatric patients.<sup>17</sup> Considering that the incidence of intraoperative hypoxemia was 20% in pediatric patients undergoing general anesthesia, we assumed that performing the perioperative lung ultrasound and lung ultrasound-guided recruitment maneuver would decrease it to 5%. The required sample size was 61 for each group, with a set  $\alpha$  error of 0.05, a power of 80%, and a dropout rate of 10%.

All data are expressed as the mean  $\pm$  SD or median (interquartile range [range]) unless otherwise specified. The Kolmogorov-Smirnov test was used to determine the normality of the distribution. The primary outcomes were evaluated using the chi-square test. The secondary outcomes were evaluated using the Student's *t* test and chi-square test for the continuous and categorical variables, respectively. The Mann-Whitney U test was used for comparison of the initial SpO<sub>2</sub> upon arrival to pediatric intensive care unit and lung ultrasound scores between the groups. The Wilcoxon signed-rank test was used for comparison of the intragroup lung ultrasound scores.

Although the adjustment for multiple primary outcomes was not included in the original analysis plan, it was requested during the peer review process. In order to adjust the multiplicity of primary outcomes, the Bonferroni correction was applied. Regarding three primary outcomes,  $P \leq 0.017$  was considered to be statistically significant. These adjustments were *post hoc* and were offered in attempt to conservatively interpret the primary inference. Statistical



**Fig. 1.** Lung ultrasound findings of consolidations, B-lines, and pleural effusion. The degree of consolidations was divided into four grades: C0, no consolidation; C1, minimal juxtapleural consolidations; C2, small-sized consolidations; and C3, large-sized consolidations. The degree of B-lines was divided into four grades: B0, fewer than three isolated B-lines; B1, multiple well-defined B-lines; B2, multiple coalescent B-lines; and B3, white lung. The degree of pleural effusion was divided into four grades: P0, no pleural effusion; P1, minimal pleural effusion; P2, small amount of pleural effusion; and P3, moderate amount of pleural effusion. Each *arrow* indicates pathologic findings in each figure.

analysis was performed using IBM SPSS Statistics 23 (SPSS Inc., IBM Corp., USA).

## Results

From August 25, 2015, to August 22, 2016, 122 children were enrolled and randomized into the control ( $n = 61$ ) and intervention ( $n = 61$ ) groups, respectively (fig. 3). Two patients in the intervention group were excluded from the

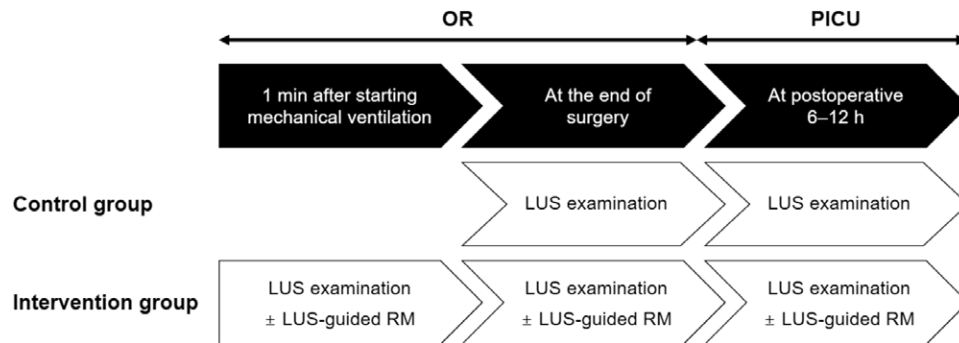
final analysis because pediatric intensive care unit lung ultrasound examination could not be performed. Baseline characteristics of the study population and perioperative variables are summarized in table 1.

Among three primary outcomes, the incidence of post-operative desaturation was higher in the control group than in the intervention group (64% *vs.* 27%;  $P < 0.001$ ; OR, 0.210; 95% CI, 0.097 to 0.456). However, the incidences of

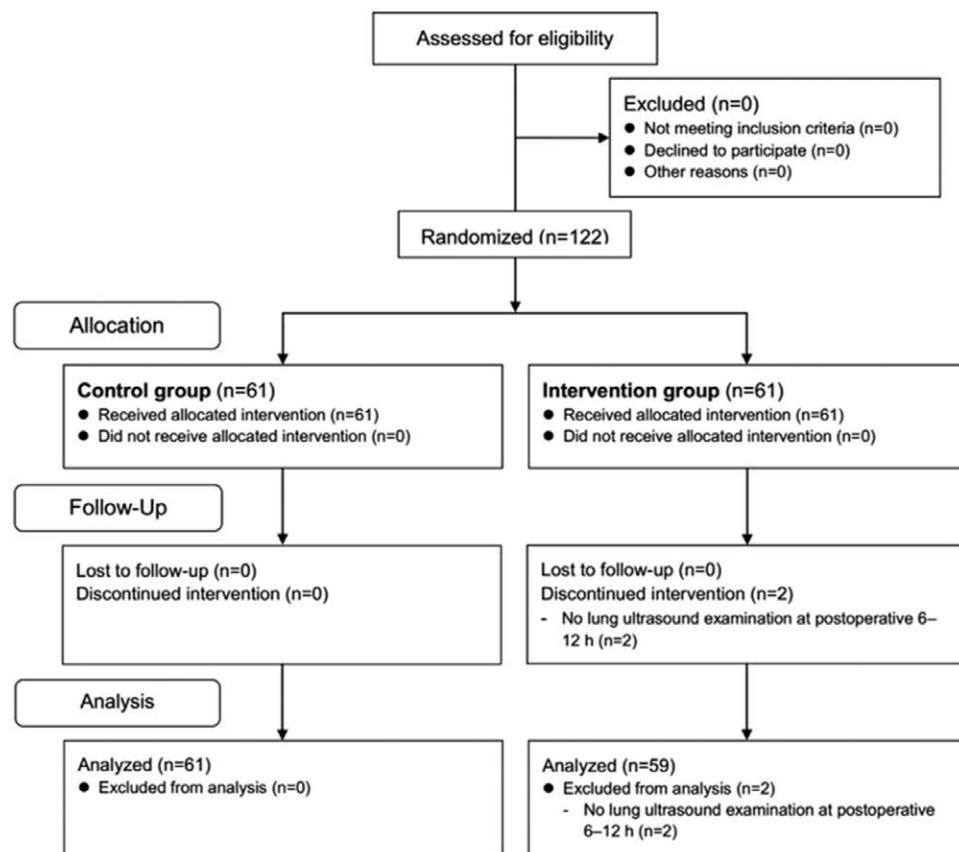
intraoperative desaturation (36% vs. 19%;  $P = 0.033$ ; OR, 0.406; 95% CI, 0.176 to 0.939) and postoperative pulmonary complications (12% vs. 3%;  $P = 0.093$ ; OR, 0.271; 95% CI, 0.054 to 1.361) were similar between the control and intervention groups.

Other perioperative outcome variables are summarized in table 2. In the intervention group, 55 (93%) patients on the preoperative lung ultrasound examination, 25 (42%) patients on the postoperative lung ultrasound examination, and 50 (85%) patients on the pediatric intensive care unit lung ultrasound examination received

a lung ultrasound-guided recruitment maneuver. The incidence of desaturation during transfer to the pediatric intensive care unit was similar between the control and intervention groups (5% vs. 0%;  $P = 0.244$ ; OR, 0.951; 95% CI, 0.898 to 1.007). Although the length of pediatric intensive care unit stay did not show a difference between the groups ( $67 \pm 62$  vs.  $53 \pm 37$ ; 95% CI of mean difference,  $-5$  to  $32$ ;  $P = 0.145$ ), the duration of mechanical ventilation was significantly shorter in the intervention group than in the control group ( $38 \pm 43$  vs.  $26 \pm 25$ ; 95% CI of mean difference,  $0$  to  $25$ ;  $P = 0.048$ ). The



**Fig. 2.** Schematic timeline illustrating the study protocol for each group. The intervention group received lung ultrasound (LUS)-guided recruitment maneuver (RM) if there was significant atelectasis on the LUS examination. The control group received only LUS examinations without RM. OR = operating room; PICU = pediatric intensive care unit.



**Fig. 3.** Consolidated Standards of Reporting Trials flow diagram.

incidence of postoperative fever did not differ between the groups (62% vs. 71%;  $P = 0.337$ ; OR, 1.495; 95% CI, 0.696 to 3.214).

The intra- and postoperative  $PaO_2/FiO_2$  values are summarized in table 3. All  $PaO_2/FiO_2$  values were significantly higher in the intervention group than in the control group.

The lung ultrasound scores of consolidations, B-lines, and pleural effusion are summarized in table 4. The lung ultrasound scores of consolidations and B-lines on the postoperative and pediatric intensive care unit lung ultrasound examination were significantly lower in the intervention group than in the control group. In the intervention group, the lung ultrasound scores of consolidations and B-lines significantly decreased between the pre- and postoperative

lung ultrasound examinations. Nonetheless, in both groups, the lung ultrasound scores of consolidations and B-lines significantly increased between the postoperative and pediatric intensive care unit lung ultrasound examinations.

Preoperative lung ultrasound examination detected an abnormal ETT placement in the intervention group. Moreover, in the control group, postoperative and pediatric intensive care unit lung ultrasound examinations discovered significant pleural effusion that needed a chest tube insertion and minimal pneumothorax, respectively. No complications such as hypotension, arrhythmia, or lung injury were associated with the recruitment maneuver.

### Discussion

In this study, we investigated the utility of perioperative lung ultrasound examinations in pediatric patients undergoing cardiac surgery. Perioperative lung ultrasound examinations accompanied by lung ultrasound-guided recruitment maneuvers proved useful for decreasing postoperative desaturation events, improving lung ultrasound findings, and shortening the duration of mechanical ventilation.

Despite several reports regarding the use of lung ultrasound for diagnosing and managing various diseases in pediatric patients, including respiratory distress syndrome, pneumonia, bronchiolitis, and atelectasis,<sup>18–21</sup> data concerning the use of lung ultrasound in cardiac surgery are limited in adult and pediatric populations. Especially in children, there have been only case reports regarding the use of lung ultrasound in cardiac surgery.<sup>10,22</sup> To the best of our knowledge, this is the first randomized controlled trial investigating the use of lung ultrasound and the effect of lung ultrasound-guided recruitment maneuvers according to the lung ultrasound findings in pediatric cardiac surgery.

Alsaddique *et al.*<sup>11</sup> recently demonstrated that routine repeated monitoring with cardiac and lung ultrasound after cardiac surgery in adults is feasible and that it alters clinically important diagnoses. In our study, lung ultrasound examination with recruitment maneuver played a key role in improving perioperative respiratory care not only by

**Table 1.** Baseline Characteristics of the Study Population

	Control Group, n = 61	Intervention Group, n = 59	P Value
Age (months)	10 ± 14	15 ± 16	0.085
Boys	36 (59)	30 (51)	0.463
Height (cm)	69.4 ± 15.9	75.1 ± 16.8	0.056
Weight (kg)	7.4 ± 3.5	8.7 ± 3.9	0.067
Diagnosis			
Atrial septal defect	16	21	
Ventricular septal defect	38	33	
Atrioventricular septal defect	2	1	
Tetralogy of Fallot	3	0	
Coarctation of the aorta	1	1	
Aortic stenosis	1	1	
Tricuspid regurgitation	0	1	
Mitral valve regurgitation	0	1	
Preoperative chest x-ray findings			
No active lung lesion	14	10	
Increased pulmonary vascularity	47	49	
Duration of anesthesia (min)	301 ± 70	310 ± 59	0.425

Data presented as mean ± SD or n (%).

**Table 2.** Perioperative Outcome Variables

	Control Group, n = 61	Intervention Group, n = 59	95% CI of Mean Difference	P Value
Recruitment maneuver after				
Preoperative lung ultrasound examination	0	55 (93%)		
Postoperative lung ultrasound examination	0	25 (42%)		
Pediatric intensive care unit lung ultrasound examination	0	50 (85%)		
Number of desaturation events				
Intraoperative	1 ± 1	0 ± 0	0 to 1	0.007
Postoperative	2 ± 5	0 ± 1	1 to 3	0.006
Initial $SpO_2$ upon arrival to pediatric intensive care unit (%)	99 (99–100 [94–100])	100 (99–100 [95–100])	–1 to 0	0.018
Duration of mechanical ventilation (h)	38 ± 43	26 ± 25	0 to 25	0.048
Length of pediatric intensive care unit stay (h)	67 ± 62	53 ± 37	–5 to 32	0.145

Data presented as mean ± SD, median (interquartile range [range]), or n (%).

$SpO_2$  = oxygen saturation measured by pulse oximetry.

eliminating atelectasis but also by discovering abnormal conditions such as misplaced ETT, pleural effusion, and pneumothorax.

Compared with the findings of de Graaff *et al.*,<sup>17</sup> that the incidence of intraoperative hypoxemia ( $SpO_2 \leq 90\%$ ) was 20% in pediatric noncardiac surgery, the overall incidence of intraoperative desaturation was 28% (36% in the control group *vs.* 19% in the intervention group) in this study despite a stricter definition ( $SpO_2 < 95\%$ ). Moreover, the overall incidence of postoperative desaturation was 46% (64% in the control group *vs.* 27% in the intervention group), which was higher than that of adults,<sup>23</sup> reconfirming that pediatric patients undergoing cardiac surgery are vulnerable to pulmonary complications. Therefore, perioperative respiratory care is essential in pediatric cardiac surgery.

**Table 3.** Intraoperative and Postoperative Ratio of  $Pao_2$  to  $Fio_2$  from ABG Results

	Control Group, n = 61	Intervention Group, n = 59	P Value
<b>Intraoperative</b>			
After induction of anesthesia	438 ± 99	528 ± 66	< 0.001
After weaning from CPB	434 ± 109	506 ± 118	0.001
After sternal closure	433 ± 118	548 ± 138	< 0.001
<b>Postoperative</b>			
Immediately after pediatric intensive care unit admission	373 ± 140	477 ± 102	< 0.001
3 h after operation	324 ± 117	398 ± 110	0.001
6–12 h after operation	280 ± 105	376 ± 115	< 0.001

Data presented as mean ± SD.

ABG = arterial blood gas; CPB = cardiopulmonary bypass;  $Fio_2$  = fractional inspired oxygen tension.

**Table 4.** Lung Ultrasound Scores of the Study Population

	Control Group, n = 61	P Value*	Intervention Group, n = 59	P Value†	P Value‡
<b>Preoperative lung ultrasound examination</b>					
Lung ultrasound score of consolidations			14 (11–17 [2–25])		
Lung ultrasound score of B-lines			14 (9–19 [2–26])		
<b>Postoperative lung ultrasound examination</b>					
Lung ultrasound score of consolidations	13 (10–16 [1–23])		8 (6–12 [1–17])	< 0.001	< 0.001
Lung ultrasound score of B-lines	17 (12–22 [2–31])		9 (4–14 [0–23])	< 0.001	< 0.001
Lung ultrasound score of pleural effusion	0 (0–0 [0–10])		0 (0–0 [0–6])	—	0.428
<b>Pediatric intensive care unit lung ultrasound examination</b>					
Lung ultrasound score of consolidations	22 (17–24 [5–31])	< 0.001	15 (9–18 [2–23])	< 0.001	< 0.001
Lung ultrasound score of B-lines	22 (16–29 [2–33])	< 0.001	18 (9–21 [2–27])	< 0.001	< 0.001
Lung ultrasound score of pleural effusion	0 (0–0 [0–10])	0.078	0 (0–0 [0–6])	0.007	0.543

Lung ultrasound scores are a summation of scores from the anterior, the lateral, and the posterior regions. Data presented as median (interquartile range [range]).

\*Lung ultrasound score comparison in the control group. †Lung ultrasound score comparison in the intervention group. ‡Control group *vs.* intervention group.

We found no difference in the incidence of intraoperative desaturation ( $P = 0.033$ ) between the groups. However, when interpreting our results, one should consider that we applied conservative statistics to adjust multiple primary outcomes ( $P \leq 0.017$ ), as we mentioned in Materials and Methods. The incidences of intra- and postoperative desaturation were reduced by more than half between the groups by performing perioperative lung ultrasound examinations and lung ultrasound-guided recruitment maneuvers according to the lung ultrasound findings.

Patients in the control group experienced 2.5 times greater numbers of intraoperative desaturation events compared with those in the intervention group. Most of the desaturation events occurred during the sternotomy when the lungs were deflated (73%), and the rest occurred during the weaning from CPB in the control group. Conversely, in the intervention group, the desaturation percentage during sternotomy (55%) was much smaller, implying that a preoperative lung ultrasound examination with recruitment maneuver may have contributed to atelectasis resolution, occurring after the induction of anesthesia, and to better alveolar aeration. Furthermore, the number of postoperative desaturation events in the control group was five times greater than that in the intervention group, and three of these patients had 10 or more events, indicating that not only the incidence but also the intensity of desaturation differed between the groups.

Because the lungs were deflated while on CPB, that could have brought equilibration in the state of the lungs between the groups regardless of any benefit gained by the preoperative lung ultrasound examination with recruitment maneuver. Nevertheless, the intervention group showed better lung ultrasound scores in the postoperative lung ultrasound examination. Pulmonary dysfunction attributed to CPB is thought to arise from the effects of acute systemic and

pulmonary inflammatory response.<sup>24</sup> In addition, the cessation of ventilation during CPB results in collapsed lungs leading to insufficient alveolar distention to activate the production of surfactant, which potentiates alveolar collapse and atelectasis.<sup>24</sup> In this context, pre-CPB collapsed lungs in the control group could have contributed to the inflammatory response and subsequent reactions, causing unfavorable results after CPB.

The focus of pediatric cardiac surgery has changed from saving lives to reducing morbidity and optimizing quality of life.<sup>25</sup> Hence, concepts such as early extubation and reduction in the intensive care unit or hospital stay are being investigated. Evidence regarding early extubation after pediatric cardiac surgery has established that the technique is safe and without additional morbidity or mortality, if applied in the right setting to the right population.<sup>26–31</sup> The lung ultrasound examination with recruitment maneuver in our study shortened the duration of mechanical ventilation, supporting the current trend and influencing the length of pediatric intensive care unit stay. The approximately 13-h difference for the duration of mechanical ventilation between the groups could be linked to the difference in the length of pediatric intensive care unit stay, although this was not significant. Our institution is currently practicing extubation in the operating room for eligible cases, and we believe the role of lung ultrasound would be more important in these “fast-track” cases.

Advantages of the recruitment maneuver for preventing postoperative pulmonary complications in patients undergoing general anesthesia have been demonstrated in numerous reports.<sup>32–34</sup> Among several ways of performing recruitment maneuver, we used a sustained inflation method because of its easy applicability in the operating room setting. Given that the recruitment maneuver may cause complications such as hypotension,<sup>35–37</sup> it is important to apply the recruitment maneuver carefully. In this study, real-time ultrasound guidance was applied to individualize the recruitment maneuver depending on the lung ultrasound findings. However, whether the lung ultrasound-guided recruitment maneuver is better than the recruitment maneuver without lung ultrasound needs to be verified in further studies.

Pleural effusions are significant complications after pediatric cardiac surgery, with a reported incidence ranging between 25 and 39%.<sup>38–40</sup> In this study, the overall incidence of more than a small degree of pleural effusion was 14%, which was lower than those previously reported, probably because the study subjects underwent relatively simple cardiac surgeries.

Several reports in adults have highlighted the importance of recognizing and preventing postoperative pulmonary complications after cardiac surgery,<sup>3,24,41</sup> which cannot be overemphasized in pediatric cardiac surgery, either. Given that repeated examinations are inevitable, the lung ultrasound examination with recruitment maneuver would be a suitable tool for pediatric patients after cardiac surgery, enabling point of care at the bedside. Considering that we enrolled only pediatric patients with acyanotic congenital

heart disease, generalization of our results to other populations such as children with cyanotic congenital heart disease or preterm neonates should be made cautiously.

There are several limitations in this study. First, the anesthesiologist who performed the lung ultrasound examination was not blinded, which might have influenced the outcome measurements. Nonetheless, the designated anesthesiologist only performed the lung ultrasound examination and lung ultrasound-guided recruitment maneuver. Second, because the surgeons managed the patients postoperatively, inconsistency in management plans between the surgeons could have affected the results. Third, as this study aimed to assess the utility of perioperative lung ultrasound in pediatric cardiac surgery, we focused on the intraoperative period until the first postoperative day. However, some outcome variables could have been influenced by events 24 h after surgery.

### Conclusions

Perioperative lung ultrasound examinations accompanied by lung ultrasound-guided recruitment maneuvers proved practical and beneficial to pediatric patients undergoing cardiac surgery. They decreased the incidence of postoperative desaturation events and shortened the duration of mechanical ventilation, encouraging more active application in pediatric cardiac surgery.

### Research Support

Support was provided solely from institutional and/or departmental sources.

### Competing Interests

The authors declare no competing interests.

### Reproducible Science

Full protocol available at: jintae73@snu.ac.kr. Raw data available at: jintae73@snu.ac.kr.

### Correspondence

Address correspondence to Dr. Kim: Department of Anesthesiology and Pain Medicine, Seoul National University Hospital, #101 Daehak-ro, Jongno-gu, 03080, Seoul, Korea. jintae73@gmail.com. This article may be accessed for personal use at no charge through the Journal Web site, www.anesthesiology.org.

### References

- Nichols DG: Respiratory muscle performance in infants and children. *J Pediatr* 1991; 118(pt 1):493–502
- Bronicki RA, Chang AC: Management of the postoperative pediatric cardiac surgical patient. *Crit Care Med* 2011; 39:1974–84
- Badenes R, Lozano A, Belda FJ: Postoperative pulmonary dysfunction and mechanical ventilation in cardiac surgery. *Crit Care Res Pract* 2015; 2015:420513
- Kilpatrick B, Slinger P: Lung protective strategies in anaesthesia. *Br J Anaesth* 2010; 105(suppl 1):i108–16



5. Cattarossi L: Lung ultrasound: Its role in neonatology and pediatrics. *Early Hum Dev* 2013; 89(suppl 1):S17–9
6. Volpicelli G, Elbarbary M, Blaivas M, Lichtenstein DA, Mathis G, Kirkpatrick AW, Melniker L, Gargani L, Noble VE, Via G, Dean A, Tsung JW, Soldati G, Copetti R, Bouhemad B, Reissig A, Agricola E, Rouby JJ, Arbelot C, Liteplo A, Sargsyan A, Silva F, Hoppmann R, Breikreutz R, Seibel A, Neri L, Storti E, Petrovic T, International Liaison Committee on Lung Ultrasound (ILC-LUS) for International Consensus Conference on Lung Ultrasound (ICC-LUS): International evidence-based recommendations for point-of-care lung ultrasound. *Intensive Care Med* 2012; 38:577–91
7. Ashton-Cleary DT: Is thoracic ultrasound a viable alternative to conventional imaging in the critical care setting? *Br J Anaesth* 2013; 111:152–60
8. Lichtenstein DA, Mauriat P: Lung ultrasound in the critically ill neonate. *Curr Pediatr Rev* 2012; 8:217–23
9. Tusman G, Acosta CM, Nicola M, Esperatti M, Bohm SH, Suarez-Sipmann F: Real-time images of tidal recruitment using lung ultrasound. *Crit Ultrasound J* 2015; 7:19
10. Vitale V, Ricci Z, Cogo P: Lung ultrasonography and pediatric cardiac surgery: First experience with a new tool for postoperative lung complications. *Ann Thorac Surg* 2014; 97:e121–4
11. Alsaddique A, Royle AG, Royle CF, Mobeirek A, El Shaer F, AlBackr H, Fouda M, Canty DJ: Repeated monitoring with transthoracic echocardiography and lung ultrasound after cardiac surgery: Feasibility and impact on diagnosis. *J Cardiothorac Vasc Anesth* 2016; 30:406–12
12. Davis PJ, Cladis FP, Motoyama EK: *Smith's Anesthesia for Infants and Children: Expert Consult Premium*. Philadelphia, Elsevier Health Sciences, 2010, pp 73–101
13. Acosta CM, Maidana GA, Jacovitti D, Belaunzarán A, Cereceda S, Rae E, Molina A, Gonorazky S, Bohm SH, Tusman G: Accuracy of transthoracic lung ultrasound for diagnosing anesthesia-induced atelectasis in children. *ANESTHESIOLOGY* 2014; 120:1370–9
14. Song IK, Kim EH, Lee JH, Ro S, Kim HS, Kim JT: Effects of an alveolar recruitment manoeuvre guided by lung ultrasound on anaesthesia-induced atelectasis in infants: A randomised, controlled trial. *Anaesthesia* 2017; 72:214–22
15. Prina E, Torres A, Carvalho CR: Lung ultrasound in the evaluation of pleural effusion. *J Bras Pneumol* 2014; 40:1–5
16. Gallart L, Canet J: Post-operative pulmonary complications: Understanding definitions and risk assessment. *Best Pract Res Clin Anaesthesiol* 2015; 29:315–30
17. de Graaff JC, Bijker JB, Kappen TH, van Wolfswinkel L, Zuithoff NP, Kalkman CJ: Incidence of intraoperative hypoxemia in children in relation to age. *Anesth Analg* 2013; 117:169–75
18. Vergine M, Copetti R, Brusa G, Cattarossi L: Lung ultrasound accuracy in respiratory distress syndrome and transient tachypnea of the newborn. *Neonatology* 2014; 106:87–93
19. Basile V, Di Mauro A, Scalini E, Comes P, Lofù I, Mostert M, Tafuri S, Manzionna MM: Lung ultrasound: A useful tool in diagnosis and management of bronchiolitis. *BMC Pediatr* 2015; 15:63
20. Liu J, Chen SW, Liu F, Li QP, Kong XY, Feng ZC: The diagnosis of neonatal pulmonary atelectasis using lung ultrasonography. *Chest* 2015; 147:1013–9
21. Shah VP, Tunik MG, Tsung JW: Prospective evaluation of point-of-care ultrasonography for the diagnosis of pneumonia in children and young adults. *JAMA Pediatr* 2013; 167:119–25
22. Cantinotti M, Giordano R, Assanta N, Murzi B, Gargani L: Chest ultrasound: A new, easy, and radiation-free tool to detect retrosternal clot after pediatric cardiac surgery. *J Cardiothorac Vasc Anesth* 2015; 29:e59–60
23. Ranucci M, Ballotta A, La Rovere MT, Castelvechchio S; Surgical and Clinical Outcome Research (SCORE) Group: Postoperative hypoxia and length of intensive care unit stay after cardiac surgery: The underweight paradox? *PLoS One* 2014; 9:e93992
24. Wynne R, Botti M: Postoperative pulmonary dysfunction in adults after cardiac surgery with cardiopulmonary bypass: Clinical significance and implications for practice. *Am J Crit Care* 2004; 13:384–93
25. Bastero P, DiNardo JA, Pratap JN, Schwartz JM, Sivarajan VB: Early perioperative management after pediatric cardiac surgery: Review at PCICS 2014. *World J Pediatr Congenit Heart Surg* 2015; 6:565–74
26. Harris KC, Holowachuk S, Pitfield S, Sanatani S, Froese N, Potts JE, Gandhi SK: Should early extubation be the goal for children after congenital cardiac surgery? *J Thorac Cardiovasc Surg* 2014; 148:2642–7
27. Lawrence EJ, Nguyen K, Morris SA, Hollinger I, Graham DA, Jenkins KJ, Bodian C, Lin HM, Gelb BD, Mittnacht AJ: Economic and safety implications of introducing fast tracking in congenital heart surgery. *Circ Cardiovasc Qual Outcomes* 2013; 6:201–7
28. Mittnacht AJ, Thanjan M, Srivastava S, Joashi U, Bodian C, Hossain S, Kin N, Hollinger I, Nguyen K: Extubation in the operating room after congenital heart surgery in children. *J Thorac Cardiovasc Surg* 2008; 136:88–93
29. Neirotti RA, Jones D, Hackbarth R, Paxson Fosse G: Early extubation in congenital heart surgery. *Heart Lung Circ* 2002; 11:157–61
30. Vricella LA, Dearani JA, Gundry SR, Razzouk AJ, Brauer SD, Bailey LL: Ultra fast track in elective congenital cardiac surgery. *Ann Thorac Surg* 2000; 69:865–71
31. Garg R, Rao S, John C, Reddy C, Hegde R, Murthy K, Prakash PV: Extubation in the operating room after cardiac surgery in children: A prospective observational study with multidisciplinary coordinated approach. *J Cardiothorac Vasc Anesth* 2014; 28:479–87
32. Hartland BL, Newell TJ, Damico N: Alveolar recruitment maneuvers under general anesthesia: A systematic review of the literature. *Respir Care* 2015; 60:609–20
33. Martin JB, Garbee D, Bonanno L: Effectiveness of positive end-expiratory pressure, decreased fraction of inspired oxygen and vital capacity recruitment maneuver in the prevention of pulmonary atelectasis in patients undergoing general anesthesia: A systematic review. *JBI Database System Rev Implement Rep* 2015; 13:211–49
34. Yang D, Grant MC, Stone A, Wu CL, Wick EC: A meta-analysis of intraoperative ventilation strategies to prevent pulmonary complications: Is low tidal volume alone sufficient to protect healthy lungs? *Ann Surg* 2016; 263:881–7
35. Neves VC, Koliski A, Giraldo DJ: Alveolar recruitment maneuver in mechanic ventilation pediatric intensive care unit children. *Rev Bras Ter Intensiva* 2009; 21:453–60
36. Halbertsma FJ, van der Hoeven JG: Lung recruitment during mechanical positive pressure ventilation in the PICU: What can be learned from the literature? *Anaesthesia* 2005; 60:779–90
37. Fan E, Wilcox ME, Brower RG, Stewart TE, Mehta S, Lapinsky SE, Meade MO, Ferguson ND: Recruitment maneuvers for acute lung injury: A systematic review. *Am J Respir Crit Care Med* 2008; 178:1156–63
38. Labidi M, Baillet R, Dionne B, Lacasse Y, Maltais F, Boulet LP: Pleural effusions following cardiac surgery: Prevalence, risk factors, and clinical features. *Chest* 2009; 136:1604–11
39. Bocsi J, Hamsch J, Osmanic P, Schneider P, Valet G, Tárnok A: Preoperative prediction of pediatric patients with effusions and edema following cardiopulmonary bypass surgery by serological and routine laboratory data. *Crit Care* 2002; 6:226–33
40. Airan B, Sharma R, Choudhary SK, Mohanty SR, Bhan A, Chowdhari UK, Juneja R, Kothari SS, Saxena A, Venugopal

P: Univentricular repair: Is routine fenestration justified? *Ann Thorac Surg* 2000; 69:1900–6

41. Serpa Neto A, Hemmes SN, Barbas CS, Beiderlinden M, Fernandez-Bustamante A, Futier E, Hollmann MW, Jaber S, Kozian A, Licker M, Lin WQ, Moine P, Scavonetto F, Schilling T, Selmo G, Severgnini P, Sprung J, Treschan T, Unzueta C,

Weingarten TN, Wolthuis EK, Wrigge H, Gama de Abreu M, Pelosi P, Schultz MJ; PROVE Network investigators: Incidence of mortality and morbidity related to postoperative lung injury in patients who have undergone abdominal or thoracic surgery: A systematic review and meta-analysis. *Lancet Respir Med* 2014; 2:1007–15

## ANESTHESIOLOGY REFLECTIONS FROM THE WOOD LIBRARY-MUSEUM

### Taking Pains with Aloe for More Than 35 Centuries: From Tightening Skin to Loosening Bowels



Native to the southwest Arabian peninsula, species of the Aloe have provided soothing and antiseptic preparations for wounds and burns since at least the time that the Ebers papyrus was composed (c. 1550 BCE). A Greek surgeon in the Roman army, Dioscorides lauded the bitter juice of aloe for “conglutinating of wounds and loosening of the belly.” Indeed, aloe was prized as a laxative orally and as a healing astringent topically. As depicted on this French-language trade card from the Liebig Company (above), *Aloe perryi* (Zanzibar or Socotrine Aloe), is native to Socotra, an island east of Somalia. Closely related to *A. perryi*, the gray-green *A. vera* (Barbados or burn aloe) is employed worldwide as a household remedy for minor burns and wounds. *A. vera* was called “true aloe” in Latin to distinguish it from the unrelated but similarly spiky-leaved Agave (century or tequila) plant, with which Aloe was confused centuries ago. (Copyright © the American Society of Anesthesiologists’ Wood Library-Museum of Anesthesiology.)

George S. Bause, M.D., M.P.H., Honorary Curator and Laureate of the History of Anesthesia, Wood Library-Museum of Anesthesiology, Schaumburg, Illinois, and Clinical Associate Professor, Case Western Reserve University, Cleveland, Ohio. UJYC@aol.com.