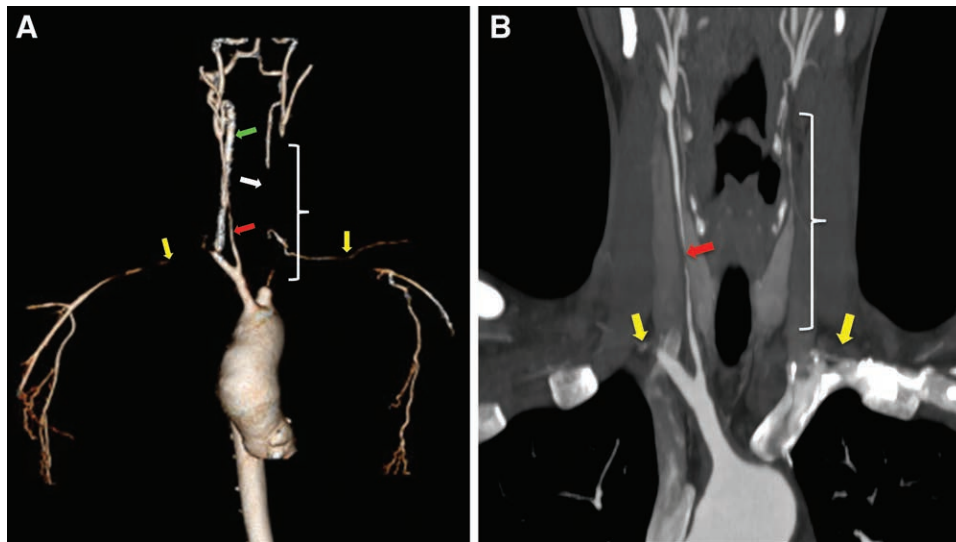


# Takayasu Arteritis and Complete Aortic Arch Branch Vessel Occlusions

Shane M. Gillespie, D.O., Stephen M. Broski, M.D., David W. Barbara, M.D.



**T**AKAYASU arteritis is a large vessel vasculitis of the aorta and its primary branches.<sup>1</sup> Severe cases may involve complete occlusion of aortic arch branch vessels as noted in the computerized tomography from this 28-yr-old woman. Three-dimensional (A) and coronal (B) images from a contrast-enhanced computerized tomography demonstrate irregular severe stenosis of the right common carotid artery (red arrows) and complete occlusions of bilateral subclavian arteries (yellow

arrows), the left common carotid artery (white brackets), and the left vertebral artery (white arrow in A). Note the hypertrophied right vertebral artery (green arrow in A), providing the majority of intracranial blood flow. Due to these severe arterial occlusions, she developed visual deficits with neck movement, presyncope, and arm claudication.

Although Takayasu arteritis typically is treated with glucocorticoids and immunosuppressants,<sup>1,2</sup> this patient underwent bilateral carotid artery bypasses given severe symptomatology despite optimal medical management. Anesthetic considerations related to the image findings entail femoral arterial blood pressure monitoring and meticulous attention to head and neck positioning to mitigate cerebral blood flow compromise. If permissible by the planned operation, an awake patient's cognition may be a valuable monitor of adequate cerebral perfusion. If laryngoscopy is required, such as with this patient, preinduction neck position must be maintained with a technique such as in-line immobilization. Finally, electroencephalogram and cerebral oximetry can be utilized to ensure patient positioning does not compromise cerebral blood flow and also can guide therapies such as blood pressure augmentation and/or electroencephalographic burst suppression with anesthetics during times of surgical arterial clamping.<sup>2,3</sup>

## Competing Interests

The authors declare no competing interests.

## Correspondence

Address correspondence to Dr. Barbara: Barbara.David@mayo.edu

## References

- Schmidt J, Kermani TA, Bacani AK, Crowson CS, Cooper LT, Matteson EL, Warrington KJ: Diagnostic features, treatment, and outcomes of Takayasu arteritis in a US cohort of 126 patients. *Mayo Clin Proc* 2013; 88:822–30
- Yoshida M, Yamamoto T, Shiiba S, Harano N, Sago T, Nunomaki M, Watanabe S: Anesthetic management of a patient with Takayasu arteritis. *Anesth Prog* 2016; 63:31–3
- Xiao W, Wang T, Fu W, Wang F, Zhao L: Regional cerebral oxygen saturation guided cerebral protection in a parturient with Takayasu's arteritis undergoing cesarean section: A case report. *J Clin Anesth* 2016; 33:168–72

Charles D. Collard, M.D., served as Handling Editor for this article.

From the Mayo Clinic College of Medicine, Rochester, Minnesota.

Copyright © 2018, the American Society of Anesthesiologists, Inc. Wolters Kluwer Health, Inc. All Rights Reserved. *Anesthesiology* 2018; 128:1005