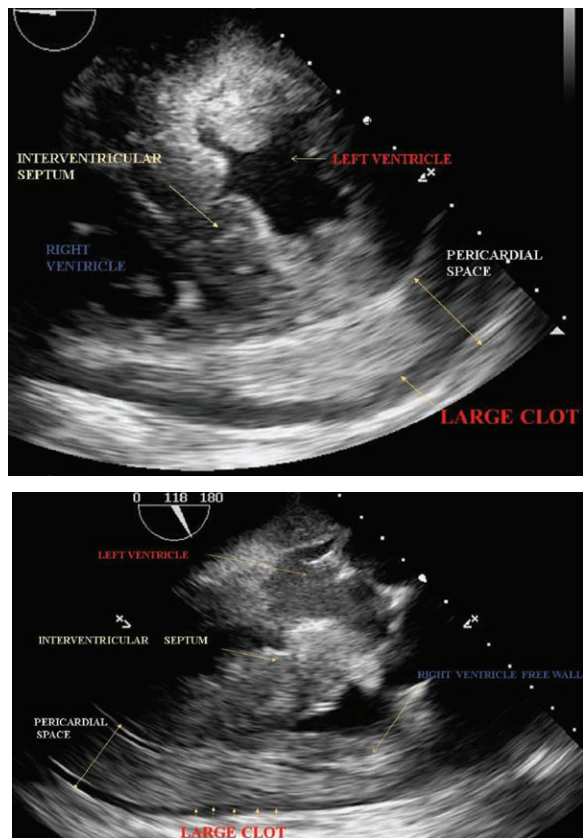


Hemopericardium and Acute Cardiac Tamponade

Sandeep Khanna, M.D., Kamal Maheshwari, M.D., M.P.H.



HEMOPERICARDIUM leading to acute cardiac tamponade is a true emergency. The accompanying transesophageal echocardiography images exhibit such an occurrence. A significant effusion is layering both the ventricles (top panel). A large clot in the pericardial space is compressing the free wall of the right ventricle (bottom panel). Being thin-walled, the right atrium is most prone to compression (see video, Supplemental Digital Content, <http://links.lww.com/ALN/B571>, which demonstrates clot impinging on right atrium). Common causes include malignancy, aortic dissection, myocardial wall rupture, cardiac surgery, and chest trauma.¹⁻³

Rapid bleeding into the pericardial sac overwhelms its capacity to stretch. Consequently, intrapericardial pressures rise acutely, impeding diastolic filling and systolic ejection. Cardiac output decreases precipitously resulting in shock. Tamponade is essentially a clinical diagnosis. Intractable hypotension, tachycardia, jugular venous distension, and pulsus paradoxus suggest the diagnosis. Echocardiography is corroborative. Specific signs include diastolic right ventricular and left atrial collapse.¹⁻³ Differentials include right ventricular myocardial infarction and pulmonary embolism.

Hemodynamic instability necessitates pericardial decompression *via* surgical drainage. Aortic dissection and myocardial wall rupture should be excluded, because decompression may lead to catastrophic exsanguination in these conditions.^{1,2} Anesthetic considerations include liberal volume loading and maintenance of high normal systemic vascular resistance. As endogenous catecholamine response is maximal, the role of inotropes is limited. Invasive arterial monitoring and large-bore IV access are desirable.

Prior to induction, it is prudent to have the surgical team prepare and drape the patient, in readiness for incision. Bradycardia, excessive peak airway pressures, and high positive end-expiratory pressure are scrupulously avoided.³

Competing Interests

The authors declare no competing interests.

Correspondence

Address correspondence to Dr. Khanna: khannas@ccf.org

References

- 2015 ESC Guidelines for the diagnosis and management of pericardial diseases: The Task Force for the Diagnosis and Management of Pericardial Diseases of the European Society of Cardiology (ESC). *Eur Heart J* 2015; 36:2921-64
- Spodick DH: Acute cardiac tamponade. *N Engl J Med* 2003; 349:684-90
- O'Connor CJ, Tuman KJ: The intraoperative management of patients with pericardial tamponade. *Anesthesiol Clin* 2010; 28:87-96

Supplemental Digital Content is available for this article. Direct URL citations appear in the printed text and are available in both the HTML and PDF versions of this article. Links to the digital files are provided in the HTML text of this article on the Journal's Web site (www.anesthesiology.org). Charles D. Collard, M.D., served as Handling Editor for this article.

From the Department of General Anesthesia (S.K., K.M.) and the Department of Outcomes Research (K.M.), Anesthesiology Institute, Cleveland Clinic Foundation, Cleveland, Ohio.

Copyright © 2018, the American Society of Anesthesiologists, Inc. Wolters Kluwer Health, Inc. All Rights Reserved. *Anesthesiology* 2018; 128:1006