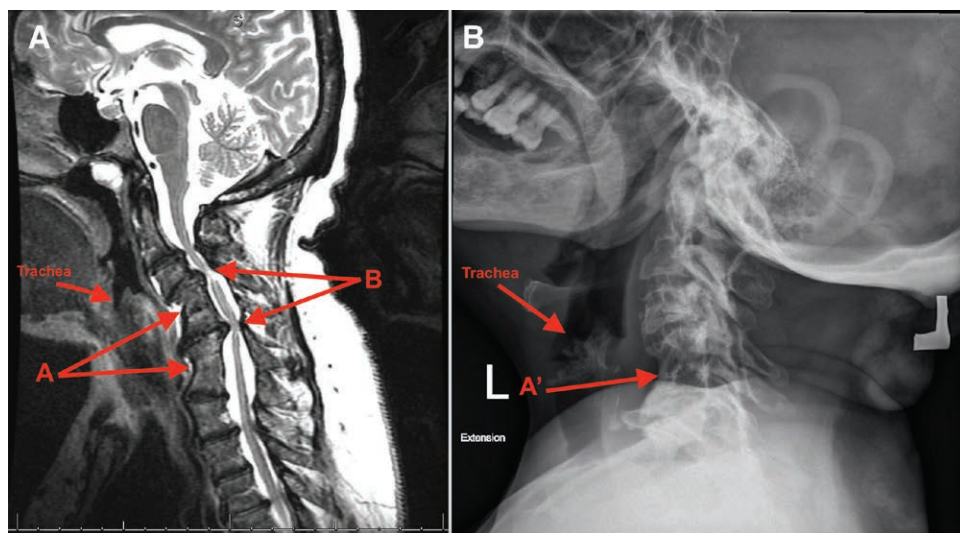


## Cervical Deformity and Potential Difficult Airway Management in Klippel–Feil Syndrome

Mamta Chura, M.B.B.S., Nadine Odo, B.A., E.L.S., Edward Foley, M.D., Vaibhav Bora, M.B.B.S.



**K**LIPPEL–FEIL syndrome presents with a short neck and severe restriction of cervical motion.<sup>1</sup> The accompanying magnetic resonance image demonstrates this neck deformity due to the fusion of cervical vertebrae (image A, arrow A) and severe central canal stenosis (image A, arrow B). A lateral cervical spine X-ray (image B) demonstrates cervical fusion (arrow A') but not the extent of spinal canal narrowing, and thus magnetic resonance imag-

ing or computed tomography better informs preoperative airway assessment. Preoperative review of the imaging is instrumental to objective airway assessment, risk stratification, and development of an airway management plan. During laryngoscopy, the neck should be maintained in a neutral position to prevent hyperextension, which could cause severe neurologic injury.<sup>2</sup> In patients with symptomatic cord compression, an awake fiberoptic intubation is often a better option due to severely limited neck range of motion, atlanto-occipital abnormalities,<sup>1,2</sup> and possible impingement on the spine. The endotracheal tube should be meticulously secured and inline stabilization maintained, especially during procedures that require prone positioning. A laryngeal mask airway can be used to manage a difficult airway; however, it has a limited role in prone positioning. Due to skeletal abnormalities, protective padding should be used to prevent perioperative nerve injury and pressure ulcers. On emergence from anesthesia, a neurologic examination must be performed to ensure integrity of the spinal cord. The presence of congenital cardiac, renal, and other skeletal abnormalities can also affect anesthetic management.<sup>3</sup> Of particular note, kyphoscoliosis may lead to restrictive respiratory mechanics and can cause difficulties and complications when placing spinal or epidural anesthesia.

### Competing Interests

The authors declare no competing interests.

### Correspondence

Address correspondence to Dr. Bora: vbora@augusta.edu

### References

1. Farid IS, Omar OA, Inslar SR: Multiple anesthetic challenges in a patient with Klippel–Feil Syndrome undergoing cardiac surgery. *J Cardiothorac Vasc Anesth* 2003; 17:502–5
2. Daum RE, Jones DJ: Fiberoptic intubation in Klippel–Feil syndrome. *Anaesthesia* 1988; 43:18–21
3. Nargozyan C: The airway in patients with craniofacial abnormalities. *Paediatr Anaesth* 2004; 14:53–9

Charles D. Collard, M.D., served as Handling Editor for this article.

From the Department of Anesthesiology and Perioperative Medicine, Medical College of Georgia, Augusta University, Augusta, Georgia.

Copyright © 2018, the American Society of Anesthesiologists, Inc. Wolters Kluwer Health, Inc. All Rights Reserved. *Anesthesiology* 2018; 128:1007