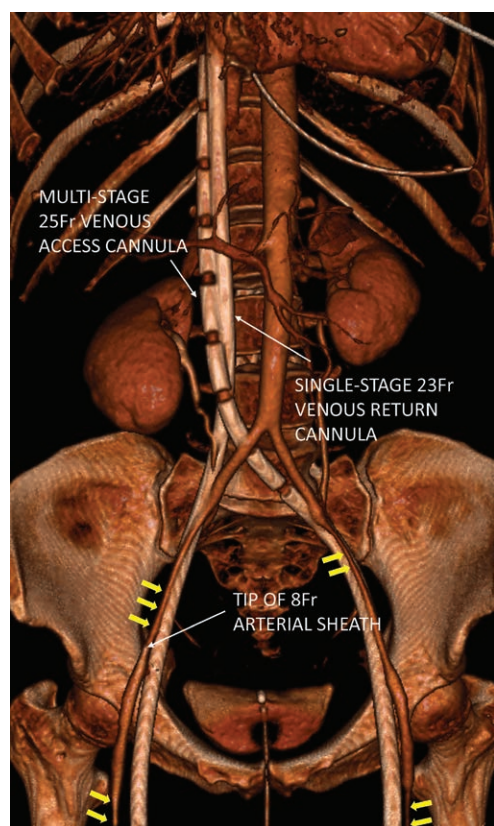


# Profound Vasoconstriction

## Implications for Percutaneous Arterial Access

Daniel G. Taylor, M.B.Ch.B., F.F.I.C.M., Luigi Camporota, M.D., Ph.D.



**I**N the management of severe respiratory failure, veno-venous extracorporeal membrane oxygenation is an increasingly used therapy that presents a unique challenge for anesthesiologists.<sup>1</sup> Veno-arterial-venous extracorporeal membrane oxygenation is emerging as a strategy to treat refractory respiratory failure with coexisting cardiogenic shock.<sup>2</sup> This image demonstrates profound constrictive effects of high-dose vasopressor therapy on arterial caliber and implications for percutaneous arterial access.

The accompanying computed tomography angiogram demonstrates a patient established on veno-venous extracorporeal membrane oxygenation using a bifemoral percutaneous approach. A 25Fr multistage access cannula and a 23Fr return cannula can be seen ascending the inferior vena cava *via* the left and right femoral veins, respectively, with their tips lying at the cavoatrial junction. An 8Fr arterial sheath was inserted percutaneously *via* the right femoral artery at time of extracorporeal membrane oxygenation cannulation to allow rapid arterial access if circulatory support was required in the form of veno-arterial-venous extracorporeal membrane oxygenation; the tip of the arterial sheath is labeled. At time of image acquisition, the patient was on high-dose vasopressor therapy (norepinephrine 0.8 mcg · kg · min and epinephrine 0.5 mcg · kg · min). Severe vasoconstriction of the femoral and iliac arteries can be seen (yellow arrows) and is present bilaterally.

Anesthesiologists should be aware of the importance of gaining arterial access early in a patient on veno-venous extracorporeal membrane oxygenation with coexistent septic cardiomyopathy. Percutaneous arterial access may be very challenging when a patient is on high-dose vasopressor therapy. This image also demonstrates why distal limb perfusion must be monitored closely for ischemic complications if indwelling arterial devices are *in situ*.<sup>3</sup>

### Competing Interests

The authors declare no competing interests.

### Correspondence

Address correspondence to Dr. Taylor: daniel.taylor1@gstt.nhs.uk

### References

1. Fierro MA, Daneshmand MA, Bartz RR: Perioperative management of the adult patient on venovenous extracorporeal membrane oxygenation requiring noncardiac surgery. *ANESTHESIOLOGY* 2018; 128:181–201
2. Vogel DJ, Murray J, Czapan A, Camporota L, Ioannou N, Meadows CIS, Sherren PB, Daly K, Gooby N, Barrett N: Veno-arterio-venous ECMO for septic cardiomyopathy: A single-centre experience. *Perfusion* 2018; 33(1 suppl):57–64
3. Brown SM, Lanspa MJ, Jones JP, Kuttler KG, Li Y, Carlson R, Miller RR III, Hirshberg EL, Grissom CK, Morris AH: Survival after shock requiring high-dose vasopressor therapy. *Chest* 2013; 143:664–71

From the Department of Critical Care, Guy's and St Thomas' National Health Service Foundation Trust, London, United Kingdom.

Copyright © 2018, the American Society of Anesthesiologists, Inc. Wolters Kluwer Health, Inc. All Rights Reserved. *Anesthesiology* 2018; 129:1165