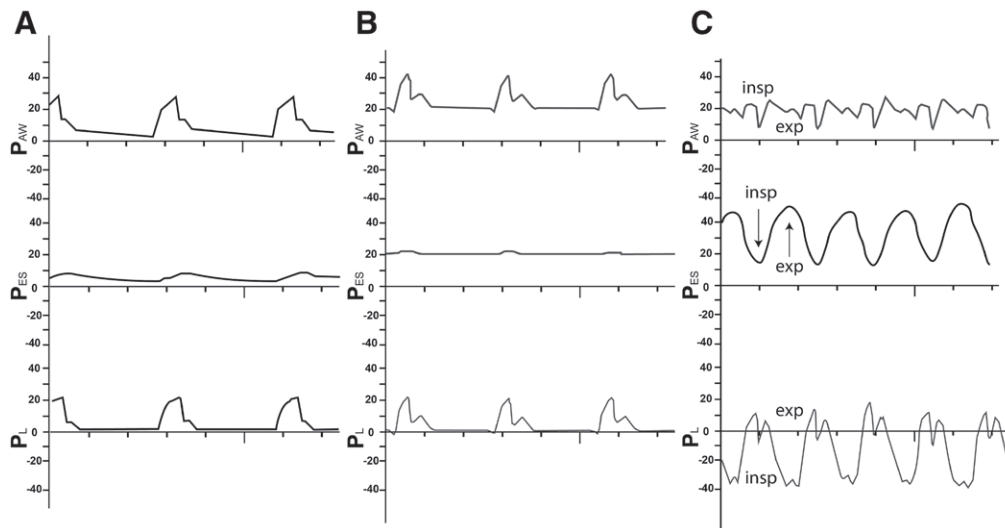


Esophageal Pressure Monitoring in the Critically Ill Obese Subject

Malcolm Lemyze, M.D., Aurélie Guiot, M.D., Maxime Granier, M.D.



A physiologically based ventilator strategy using transpulmonary pressure (PL)—the difference between airway pressure (PAW) and pleural pressure or its surrogate, the esophageal pressure (PES)—is especially interesting for morbidly obese patients whose lungs are trapped between excessive chest fat and a massive abdominal wall, as a bag-in-box respiratory system.^{1,2} The figure displays airway pressure, esophageal pressure, and transpulmonary pressure tracings in a sedated healthy individual (panel A), in a deeply sedated male weighted 139 kg with an abdominal circumference of 140 cm (panel B), and in the same obese subject fighting the ventilator after sedation withdrawal (panel C). In panel B, a positive end-expiratory pressure (PEEP) of 21 cm H₂O was needed to counterbalance the very high esophageal pressure so as to maintain an “open lung” strategy² with a positive PL throughout the respiratory cycle. In panel C, looking at the slightly distorted airway pressure waveforms only, the attending clinician may underestimate the deleterious effects of the patient’s respiratory efforts. An excessive respiratory drive combined with vigorous inspiratory efforts (*insp*, down arrow) and active abdominal muscle contractions against the PEEP (*exp*, up arrow) generates dramatically high esophageal pressure swings that can result in “patient self-inflicted lung injury.”³ Such an abnormal ventilatory pattern with devastating swings of esophageal pressure and transpulmonary pressure after sedation withdrawal can cause life-threatening pulmonary edema and should be rapidly recognized and treated. Sedation and even paralysis are usually required. Esophageal pressure monitoring not

only helps set high PEEP in mechanically ventilated obese patients² but also assists the medical decision-making process during the critical period of the weaning from mechanical ventilation.

Acknowledgment

The authors thank Thibault Colling, Department of Communication, Arras Hospital, France, for his invaluable assistance in designing the figure.

Competing Interests

The authors declare no competing interests.

Correspondence

Address correspondence to Dr. Lemyze: malcolmlemyze@yahoo.fr

References

1. MacIntyre NR: Mechanical ventilation in the context of a “bag-in-box” respiratory system. *Crit Care Med* 2012; 40:1988–9
2. Pirrone M, Fisher D, Chipman D, Imber DA, Corona J, Mietto C, Kacmarek RM, Berra L: Recruitment maneuvers and positive end-expiratory pressure titration in morbidly obese ICU patients. *Crit Care Med* 2016; 44:300–7
3. Brochard L, Slutsky A, Pesenti A: Mechanical ventilation to minimize progression of lung injury in acute respiratory failure. *Am J Respir Crit Care Med* 2017; 195:438–42

From the Department of Critical Care Medicine, Arras Hospital, Arras, France (M.L., M.G.); and the Department of Cardiology, Clinic of Bois Bernard, Rouvroy, France (A.G.).

Copyright © 2019, the American Society of Anesthesiologists, Inc. Wolters Kluwer Health, Inc. All Rights Reserved. *Anesthesiology* 2019; 130:441