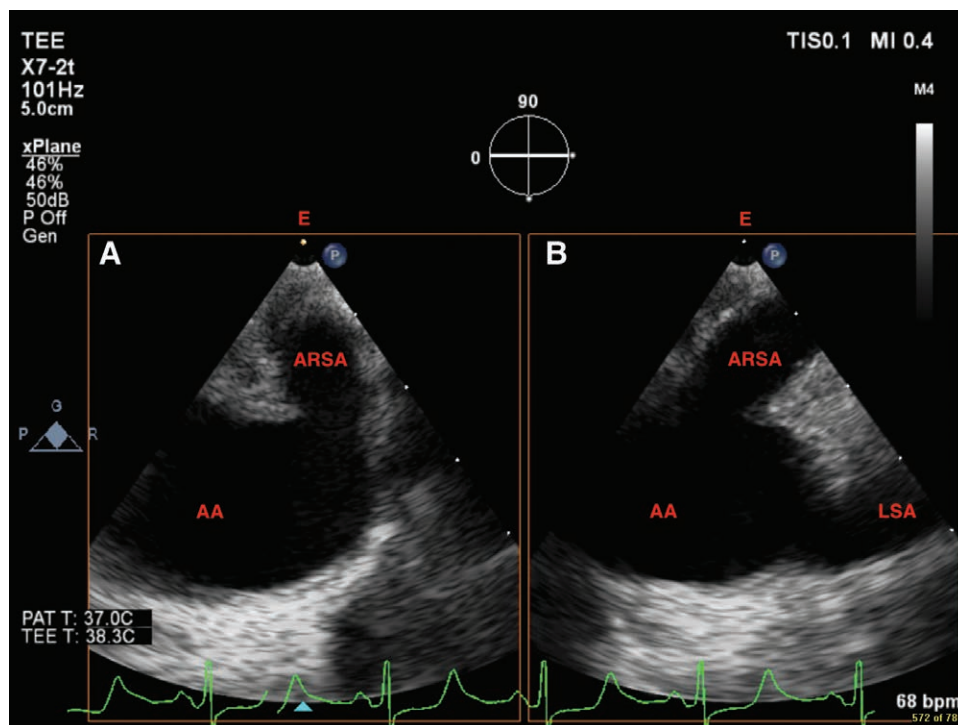
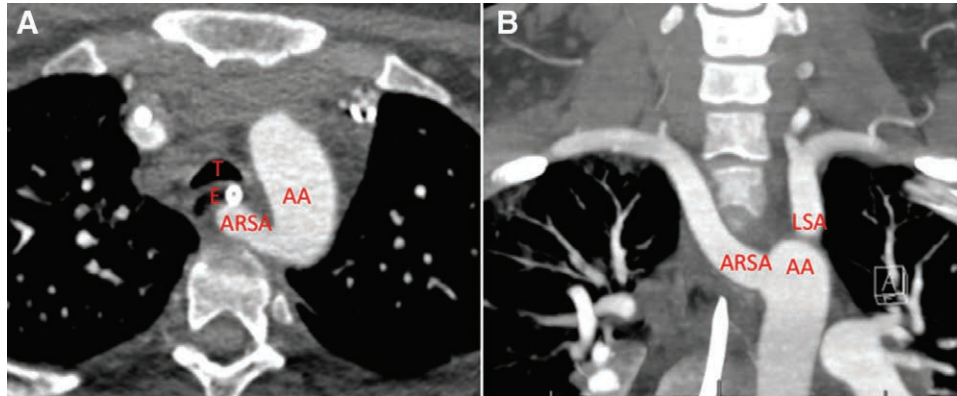


# Aberrant Right Subclavian Artery

## An Important Variant of the Aortic Arch

Rohesh J. Fernando, M.D., F.A.S.E., Jason M. Altman, D.O., Blaine Farmer, M.D., Chandrika Garner, M.D., F.A.S.E.



**A** aberrant right subclavian artery is an uncommon congenital anomaly of the aortic arch with incidence of 0.02 to 1.7%.<sup>1</sup> Aberrant right subclavian artery is generally the last branch of the arch, originating distal to the left subclavian artery.<sup>2</sup> Aberrant right subclavian artery can be diagnosed using

computed tomography and transesophageal echocardiography (TEE). Computed tomography imaging shows aberrant right subclavian artery in the axial (top image, panel *A*; AA, aortic arch; ARSA, aberrant right subclavian artery; E, esophagus; T, trachea) and coronal (top image, panel *B*; LSA, left subclavian

From the Cardiothoracic Section, Department of Anesthesiology, Wake Forest School of Medicine, Medical Center Boulevard, Winston-Salem, North Carolina.

Copyright © 2019, the American Society of Anesthesiologists, Inc. Wolters Kluwer Health, Inc. All Rights Reserved. Anesthesiology 2019; 130:615–6

artery) planes. TEE shows aberrant right subclavian artery in the aortic arch view (bottom image, panel *A*) with the corresponding orthogonal view (bottom image, panel *B*). In 80% of cases, aberrant right subclavian artery travels retroesophageally toward the right arm, as seen on computed tomography in this case (top image, panel *A*). TEE also shows aberrant right subclavian artery coursing toward the esophagus. Less commonly, aberrant right subclavian artery travels between the esophagus and trachea (15%) or anterior to the trachea (5%).<sup>2</sup>

Although often asymptomatic, incidental discovery with imaging is possible and can have important clinical implications. Esophageal compression can occur from aberrant right subclavian artery, termed “dysphagia lusoria.”<sup>2</sup> In children, tracheal compression may lead to aspiration and frequent pulmonary infections, manifesting as cough, dyspnea, and noisy breathing; such compression is unlikely in adults due to tracheal rigidity.<sup>2</sup> Instrumentation of the esophagus should be done carefully to prevent vascular compression while stenting the esophagus open. Kommerell’s diverticulum is an aneurysm at the origin of aberrant right subclavian artery that may cause tracheal compression and/or deviation. The distortion of the airway may lead to difficult intubation and/or lung isolation, particularly with double-lumen tubes.<sup>3</sup> Fiber optic–assisted intubation allows examination of the trachea for compression and excessive posterior arterial pulsations while facilitating intubation.

## Competing Interests

The authors declare no competing interests.

## Correspondence

Address correspondence to Dr. Fernando: rfernand@wakehealth.edu

## References

1. Battaloglu B, Secici S, Colak C, Disli OM, Erdil N, Kutlu R: Aberrant right subclavian artery and axillary artery cannulation in type a aortic dissection repair. *Ann Thorac Surg* 2013; 96:e1–2
2. Gadhinglajkar SV, Sreedhar R, Unnikrishnan M, Varma R: Surgery for dysphagia lusoria caused by right aberrant subclavian artery: Anesthesia perspective. *J Cardiothorac Vasc Anesth* 2005; 19:86–9
3. Mossad E, Farid I, Youssef G, Ando M: Diverticulum of Kommerell: A review of a series and a report of a case with tracheal deviation compromising single lung ventilation. *Anesth Analg* 2002; 94:1462–4