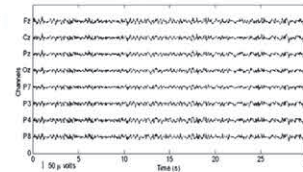
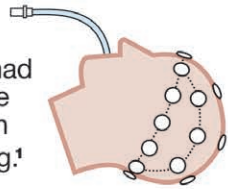


INFOGRAPHICS IN ANESTHESIOLOGY

Complex Information for Anesthesiologists Presented Quickly and Clearly

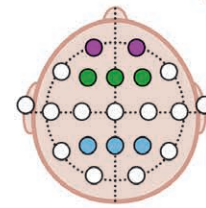
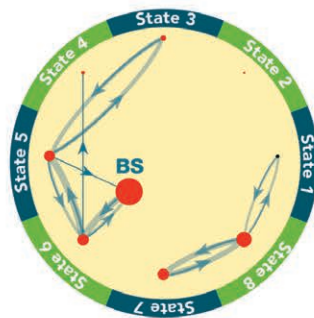
Anesthesia without Surgery: Unconsciousness is Metastable

30 volunteers had 3 h of isoflurane anesthesia with EEG monitoring.¹

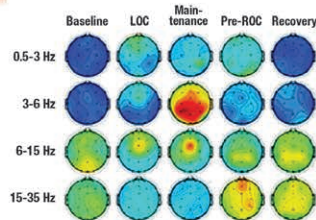


EEG signals were processed and episodes of burst suppression were identified.

Rather than confirming reductions in **frontal-parietal** connectivity, analysis revealed eight distinct functional connectivity states. Transitions between states and burst suppression were measured.



Functional connectivity was measured using weighted phase lag index (wPLI), focused on comparing the **frontal-parietal** and **prefrontal-frontal** cortical regions.



wPLI measures phase synchronization and was assessed before, during, and after steady-state anesthesia. Previous work has suggested that anesthesia decreases **frontal-parietal** connectivity.

Despite steady-state anesthesia, there was no fixed state of activity. Connectivity was metastable, moving between the eight states over seconds to minutes.

These results suggest that single connectivity patterns may not be able to differentiate levels of consciousness.

BS, burst suppression; EEG, electroencephalogram; LOC, loss of consciousness; ROC, return of consciousness.

Infographic created by Jonathan P. Wanderer, Vanderbilt University Medical Center, and James P. Rathmell, Brigham and Women's Health Care/Harvard Medical School. Illustration by Annemarie Johnson, Vivo Visuals. Address correspondence to Dr. Wanderer: jonathan.p.wanderer@vanderbilt.edu. This Infographic has a related article on p. 870.

1. Li D, Viisides PE, Kelz MB, Avidan MS, Mashour GA; ReCCognition Study Group: Dynamic cortical connectivity during general anesthesia in healthy volunteers. *ANESTHESIOLOGY* 2019; 130:870–84