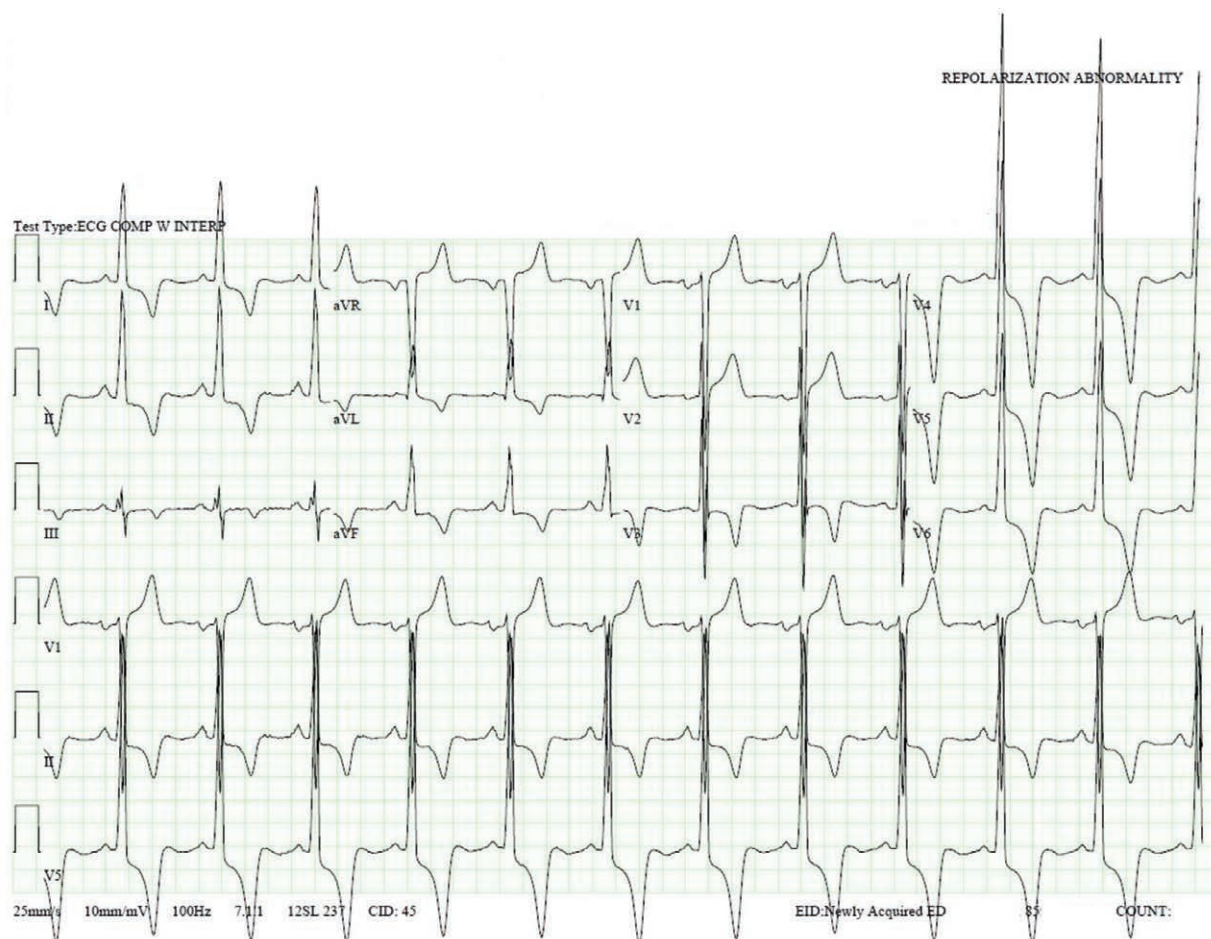


# Giant T-wave Inversions in Apical Hypertrophic Cardiomyopathy

Sandeep Khanna, M.D., Roshni Sreedharan, M.D., Kamal Maheshwari, M.D., M.P.H., Kurt Ruetzler, M.D.



**G**iant T-wave inversion is defined as T-wave inversion that is greater than 10 mm in any electrocardiography lead, whereas global T-wave inversion refers to inverted T waves in all standard leads except augmented voltage right arm (aVR). The accompanying image exhibits these uncommon electrocardiography findings. Anesthesiologists often have to decide whether additional investigations are required in patients who exhibit T-wave inversions in the perioperative period. Nonspecific T-wave inversions occur commonly in surgical patients and are clinically benign.<sup>1</sup> In

contrast, giant negative T waves occur in specific conditions such as left main or equivalent myocardial ischemia and apical hypertrophic cardiomyopathy.<sup>2</sup> Regardless of the degree of T-wave inversion, concomitant presence of chest pain, dyspnea, and ST-segment changes should prompt further cardiac work-up and consultation.<sup>1</sup>

Giant negative T waves in precordial leads V4–V6 in conjunction with tall R waves are frequently found in apical hypertrophic cardiomyopathy. Interestingly, the degree of T-wave inversion correlates well with the severity of

Supplemental Digital Content is available for this article. Direct URL citations appear in the printed text and are available in both the HTML and PDF versions of this article. Links to the digital files are provided in the HTML text of this article on the Journal's Web site ([www.anesthesiology.org](http://www.anesthesiology.org)).

From the Departments of General Anesthesiology (S.K., R.S., K.M., K.R.), Outcomes Research (S.K., K.M., K.R.), and Critical Care Medicine (R.S.), Cleveland Clinic Foundation, Cleveland, Ohio.

Copyright © 2019, the American Society of Anesthesiologists, Inc. All Rights Reserved. *Anesthesiology* 2019; 131:398–9. DOI: 10.1097/ALN.0000000000002732

apical hypertrophy. Echocardiography is corroborative (Supplemental Digital Content, <http://links.lww.com/ALN/B940>).<sup>2</sup>

Apical hypertrophy often severely decreases left ventricular compliance and chamber size. A small and stiff left ventricle impairs diastolic filling enough to compromise stroke volumes despite preserved systolic function. This complicates anesthetic care. Although overzealous fluid administration precipitates cardiogenic pulmonary edema, hypovolemia markedly decreases stroke volume, causing precipitous hypotension. Optimization of hemodynamics relies on preservation of atrial kick, control of heart rate, judicious preloading, and use of vasopressors. Invasive arterial monitoring and transesophageal echocardiography help in decision-making when substantial fluid shifts are anticipated.<sup>3</sup>

### Competing Interests

The authors declare no competing interests.

### Correspondence

Address correspondence to Dr. Khanna: [khannas@ccf.org](mailto:khannas@ccf.org)

### References

1. Breslow MJ, Miller CF, Parker SD, Walman AT, Rogers MC: Changes in T-wave morphology following anesthesia and surgery: A common recovery-room phenomenon. *ANESTHESIOLOGY* 1986; 64:398–402
2. Park SY, Park TH, Kim JH, Baek HK, Seo JM, Kim WJ, Cha KS, Kim MH, Kim YD: Relationship between giant negative T-wave and severity of apical hypertrophy in patients with apical hypertrophic cardiomyopathy. *Echocardiography* 2010; 27:770–6
3. Chapter: Fox JF, Smith MM, Nuttall GA, Oliver WC. Uncommon cardiac diseases, Kaplan's Cardiac Anesthesia, 7th edition. Edited by Kaplan JA, Augoustides JGT, Manecke GR, Maus T, Reich DL. Philadelphia, Elsevier, 2017, pp 909–24