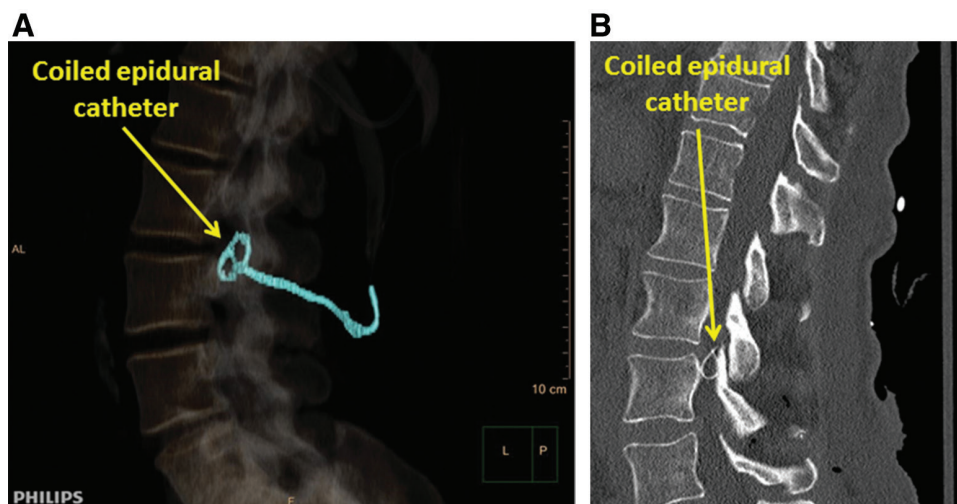


An Impacted Epidural Catheter

Patrick N. Odonkor, M.B., Ch.B., Seema P. Deshpande, M.B., B.S., Andy M. Malinow, M.D.



Rarely, an epidural catheter becomes impacted, causing difficulty upon withdrawal from the patient. Such difficulty has been attributed to “kinking, curling, coiling, knotting and looping” of the epidural catheter in the epidural space¹ or entrapment in muscle, ligaments, joints, or bony structures.^{2,3} If multiple attempts at withdrawal by gentle traction in multiple patient positions is unsuccessful or if the catheter becomes disrupted, leaving a distal fragment in the patient, the impacted epidural catheter should be evaluated by neuraxial imaging¹ using computerized tomography (Supplemental Digital Content 1, <http://links.lww.com/ALN/B932>), magnetic resonance imaging (if there is no metal in the epidural catheter), plain radiography, and/or ultrasonography to determine the mechanism of impaction. A three-dimensional multidetector computerized tomography reconstruction with color enhancement (*panel A*; Supplemental Digital Content 1, <http://links.lww.com/ALN/B932>) provides additional spatial information not seen with traditional computerized tomography imaging (*panel B*), thereby facilitating localization and visualization of the entire length of the retained distal epidural catheter fragment to enhance diagnostic evaluation and guide clinical management.

An impacted but completely buried length of epidural catheter can be managed conservatively with agreement of the asymptomatic patient. Before discharge, the patient should be given a written description of the insertion and attempts at withdrawal of the epidural catheter, the length and location of the impacted epidural catheter, along with copies of pertinent images; all to be shared with physicians

(*e.g.*, anesthesiologists, radiologists, surgeons) during any future medical care. Surgical retrieval is indicated when symptoms (*e.g.*, bleeding, infection, pressure effects) are present, if an impacted length of epidural catheter protrudes from the patient’s skin, or at the insistence of the patient. (Supplemental Digital Content 2, <http://links.lww.com/ALN/B933>.)

Competing Interests

The authors declare no competing interests.

Correspondence

Address correspondence to Dr. Odonkor: podonkor@som.umaryland.edu

References

1. Brichant JF, Bonhomme V, Hans P: On knots in epidural catheters: A case report and a review of the literature. *Int J Obstet Anesth* 2006; 15:159–62
2. Costa C, Fonseca S, Guedes L, Leão A, Sousa A: Epidural catheter anchored in the posterior lateral epidural space: How to manage it. *Rev Esp Anestesiol Reanim* 2018; 65:59–61
3. Ugboma S, Au-Truong X, Kranzler LI, Rigai SH, Joseph NJ, Salem MR: The breaking of an intrathecally-placed catheter during extraction: Case report. *Anesth Analg* 2002; 95:1087–9

Supplemental Digital Content is available for this article. Direct URL citations appear in the printed text and are available in both the HTML and PDF versions of this article. Links to the digital files are provided in the HTML text of this article on the Journal’s Web site (www.anesthesiology.org).

From the University of Maryland School of Medicine, Baltimore, Maryland.

Copyright © 2019, the American Society of Anesthesiologists, Inc. All Rights Reserved. *Anesthesiology* 2019; 131:664. DOI: 10.1097/ALN.0000000000002738