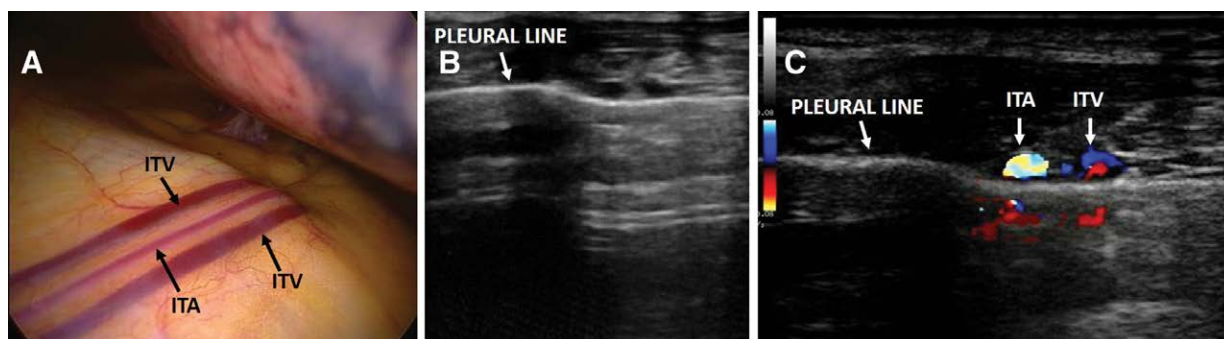


Lung Pulse with Pneumothorax

Examine the Thoracic Artery and Veins

Roberto Copetti, M.D.



The sonographic signs of pneumothorax include the following: presence of lung point(s), absence of lung sliding, absence of B-lines, and absence of lung pulse.¹

The lung pulse, described in 2003,² is the rhythmic movement of the pleura in synchrony with the cardiac rhythm. Its presence indicates that the parietal and visceral pleura oppose one another, and so its presence rules out a pneumothorax. The internal thoracic arteries (ITAs) are a descendant branch of the subclavian artery, are located on both sides of the thorax near the sternum, and are each accompanied by two internal thoracic veins (ITVs), which drain into the subclavian vein. *Panel A* is an image obtained during video-assisted thoracoscopy and shows the internal thoracic artery and the accompanying veins close to the parietal pleura.

Panel B shows a transverse scan performed with linear probe in the right parasternal region in a patient with suspected right pneumothorax. Supplemental Digital Content video 1 (<http://links.lww.com/ALN/B938>) shows a pulsation of the pleural line at this level, and this could be erroneously interpreted as a lung pulse. *Panel C* highlights the

same image with color Doppler that illustrates the internal thoracic artery and one internal thoracic vein. Supplemental Digital Content video 2 (<http://links.lww.com/ALN/B939>) demonstrates that the pulsation of the pleural line is determined by the flow of the two vessels mimicking a lung pulse.

Competing Interests

The author declared no competing interests.

Correspondence

Address correspondence to Dr. Copetti: robcopet@gmail.com

References

1. Husain LF, Hagopian L, Wayman D, Baker WE, Carmody KA: Sonographic diagnosis of pneumothorax. *J Emerg Trauma Shock* 2012; 5:76–81
2. Lichtenstein DA, Lascols N, Prin S, Mezière G: The “lung pulse”: An early ultrasound sign of complete atelectasis. *Intensive Care Med* 2003; 29:2187–92

Supplemental Digital Content is available for this article. Direct URL citations appear in the printed text and are available in both the HTML and PDF versions of this article. Links to the digital files are provided in the HTML text of this article on the Journal's Web site (www.anesthesiology.org).

From the Emergency Department, Cattinara University Hospital, Trieste, Italy.

Copyright © 2019, the American Society of Anesthesiologists, Inc. All Rights Reserved. *Anesthesiology* 2019; 131:666. DOI: 10.1097/ALN.0000000000002756