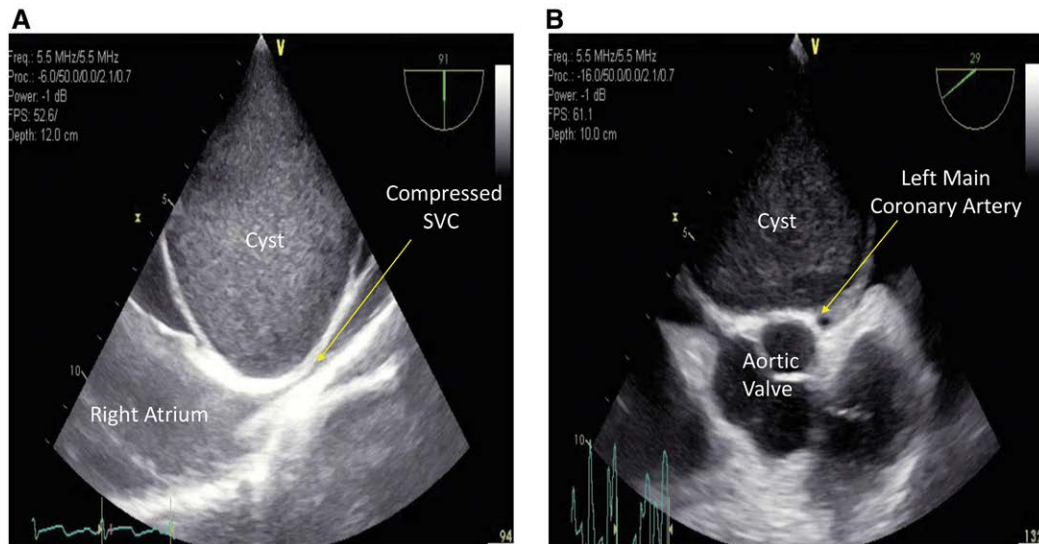


Gigantic Pericardial Bronchogenic Cyst Compressing Superior Vena Cava and Coronary Artery

Christopher Parsons, M.D., Chen B. Zhao, D.O., Jiapeng Huang, M.D., Ph.D.



A 41-yr-old male with intermittent chest pain presented for resection of a pericardial mass. Transesophageal echocardiography showed dramatic compression of the superior vena cava (SVC) to less than 2 mm (*panel A*), significant obliteration of the right pulmonary artery, and intermittent collapse of the left main coronary artery (*panel B*). Pathologic diagnosis was consistent with bronchogenic cyst.

Bronchogenic cysts are relatively rare in adults, and most of these cysts are located within the mediastinum. Presenting symptoms vary significantly based on location and size, ranging from asymptomatic to symptoms due to compression of adjacent structures.¹ Echocardiography played a pivotal role in the diagnosis and management of pericardial cysts to identify which crucial structures are being compressed and what the expected hemodynamic and airway consequences are in the perioperative period.²

In the perioperative period, continuous hemodynamic monitoring with an arterial line shall be established before anesthesia induction due to the unpredictable nature of mass effect on heart and lung. If either vena cava is compressed, central venous access on the opposite side of the diaphragm should be obtained, and adequate volume is administered to avoid complete occlusion of the venous system. Maintaining spontaneous breathing and negative intrapleural pressure might facilitate blood flow through the lungs if the pulmonary artery is affected. Keeping adequate

blood pressure, avoiding tachycardia, and paying attention to ischemic changes are key to preventing catastrophic cardiac arrest when the coronary artery is compromised. In addition, a large pericardial cyst might pressure the tracheo-bronchial tree, and maintaining spontaneous ventilation without muscle relaxant is ideal.³

Competing Interests

The authors declare no competing interests.

Correspondence

Address correspondence to Dr. Huang: jiapenghuang@yahoo.com

References

1. Fievet L, D'Journo XB, Guys JM, Thomas PA, De Lagausie P: Bronchogenic cyst: Best time for surgery? *Ann Thorac Surg* 2012; 94:1695–9
2. Efthymiou CA, Kefaloyannis EM, Thorpe JA: Massive bronchogenic cyst mimicking ischaemic chest pain. *Eur J Cardiothorac Surg* 2008; 34:1260–1
3. Venkatesh BG, Girotra S, Iyer KS, Chakrabarti M, Khurana P, Sen A: Pericardial cyst due to tuberculosis in an adolescent. *Ann Card Anaesth* 2008; 11:116–8

From the Department of Anesthesiology and Perioperative Medicine, University of Louisville, Louisville, Kentucky (C.P., C.B.Z., J.H.), and the Department of Anesthesiology, Jewish Hospital, Louisville, Kentucky (J.H.).

Copyright © 2019, the American Society of Anesthesiologists, Inc. All Rights Reserved. *Anesthesiology* 2019; 131:667. DOI: 10.1097/ALN.0000000000002739