

ANESTHESIOLOGY

Transversus Abdominis Plane Block

A Narrative Review

De Q. Tran, M.D., F.R.C.P.C., Daniela Bravo, M.D.,
Prangmalee Leurcharumee, M.D., Joseph M. Neal, M.D.

ANESTHESIOLOGY 2019; 131:1166–90

Since Rafi's¹ 2001 description, transversus abdominis plane blocks have become one of the most commonly performed truncal blocks.² They can be used to provide postoperative analgesia for open and laparoscopic abdominal surgery as well as inpatient and outpatient surgical procedures.³ Transversus abdominis plane blocks remain a deceptively complex topic. For instance, not only can the transversus abdominis plane compartment be targeted using various approaches and techniques, but its size also requires a judicious dose of local anesthetic to ensure adequate postoperative pain control. More importantly, most approaches for transversus abdominis plane block only provide somatic (*i.e.*, abdominal wall) and not visceral analgesia. Thus, they may confer minimal benefits when compared with standard multimodal or thoracic epidural analgesia.

In this narrative review article, we discuss the anatomy, nomenclature, history, approaches/techniques, pharmacology, and complications of transversus abdominis plane blocks. We also review the evidence supporting their clinical use for common open and laparoscopic surgical procedures. Finally, we explore possible alternative truncal blocks as well as areas requiring further investigation.

Anatomy

The anterolateral abdominal wall encompasses four muscles: the rectus abdominis, external oblique, internal oblique, and transversus abdominis muscles. The transversus abdominis plane compartment is an anatomical plane that contains the T6–L1 thoracolumbar nerves and that can be found between the internal oblique and transversus abdominis muscles.⁴ Anteriorly, the compartment is located between the transversus and rectus abdominis muscles.⁵ Posterolaterally, as the

ABSTRACT

In this narrative review article, the authors discuss the anatomy, nomenclature, history, approaches (posterior vs. lateral vs. subcostal), techniques, pharmacology, indications, and complications of transversus abdominis plane blocks, as well as possible alternative truncal blocks.

Despite the scarcity of evidence and contradictory findings, certain clinical suggestions can nonetheless be made. Overall transversus abdominis plane blocks appear most beneficial in the setting of open appendectomy (posterior or lateral approach). Lateral transversus abdominis plane blocks are not suggested for laparoscopic hysterectomy, laparoscopic appendectomy, or open prostatectomy. However, transversus abdominis plane blocks could serve as an analgesic option for Cesarean delivery (posterior or lateral approach) and open colorectal section (subcostal or lateral approach) if there exist contraindications to intrathecal morphine and thoracic epidural analgesia, respectively.

Future investigation is required to compare posterior and subcostal transversus abdominis plane blocks in clinical settings. Furthermore, posterior transversus abdominis plane blocks should be investigated for surgical interventions in which their lateral counterparts have proven not to be beneficial (*e.g.*, laparoscopic hysterectomy/appendectomy, open prostatectomy). More importantly, because posterior transversus abdominis plane blocks can purportedly provide sympathetic blockade and visceral analgesia, they should be compared with thoracic epidural analgesia for open colorectal surgery. Finally, transversus abdominis plane blocks should be compared with newer truncal blocks (*e.g.*, erector spinae plane and quadratus lumborum blocks) with well-designed and adequately powered trials.

(*ANESTHESIOLOGY* 2019; 131:1166–90)

rectus abdominis tapers to an end, the transversus abdominis plane compartment can be found between the internal oblique and transversus abdominis muscles.

Immediately after exiting from their respective intervertebral foramina, spinal nerves divide into anterior and posterior rami (fig. 1).⁶ In turn, the anterior ramus gives off two main branches: the anterior and lateral cutaneous nerves. The anterior cutaneous branch (from the T6–T11 segments) gives rise to intercostal nerves, which supply the skin and muscles of the anterior abdominal wall.⁴ The T6–T8 intercostal nerves initially travel between the innermost and internal intercostal muscles before entering the transversus abdominis plane compartment at the level of the costal margin.⁴ In the transversus abdominis plane compartment, intercostal nerves display extensive interconnections and anastomosis to form the upper (cephalad) portion of the transversus abdominis plane plexus. The T9–T11 intercostal and T12 subcostal nerves penetrate the transversus abdominis plane compartment posterior to the midaxillary line.⁷ They also interconnect

This article is featured in "This Month in Anesthesiology," page 1A.

Submitted for publication February 9, 2019. Accepted for publication May 13, 2019. From the Department of Anesthesiology, McGill University, Montreal, Quebec, Canada (D.Q.T.); Department of Anesthesiology and Perioperative Medicine, Clinical Hospital of the University of Chile, University of Chile, Santiago, Chile (D.B.); Department of Anesthesiology, Faculty of Medicine, Maharaj Nakorn Chiang Mai Hospital, Chiang Mai University, Chiang Mai, Thailand (P.L.); Department of Anesthesiology, Virginia Mason Medical Center, Seattle, Washington (J.M.N.).

Copyright © 2019, the American Society of Anesthesiologists, Inc. All Rights Reserved. *Anesthesiology* 2019; 131:1166–90. DOI: 10.1097/ALN.0000000000002842

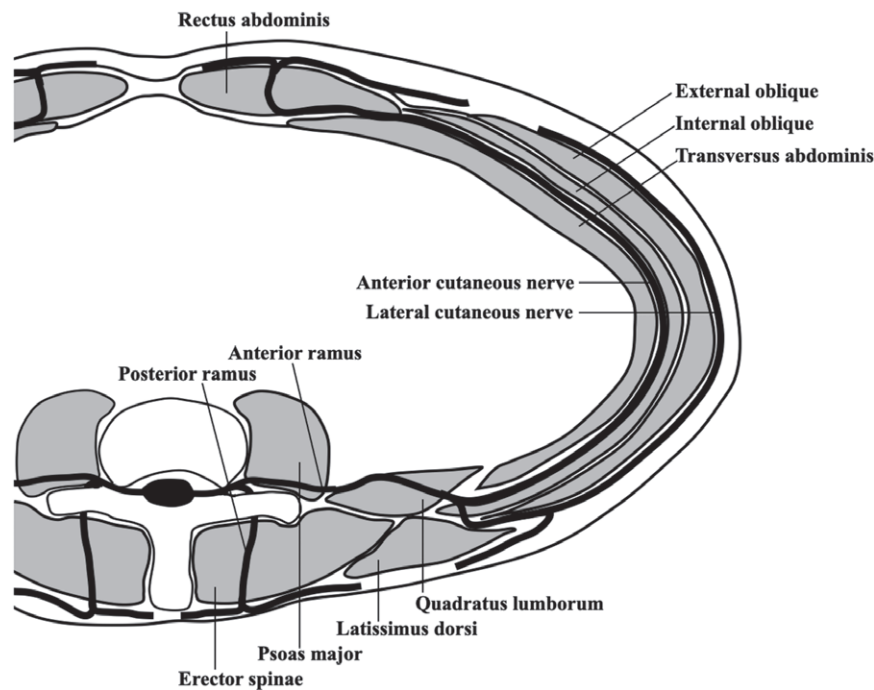


Fig. 1. Transverse section of the lower abdominal wall (at the T12 level) demonstrating the course of a thoracolumbar nerve.

with each other and form the lower (caudad) portion of the transversus abdominis plane plexus. The latter runs along the deep circumflex iliac artery⁴ and enters the rectus sheath at the lateral edge of the rectus abdominis muscle. Within the rectus sheath, the neural plexus runs along the deep inferior epigastric artery. The lower thoracic intercostal and subcostal nerves innervate the skin of the infra-umbilical area between the midline and midclavicular lines.

The lateral cutaneous branches of the T6–T11 spinal nerves depart from their respective anterior rami near the angle of the rib, or around the midaxillary line.^{3,5,6} Thus, the lateral cutaneous branches arise before the main nerves penetrate the lateral transversus abdominis plane compartment (fig. 1). They supply the skin over the lateral abdominal wall between the costal margin and iliac crest.^{5,6,8}

The L1 spinal nerve divides into iliohypogastric and ilioinguinal nerves. Both leave the transversus abdominis plane compartment anterior to the middle third of the iliac crest and lie ventral to the internal oblique muscle and medial to the anterosuperior iliac spine. These nerves supply the anterior abdomen at the level of the inguinal area and the medial thigh.^{5,9}

Nomenclature of Transversus Abdominis Plane Blocks

The transversus abdominis plane compartment can be accessed using various approaches and techniques. For the purposes of this review article, the term *approach* refers to

the anatomical site *where* the transversus abdominis plane compartment is targeted. The term *technique* refers to *how* (i.e., loss-of-resistance, ultrasound guidance, direct surgical vision) the compartment is identified for a given approach.

The nomenclature pertaining to approaches remains controversial.¹⁰ For the sake of simplicity and clarity, the current review employs a modified version of the 2015 classification proposed by Hebbard.¹¹ The *subcostal* approach targets the transversus abdominis plane compartment in the anterior abdominal wall (beneath the costal margin as its name implies) anywhere between the xyphoid process¹² and the anterosuperior iliac spine (fig. 2).¹³ The *lateral* approach targets the transversus abdominis plane compartment in the lateral abdominal wall between the midaxillary¹⁴ and anterior axillary¹⁵ lines (fig. 3). Finally, the *posterior* approach targets the transversus abdominis plane compartment at the level of the lumbar triangle of Petit¹ or the anterolateral aspect of the quadratus lumborum muscle (fig. 4).¹⁶

History of Transversus Abdominis Plane Blocks

Beyond simple academic interest, a discussion of the circuitous history of transversus abdominis plane blocks allows clinicians to understand the practical problems that led to the development of the different approaches. Furthermore, the chronology eloquently illustrates the possible continuum that exists between (posterior) transversus abdominis plane blocks and its more modern counterparts (e.g., quadratus lumborum blocks).

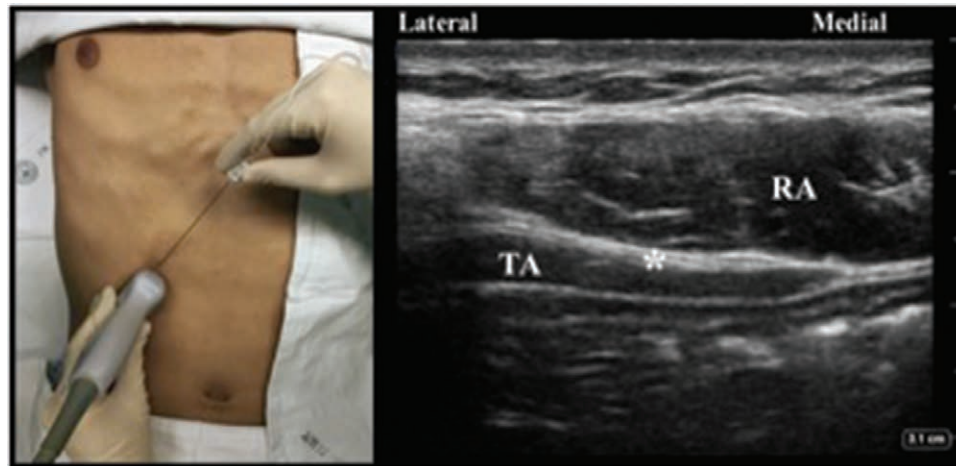


Fig. 2. Ultrasound probe position, needle puncture site, and sonographic image of the subcostal transversus abdominis plane block. Asterisk indicates needle target; RA, rectus abdominis muscle; TA, transversus abdominis muscle.

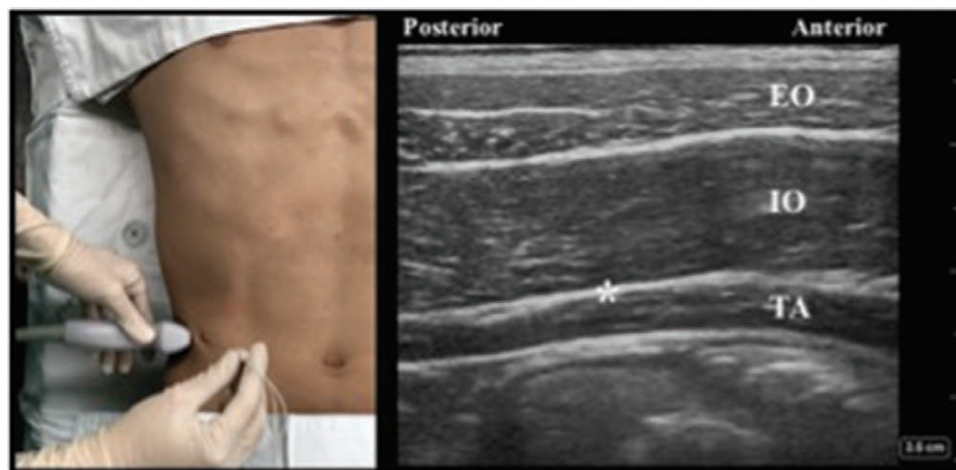


Fig. 3. Ultrasound probe position, needle puncture site, and sonographic image of the lateral transversus abdominis plane block. Asterisk indicates needle target; EO, external oblique muscle; IO, internal oblique muscle; TA, transversus abdominis muscle.

The first description of transversus abdominis plane block is generally credited to Rafi, who, in 2001, advocated the performance of abdominal field block at the level of the lumbar triangle of Petit. Rafi suggested using a blunt needle and a single pop sensation to identify the intermuscular plane between the internal oblique and transversus abdominis muscles, a compartment purported to contain the 7th to 11th intercostal nerves, the subcostal nerve, as well as the ilioinguinal and iliohypogastric nerves.¹ In 2006, O'Donnell¹⁷ introduced the term *transversus abdominis plane block* into the literature. He also modified Rafi's original description by advocating a double pop technique to identify the planes between fascial extensions of the external oblique muscle

and the internal oblique (first pop),¹⁸ and between the internal oblique and transversus abdominis muscles (second pop).¹⁷

The next technical development occurred in 2007: because the triangle of Petit can be difficult to identify in obese patients (because of its increased depth) and elderly subjects (because of a loss in muscle mass), Hebbard *et al.*¹⁴ advocated the use of ultrasound guidance to identify the different intermuscular planes. Hebbard *et al.*¹⁴ also favored a puncture site on the midaxillary line (instead of the triangle of Petit) to facilitate visualization of the abdominal wall. The technique proposed by Hebbard *et al.*¹⁴ was indeed easy to master, as experience with only 16 blocks was required

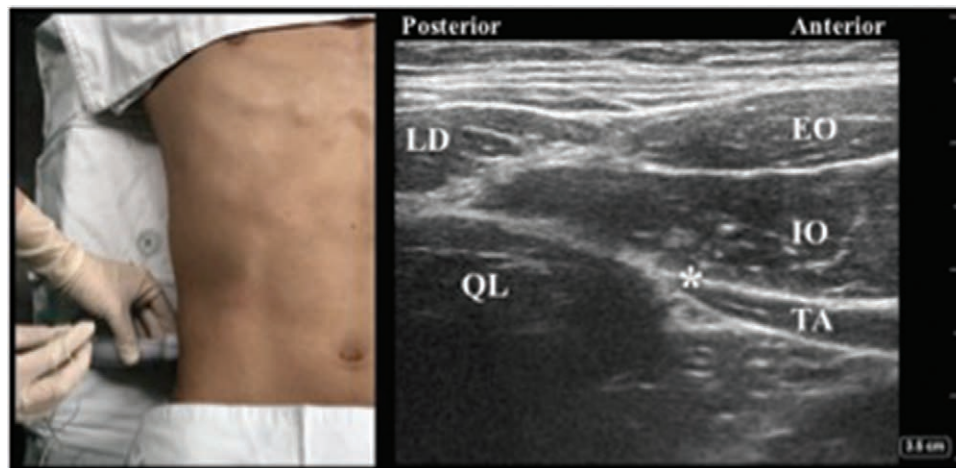


Fig. 4. Ultrasound probe position, needle puncture site, and sonographic image of the posterior transversus abdominis plane block. Asterisk indicates needle target; EO, external oblique muscle; IO, internal oblique muscle; LD, latissimus dorsi muscle; QL, quadratus lumborum muscle; TA, transversus abdominis muscle.

to achieve 90% proficiency.¹⁹ Unfortunately, clinical experience^{12,20} and cadaveric investigation²¹ soon revealed that lateral transversus abdominis plane blocks cover mainly the T10 to L1 dermatomes, thereby confining their usefulness to lower abdominal surgery.

Dissatisfaction with the lateral approach spearheaded the search for better alternatives. Two (opposite) schools of thought arose. In one camp, propelled by Hebbard's subsequent 2008 report,¹² operators started experimenting with an ultrasound-guided subcostal approach for transversus abdominis plane blocks. With this method, the initial needle insertion begins near the xyphoid process and the local anesthetic is deposited between the rectus abdominis and transversus abdominis muscles. Subsequently, the needle is directed inferolaterally along the costal margin toward the anterosuperior iliac spine with incremental local anesthetic injection to distend the transversus abdominis plane compartment.¹² A 2010 confirmatory study by Lee *et al.*²² demonstrated that, compared with its lateral counterpart, the new subcostal approach anesthetized an increased number of dermatomes (4 *vs.* 3) and yielded a higher peak of sensory blockade (T8 *vs.* T10).

In contrast, proponents of the ultrasound-guided posterior approach advocated displacing the puncture site posterior to the midaxillary line to target the anterolateral border of the quadratus lumborum muscle. The earliest description of posterior transversus abdominis plane blocks can be traced back to a 2011 study by Carney *et al.*¹⁶ In it, the authors credited a personal communication with Dr. Rafael Blanco for the concept. In Carney *et al.*'s study, volunteers underwent ultrasound-guided posterior transversus abdominis plane blocks: local anesthetic and contrast solution were deposited at the intersection of the oblique/transversus abdominis muscles and the quadratus lumborum muscle, superficial to the transversalis

fascia. On subsequent magnetic resonance imaging, contrast spread reached the T6–T10 paravertebral spaces.¹⁶ These findings seem to suggest that the mechanism of action of the posterior approach could be dual: blockade of the thoracolumbar nerves in the transversus abdominis plane compartment and local anesthetic spread around the quadratus lumborum muscle to the paravertebral space. Interestingly, the injection site posterior to the midaxillary line was not only reminiscent of Rafi's¹ original description but also of the lateral (*i.e.*, type 1) quadratus lumborum block described by Blanco.²³ This has prompted some authors to ponder whether the posterior transversus abdominis plane block is in fact a mislabeled quadratus lumborum block.²⁴ Such a parallel appears logical but remains unproven, as preliminary studies revealed that, contrarily to posterior transversus abdominis plane blocks,¹⁶ local anesthetic injected in the setting of lateral quadratus lumborum blocks does not spread to the paravertebral spaces.^{25,26}

In summary, the landmark-guided posterior approach constitutes the original method for transversus abdominis plane block. Over the last decade, technical difficulty and the search for more extensive (upper) abdominal wall anesthesia led to the subsequent development of ultrasound-guided lateral and subcostal approaches, respectively. In recent years, things seem to have come full circle with the (re)discovery of the (ultrasound-guided) posterior approach. The latter may share some similarities with the lateral quadratus lumborum block.

Approaches and Techniques for Transversus Abdominis Plane Blocks

Optimal Approach for Transversus Abdominis Plane Blocks

Before 2014, no randomized trial had compared the subcostal, lateral, and posterior approaches head-to-head in

clinical settings, and much of the knowledge was inferred from cadaveric²⁷ and volunteer^{16,22} investigations as well as meta-analyses.²⁸ For instance, in a cadaveric study ($n = 13$), Milan *et al.*²⁷ injected 40 ml of dye under direct vision in the subcostal, lateral and posterior transversus abdominis plane compartments. These authors then traced the area of dye spread onto clear plastic, which was then photographed. Milan *et al.*²⁷ found that the spread was greatest for the subcostal approach (85 cm²) followed by its posterior (78 cm²) and lateral (59 cm²) counterparts, with statistical significance reached for the difference between subcostal and lateral approaches. These findings echoed the results of a 2010 volunteer study by Lee *et al.*,²² who reported a higher number of dermatomes (4 *vs.* 3) anesthetized with the subcostal compared to the lateral approach.

Based on preliminary studies, the pattern of spread also seems to differ between approaches. In a volunteer study, Carney *et al.*¹⁶ observed (with magnetic resonance imaging) that levobupivacaine-gadolinium injected with the lateral and subcostal approaches remained in the transversus abdominis plane compartment. In contrast, the mixture reached the quadratus lumborum muscle and T5–L1 paravertebral spaces with the posterior approach. Subsequently, in a 2013 meta-analysis, Abdallah *et al.*²⁸ reported that, compared with placebo, the posterior approach results in decreased pain and breakthrough opioid consumption during the first 48 h after lower abdominal surgery. Such benefits do not seem to occur with the lateral approach.²⁸ Abdallah *et al.*²⁸ speculated that the improved pain control seen with posterior transversus abdominis plane blocks stems from paravertebral local anesthetic spread, which results in sympathetic block and, consequently, improved visceral analgesia.

Since 2014, six randomized controlled trials have compared the different approaches for transversus abdominis plane blocks in the setting of laparoscopic cholecystectomy^{29–32} Cesarean delivery³³ and laparoscopic gynecologic surgery.³⁴ Overall, these randomized controlled trials confirmed the knowledge derived from previous volunteer and cadaveric studies. For instance, in four trials, compared with their subcostal counterparts, lateral transversus abdominis plane blocks expectedly resulted in higher pain scores during the first 24 h after laparoscopic cholecystectomy.^{29–32} Furthermore, lateral transversus abdominis plane blocks anesthetized fewer dermatomes³⁴ and also proved inferior to posterior transversus abdominis plane blocks for Cesarean delivery due to increased pain scores at rest (during the first 24 h), shorter analgesic duration and decreased patient satisfaction.³³

In summary, based on the current knowledge, we suggest using the subcostal and posterior approaches instead of the lateral approach. Future randomized investigation is required to compare subcostal and posterior transversus abdominis plane blocks. In recent years, to circumvent the shortcomings associated with the lateral approach, some

operators have advocated combining the latter with the subcostal approach thereby creating a multiple quadrant injection method.^{35–37} Although this strategy results in more widespread dermatomal anesthesia than the targeted lateral approach,³⁶ we suggest caution with local anesthetic dosing, especially in subsets of patients at risk for local anesthetic systemic toxicity (*e.g.*, elderly, children, individuals with low muscle masses). One possible strategy consists in retaining conventional volumes of local anesthetic but using more dilute concentrations (*e.g.*, bupivacaine 0.2%) with epinephrine.

Optimal Technique for Transversus Abdominis Plane Blocks

The transversus abdominis plane compartment can be located with landmarks or ultrasound guidance. Alternately, it can also be identified intraoperatively by surgeons.

To date, the landmark-guided technique has been used exclusively for the posterior approach.^{1,8,17} Although still employed by some authors,³⁸ it can be fraught with technical challenges. The landmark-guided technique requires two fundamental steps: identification of the lumbar triangle of Petit and recognition of the intermuscular plane between the internal oblique and transversus abdominis muscles with tactile pops. Unfortunately, the triangle of Petit can be difficult to palpate in obese patients,^{1,39} and its position varies significantly between individuals.^{7,40} Furthermore, in 17.5% of patients, it can be absent because the external oblique overrides the latissimus dorsi muscle.⁴¹ To complicate matters further, the technical endpoint (pop sensation) remains debated. Although some experts advocate the search of two distinct pops,¹⁷ others use only a single pop, as the initial crossing of fascial extensions of the external oblique muscle (theoretically the first pop) may be too subtle to be felt.³⁸ In fact, in 36 patients undergoing bilateral transversus abdominis plane blocks, McDermott *et al.*⁴² reported that the double pop endpoint resulted in correct needle position in only 24% of cases (as assessed by ultrasound guidance). Alarming, in 18% of the time, the needle tip inadvertently breached the peritoneum.⁴² Thus, despite the lack of randomized controlled trials comparing landmark and ultrasound techniques, the potential for visceral injury⁴³ has led many authors to favor the use of ultrasound guidance for transversus abdominis plane blocks.^{42,44,45}

To date, no randomized, controlled trial has investigated the optimal technique for ultrasound-guided transversus abdominis plane blocks in clinical settings. However, preliminary cadaveric studies suggest that, for the lateral approach, a minimal volume of 15 ml is required⁴⁶ and, for the subcostal approach, a multiple-injection technique (along the costal margin) provides more extensive coverage than its single injection counterpart.⁴⁷

In 2010, West *et al.*⁴⁸ and Araco *et al.*⁴⁹ described for the first time the intraoperative performance of transversus abdominis plane blocks by surgeons. Since these initial

reports, multiple instances of surgical transversus abdominis plane blocks have been published. In fact, the number of permutations of transversus abdominis plane blocks is much greater with surgical than with (anesthesiologist-driven) percutaneous methods. For instance, like anesthesiologists, surgeons can target all three (subcostal, lateral, and posterior) transversus abdominis plane compartments^{48,50} in the setting of open (laparotomy)⁴⁸ or laparoscopic⁵¹ incisions. However, they can also perform transversus abdominis plane blocks by going through the abdominal wall^{48,50,51} or through the peritoneum.^{52,53} Furthermore, unlike anesthesiologists, they can identify the transversus abdominis plane compartment using conventional tactile feel,⁴⁸ intraoperative ultrasound,⁵⁴ or direct vision with actual dissection of the oblique muscles⁴⁹ or peritoneum.⁵⁵ Unfortunately, no trial has elucidated the optimal technique for surgical transversus abdominis plane blocks.

To date, four randomized controlled trials (Jadad scores of at least 3) have compared surgeon- and anesthesiologist-performed transversus abdominis plane blocks.^{56–59} In three studies investigating subcostal transversus abdominis plane blocks performed for laparoscopic cholecystectomy,⁵⁶ and lateral transversus abdominis plane blocks performed for Cesarean delivery⁵⁸ or laparoscopic colorectal surgery,⁵⁷ surgical and anesthesiologist-driven transversus abdominis plane blocks provided similar postoperative analgesia and breakthrough opioid consumption. However the surgical technique resulted in a 60 to 80% decrease in performance time.^{56,58} In contrast, in one trial investigating minimally invasive colorectal surgery, surgical lateral transversus abdominis plane blocks resulted in similar pain scores but 17.2-mg-lower intravenous morphine consumption at 48 h than their anesthesiologist-performed counterparts.⁵⁹

In summary, based on the current knowledge, we suggest foregoing landmark guidance in favor of ultrasound for the performance transversus abdominis plane blocks. Surgical transversus abdominis plane blocks constitute an interesting alternative to their anesthesiologist-performed counterparts, as they result in comparable analgesia but require a shorter performance time. Further investigation is required to elucidate the optimal technique for ultrasound as well as surgical transversus abdominis plane blocks.

Pharmacology of Transversus Abdominis Plane Blocks

Transversus abdominis plane blocks display rapid first phase absorption kinetics,^{60–63} and can lead to elevated plasmatic concentrations of total and unbound fractions of local anesthetic. Compared with other truncal blocks (*e.g.*, rectus sheath block), transversus abdominis plane blocks may result in a 50% shorter time to maximum serum concentration. The latter most likely stems from the large, highly vascularized absorptive surface area.^{62,64} Furthermore, accidental intramuscular injection (inside the internal oblique or transversus abdominis muscle) could lead to even faster

local anesthetic uptake.⁶⁵ All these factors may predispose to local anesthetic systemic toxicity.^{66,67}

Pharmacokinetics of Single Dose of Local Anesthetic

Multiple trials have assessed local anesthetic plasmatic concentrations after boluses of ropivacaine,^{36,60–63,68–74} levobupivacaine,^{75–78} and bupivacaine.^{79,80} The reported mean time to maximum serum concentration ranged from 10 to 35 min. However delayed absorption can occasionally occur with a time to maximum serum concentration as high as 240 min.⁷⁹ With increasing local anesthetic doses, a clear dose-dependent trend in maximum plasma concentration emerges. However the time to maximum serum concentration remains constant.⁸⁰

Although local anesthetic plasmatic levels often exceed known toxic thresholds in many cases, only a minority of patients seems to display signs of local anesthetic toxicity. This could be explained by the fact that, in many trials, patients were under general anesthesia at the time of maximum plasma concentration. Interestingly, many reported cases of local anesthetic toxicity originate from two trials performed in obstetrical patients undergoing Cesarean delivery.^{69,80} This strengthens the argument that the calculation of local anesthetic dosing should perhaps be based on lean rather than real (*i.e.*, pregnant) body weight.^{66,69} Conversely, elevated plasma levels have been reported in patients receiving doses that would traditionally be considered safe (*e.g.*, 2.1 mg/kg of ropivacaine).⁶⁸ Therefore the discrepancy between local anesthetic dosage and (toxic) plasma levels underscores the complex interaction between bound and unbound local anesthetic concentrations.^{68,80}

The impact of epinephrine (up to 5 µg/ml) on local anesthetic systemic absorption for transversus abdominis plane block has been addressed in two studies. These trials demonstrated 35% maximum plasma concentration decreases and time to maximum serum concentration prolongations ranging from 18.5 to 44 min with the addition of epinephrine to the local anesthetic mix.^{62,75}

Pharmacokinetics of Continuous Infusion of Local Anesthetic

To date, only two trials have investigated local anesthetic pharmacokinetics in the setting of continuous transversus abdominis plane blocks.^{81,82} In these studies, the time to maximum serum concentration for the infusion occurred at 48 h and 72 h for the subcostal and posterior approach, respectively. However, the unbound maximum plasma concentration peaked earlier (within 24 h) and remained steady thereafter.

Optimal Local Anesthetic Agent

To date, one randomized controlled trial (published in English) has investigated the optimal local anesthetic for transversus abdominis plane blocks. In 2016, Sinha *et al.*⁸³ compared bupivacaine 0.25% and ropivacaine 0.375% for transversus abdominis plane blocks in patients undergoing

laparoscopic cholecystectomy. Although the ropivacaine group displayed lower pain scores during the first postoperative hour, both drugs were equivalent in terms of the 24-h cumulative analgesic requirement.⁸³

Optimal Local Anesthetic Dose

When it comes to the selection of an optimal local anesthetic dose for transversus abdominis plane blocks, little definitive information is available. A recent meta-analysis compared high dose (greater than 50 mg of bupivacaine equivalents) with low dose (less than or equal to 50 mg of bupivacaine equivalents) of long-acting local anesthetic and found no intergroup differences in terms of analgesia, 6-h or 24-h opioid consumption, time to first analgesic request, and patient satisfaction.⁸⁴ To date, very few dose-finding studies have investigated the ED50 for transversus abdominis plane blocks. This dearth of evidence may be attributed to the difficulty in carrying out such studies in light of the significant interindividual variability in analgesic effect. In one trial, the ED50 for ropivacaine in adults was 2.7 mg/kg, a dose for which toxicity has been previously reported.⁸⁵ In children, the ED50 of levobupivacaine was found to be 0.22 mg/kg,⁸⁶ and the EC50 of bupivacaine, 0.08239%.⁸⁷

Local anesthetic dose constitutes the mathematical product of concentration and volume. In the literature, multiple trials have compared different local anesthetic concentrations (using constant volumes). Overall, these studies revealed minimal differences between low (0.125 to 0.25%) and high (0.5 to 0.75%) concentrations of bupivacaine, levobupivacaine, and ropivacaine in terms of postoperative pain and rescue analgesic consumption.^{88–94} In terms of volume, large injectates (15 to 30 ml per side in adults; 0.1 to 1 ml/kg per side in children) are commonly used to ensure adequate local anesthetic spread for transversus abdominis plane blocks.^{78,79,84,95} Although the minimal effective volume remains unknown, a trend toward superior analgesia was demonstrated with at least 15 ml per side in a meta-analysis conducted by Abdallah *et al.*⁹⁶ These findings concord with those of a subsequent cadaveric study, which reported that, compared with lower volumes, 15 ml can provide more extensive cephalo-caudal spread.⁴⁶ Finally, the overall local anesthetic dose seems to matter more than either concentration or volume alone, as differences in volumes carry minimal analgesic impact in the setting of a constant local anesthetic dose.^{78,97,98}

Optimal Local Anesthetic Infusion Strategy

In the literature, two trials have compared continuous local anesthetic infusion with intermittent local anesthetic boluses (without a background infusion). In the first study, compared with a continuous infusion (8 ml/h of ropivacaine 0.2%), 20-ml aliquots every 8 h proved to be more economical because of lower local anesthetic daily

requirement.⁹⁹ Furthermore, the intermittent bolus-group maintained similar block coverage on postoperative days 1 and 2, whereas its continuous infusion counterpart displayed a regression of two dermatomal segments.⁹⁹ A second trial simultaneously applied both strategies in volunteers¹⁰⁰; one side received a continuous infusion of ropivacaine 0.2% at 8 ml/h, whereas the other side received intermittent boluses (24 ml of ropivacaine 0.2% every 3 h). The primary outcome, block extension at 6 h, was similar in both groups; however, there was a significant difference at various time points between 0 and 5 h favoring intermittent boluses.

Optimal Adjuvants

In the literature, several adjuvants (*i.e.*, dexamethasone, alpha-2 agonists, magnesium, opioids, liposomal formulation) have been investigated to prolong the duration of transversus abdominis plane blocks.

Dexamethasone is commonly used for peripheral nerve blocks.¹⁰¹ A 2018 meta-analysis concluded that, compared with saline, perineural dexamethasone (4 to 8 mg) can increase the duration of transversus abdominis plane blocks by almost 3 h while reducing breakthrough analgesic consumption and postoperative nausea and vomiting.¹⁰² To date, the optimal dose and mode of administration (intravenous *vs.* perineural) have not been investigated for transversus abdominis plane blocks.

Alpha-2 agonists (*i.e.*, clonidine and dexmedetomidine) have also been used as adjuvants for transversus abdominis plane blocks. Clonidine has been investigated in the setting of transversus abdominis plane blocks performed for Cesarean delivery. Compared with plain bupivacaine, analgesia was prolonged by 10 h with the simple addition of clonidine (1 µg/kg per side); however, sedation occurred in almost one third of patients.¹⁰³ In the case of dexmedetomidine, studied doses include both weight-based regimens (*i.e.*, 0.5 to 1 µg/kg per side) and fixed dosing (*i.e.*, 100 µg per side). A 2018 meta-analysis reported significant reductions in pain scores at rest and on movement with the addition of dexmedetomidine for transversus abdominis plane blocks.¹⁰⁴ However, dexmedetomidine may result in increased sedation during the first postoperative hour as well as a lower heart rate during the first 4 h.¹⁰⁵ Future trials are required to investigate the optimal dose and route of administration (intravenous *vs.* perineural) of dexmedetomidine.

Since 2016, four randomized controlled trials have looked at the role of perineural magnesium for transversus abdominis plane blocks. Compared with control, doses between 0.15 and 0.5 g (per side) provide lower postoperative pain scores (for up to 12 h), longer analgesic duration, and lower morphine consumption.^{106–109} Future trials are required to investigate the optimal dose and mode of administration (intravenous *vs.* perineural) of magnesium for transversus abdominis plane blocks.

Finally, two randomized controlled trials conducted by Hutchins *et al.* have investigated the benefits of liposomal bupivacaine.^{110,111} Compared with bupivacaine with epinephrine, liposomal bupivacaine (130 mg) resulted in improved analgesia during the study period (72 h) as well as decreased opioid consumption and postoperative nausea or vomiting. To date, no trial has prospectively compared liposomal bupivacaine and continuous transversus abdominis plane blocks.

In summary, based on the current knowledge, we suggest the use of dilute concentrations of local anesthetic (*e.g.*, bupivacaine 0.2 to 0.25% or ropivacaine 0.2 to 0.25%) and injectate volumes of at least 15 ml (per side) for single-injection transversus abdominis plane blocks. For perineural transversus abdominis plane catheters, intermittent boluses (every 8 h) may provide more extensive blockade and higher cost efficiency than continuous local anesthetic infusion. Adjuvants such as dexamethasone, dexmedetomidine, and magnesium can increase the duration of transversus abdominis plane blocks. However, future investigation is required to elucidate their optimal dosing, mode of administration (intravenous *vs.* perineural), and combination. Furthermore, buprenorphine has been reported to prolong peripheral nerve blocks¹¹² and thus should also be investigated for transversus abdominis plane blocks in terms of efficacy as well as attendant emetic risk. Finally, patients undergoing transversus abdominis plane blocks remain at risk for local anesthetic systemic toxicity. In addition to careful local anesthetic dosing (based on lean weight), the operator should consider adding epinephrine to the local anesthetic mix, and providing patient monitoring for a period exceeding the time to maximum serum concentration (*e.g.*, 40 min).

Clinical Indications for Transversus Abdominis Plane Blocks

In the literature, transversus abdominis plane blocks have been used for a multitude of surgical interventions.³ The current review article focuses on the most common ones (*i.e.*, Cesarean delivery, laparoscopic cholecystectomy, hysterectomy, colorectal resection, appendectomy, inguinal hernia repair, prostatectomy, and bariatric surgery). To highlight the contemporary evidence, we base our suggestions on systematic reviews or meta-analysis published in 2018 or 2019. In the absence of such recent reviews, we derive our conclusions from the cumulative findings of randomized controlled trials. However, only trials published in PubMed-indexed journals were retained for analysis. This precautionary step was undertaken to minimize the impact of weaker studies published in lower tiered journals. Furthermore, particular attention (discussion) was paid to the control arm of randomized controlled trials, as the validation of transversus abdominis plane blocks (or any block) requires that control subjects receive optimal standard treatment (*e.g.*, thoracic epidural and multimodal analgesia for open and laparoscopic abdominal surgery, respectively). For the purposes of the current review, the term *multimodal analgesia* was defined

as the use of at least two nonopioid analgesic agents (*e.g.*, acetaminophen, nonsteroidal antiinflammatory drug, gabapentinoids, ketamine, local anesthetic wound infiltration)¹¹³ in addition to *pro re nata* oral or parenteral opioids.

Cesarean Delivery

Cesarean delivery constitutes the ideal surgical setting to investigate transversus abdominis plane blocks because the conventional Pfannenstiel incision lies in a territory readily anesthetized by the commonly performed lateral approach. Furthermore, because Cesarean section involves uterine incision but not excision, postoperative visceral trauma and pain may (arguably) be less pronounced. To date, Cesarean delivery constitutes the most studied surgery for transversus abdominis plane blocks.^{114–133} Unfortunately, the most recent systematic review article investigating the efficacy of transversus abdominis plane blocks for Cesarean section dates back to 2016¹³⁴ and thus did not include more recent trials.

Starting with the first trial investigating transversus abdominis plane blocks for Cesarean delivery (2008),¹¹⁴ multiple randomized controlled trials have concluded that the addition of posterior or lateral transversus abdominis plane blocks to a pharmacologic regimen encompassing acetaminophen, nonsteroidal antiinflammatory drugs and parenteral opioids results in significant analgesic and opioid-sparing benefits.^{115,118,120,121,130,132} However subsequent trials revealed that the efficacy of transversus abdominis plane blocks rivals at best that of wound infiltration^{126–128,131} and is inferior to that of intrathecal morphine (100 to 200 μ g).^{117,122} Because the latter is commonly used to provide analgesia for Cesarean delivery, the issue became whether the addition of transversus abdominis plane blocks to multimodal regimens that include long-acting neuraxial opioids would result in supplemental analgesic benefits. Six randomized controlled trials have investigated the question.^{116,119,123–125,129} Except for one study,¹²⁹ all trials (and the 2016 meta-analysis) concluded that posterior or lateral transversus abdominis plane blocks confer minimal advantages for Cesarean delivery in the setting of conventional doses of intrathecal morphine (*i.e.*, 100 to 250 μ g).^{116,119,123–125,134}

In summary, based on the current knowledge, we do not suggest the use of posterior or lateral transversus abdominis plane blocks for Cesarean delivery when long-acting intrathecal opioids are incorporated to the multimodal analgesic regimen. However, both approaches remain valuable analgesic options in patients who cannot receive intrathecal morphine or who undergo Cesarean section under general anesthesia.^{135,136}

Laparoscopic Cholecystectomy

Laparoscopic cholecystectomy constitutes the second most studied surgery for transversus abdominis plane blocks.^{15,29–31,50,88,137–144} The most recent meta-analysis investigating the efficacy of transversus abdominis plane blocks for laparoscopic cholecystectomy dates back to 2016.¹⁴⁵

Over the last 10 yr, multiple trials have investigated the benefits of lateral transversus abdominis plane blocks in the setting of laparoscopic cholecystectomy with mixed results. Whereas initial trials by El Dalawlatly *et al.*¹⁵ and Ra *et al.*⁸⁸ concluded that transversus abdominis plane blocks outperform intravenous morphine, a subsequent study detected no differences between the two analgesic strategies.¹⁴⁴ Furthermore, compared with local anesthetic infiltration of laparoscopic ports, lateral transversus abdominis plane blocks provide only marginal benefits in terms of postoperative pain scores¹⁴² and analgesic duration.¹³⁷ In fact, in the context of a multimodal analgesic regimen that included acetaminophen and ibuprofen (as well as patient-controlled intravenous opioids), Petersen *et al.*¹³⁸ demonstrated that the benefits of transversus abdominis plane blocks are confined to a small (8 mm on a 0 to 100 mm scale) reduction in pain while coughing and a 2.5-mg decrease in opioid requirement only during the first two postoperative hours.

The contemporary evidence suggests that the subcostal approach consistently outperforms its lateral counterpart in the setting of laparoscopic cholecystectomy.^{29–31} Therefore, from a methodologic standpoint, a critical analysis of potential benefits of transversus abdominis plane blocks for laparoscopic cholecystectomy should focus exclusively on the subcostal approach. In the literature, seven randomized controlled trials have compared subcostal transversus abdominis plane blocks with placebo (saline) or no treatment.^{29–31,50,139,141,143} Except for one study that only detected a shorter extubation time with transversus abdominis plane blocks,¹³⁹ the six other trials unequivocally suggest that subcostal transversus abdominis plane blocks outperform the standard analgesic treatment^{29–31,141,143} as well as periportal local anesthetic infiltration⁵⁰ with benefits extending up to 24 h postoperatively.^{29,141} However, these findings should be interpreted with caution because in none of the six trials did the control group employ a multimodal analgesic regimen that included acetaminophen, nonsteroidal antiinflammatory drugs, and periportal local anesthetic infiltration.¹⁴⁶ Thus, it remains unclear whether, similarly to Cesarean delivery, the benefits of (subcostal) transversus abdominis plane blocks could be negated by multimodal analgesia.

In summary, based on the current knowledge, we suggest further investigation to determine whether (subcostal) transversus abdominis plane blocks provide clinical benefits in the context of a multimodal analgesic regimen that incorporates acetaminophen, nonsteroidal antiinflammatory drugs, and periportal local anesthetic infiltration. We suggest the subcostal approach (instead of its lateral counterpart) if operators elect to perform transversus abdominis plane blocks for laparoscopic cholecystectomy.

Hysterectomy

Transversus abdominis plane blocks have been extensively studied in the context of open^{147–159} and laparoscopic hysterectomy.^{160–169} In 2018, a meta-analysis authored by Zhou

*et al.*¹⁷⁰ examined the benefits of transversus abdominis plane blocks for open and laparoscopic hysterectomy. Zhou *et al.*¹⁷⁰ concluded that, compared with placebo or no block, posterior/lateral transversus abdominis plane blocks result in reduced 24-hr morphine consumption, decreased pain scores at rest and on movement, lower incidences of nausea or vomiting, and increased analgesic duration after open hysterectomy. In contrast, transversus abdominis plane blocks seem to confer minimal benefits after laparoscopic hysterectomy.¹⁷⁰ The following year, Bacal *et al.*¹⁷¹ decided to carry out a similar meta-analysis. However they limited the scope of investigation to benign disease. Similarly to Zhou *et al.*,¹⁷⁰ Bacal *et al.*¹⁷¹ concluded that, compared with placebo or no block, posterior or lateral transversus abdominis plane blocks result in decreased early (2 h) and late (24 h) postoperative pain scores as well as a 10-mg lower morphine consumption at 24 h in patients undergoing open hysterectomy. Again, the benefits for laparoscopic hysterectomy seem marginal at best, as lateral transversus abdominis plane blocks can only decrease early postoperative pain.¹⁷¹

From a comparative standpoint, most published trials have used acetaminophen or nonsteroidal antiinflammatory drugs or periportal local anesthetic infiltration in the control group. However, none has employed a multimodal regimen that includes gabapentinoids,¹⁷² ketamine, and possibly intrathecal opioids.¹⁷³ Thus, future investigation is required to determine whether the benefits of transversus abdominis plane blocks (for open hysterectomy) would survive the implementation of such a multimodal analgesic regimen.

In summary, based on the current knowledge, we do not suggest the use of lateral transversus abdominis plane blocks for laparoscopic hysterectomy. Future trials are needed to determine the benefits of posterior transversus abdominis plane blocks for the latter. Although the current evidence supports the use of posterior and lateral transversus abdominis plane blocks for open hysterectomy, the authors suggest further investigation to determine whether these benefits would still be present in the context of a multimodal analgesic regimen that includes gabapentinoids, ketamine, or intrathecal opioids.

Colorectal Surgery

Transversus abdominis plane blocks have been extensively studied in the settings of open^{53,174,175} and laparoscopic colorectal surgery.^{176–182} Although a recent meta-analysis has summarized the benefits of transversus abdominis plane blocks for colorectal surgery,¹⁸³ the inclusion of both open and laparoscopic procedures constitutes a methodologic limitation, as the two types of interventions display inherently different patterns of postoperative pain and thus should be analyzed separately.

In 2018, Oh *et al.*¹⁸⁴ restricted the scope of their review article to laparoscopic colorectal surgery to investigate the potential benefits of transversus abdominis plane blocks. These authors reported that (lateral) transversus abdominis

plane blocks decrease early and late dynamic pain on movement after laparoscopic colorectal surgery compared with placebo or no treatment, despite similar pain at rest and breakthrough opioid consumption. Although statistically significant, these differences may not be clinically meaningful (0.2 to 0.7 on a 0 to 10 scale).¹⁸⁴ Furthermore, Oh *et al.*'s results should be interpreted with caution, as only two^{177,178} of the five trials^{176–178,180,181} included for analysis used multimodal analgesia.

For open colorectal surgery, multiple trials have previously demonstrated that, compared with placebo, transversus abdominis plane blocks result in decreased postoperative pain and morphine consumption.^{53,174} However, thoracic epidural analgesia is still considered by many to be the criterion analgesic standard for laparotomy: thus the more pertinent clinical question resides in the comparison of transversus abdominis plane and thoracic epidural blocks.^{185,186} Randomized trials investigating single-injection transversus abdominis plane blocks and continuous epidural catheters also highlight a second important methodologic issue pertaining to study design. For instance, for upper abdominal surgery (gastrectomy), Wu *et al.*¹⁸⁷ found that low thoracic epidural analgesia proved superior to bilateral subcostal transversus abdominis plane blocks in terms of breakthrough opioid consumption. However, the benefits associated with epidural analgesia seem to become less pronounced in recent years, as authors started using longer acting (liposomal) formulations of bupivacaine.^{188–190} Furthermore, preliminary evidence seems to indicate that continuous (subcostal) transversus abdominis plane blocks outperform their single-injection counterparts.¹⁹¹ These cumulative findings suggest that block duration constitutes an important confounding variable. Therefore, to properly investigate the benefits of transversus abdominis plane blocks for open colorectal surgery, one must compare continuous thoracic epidural blocks with continuous transversus abdominis plane blocks.

To date, three randomized controlled trials have tackled the issue with mixed findings.^{192–194} Niraj *et al.*¹⁹² and Ganapathy *et al.*¹⁹⁴ concluded that, compared with their thoracic epidural counterparts, subcostal transversus abdominis plane catheters (with or without concomitant lateral transversus abdominis plane catheters) result in similar analgesia but an increased need for breakthrough analgesics. In contrast, Wahba *et al.*¹⁹³ reported that, in patients with ischemic heart disease, thoracic epidural blocks resulted in decreased pain scores, 100-min longer analgesic duration, and 10.5-mg lower intravenous morphine consumption during the first 48 h as well as decreased sedation (during the first 24 h) and improved patient satisfaction (2 points on a 0 to 10 scale). Nonetheless, despite their findings favoring the use of thoracic epidural analgesia, Wahba *et al.*¹⁹³ opined that transversus abdominis plane blocks remain a valid analgesic option if thoracic epidural analgesia is contraindicated.

Based on the current understanding, we suggest the use of thoracic epidural analgesia for open colorectal surgery. However, subcostal transversus abdominis plane blocks remain a valid alternative for patients undergoing laparotomy in whom neuraxial blocks are contraindicated. We suggest further investigation to determine whether the benefits of (lateral) transversus abdominis plane blocks for laparoscopic colorectal surgery would persist in the setting of multimodal analgesia.

Appendectomy

To date, three randomized trials have investigated the benefits of transversus abdominis plane blocks for open appendectomy^{195–197} and three studies have done the same for laparoscopic appendectomy.^{198–200} Overall the findings have been fairly consistent. For open appendectomy, both lateral and posterior transversus abdominis plane blocks have been shown to result in decreased postoperative pain scores at rest and on movement as well as significant reductions in consumption of intravenous morphine (22 mg) and tramadol (78 mg) at 24 h and intravenous morphine (12.3 mg) at 48 h^{195–197} despite the use of acetaminophen and diclofenac.^{195,196} In contrast, for laparoscopic appendectomy, two trials have concluded that lateral transversus abdominis plane blocks provide no benefit in the setting of multimodal analgesia.^{198,200} However, Tanngaard *et al.*¹⁹⁹ were able to obtain a cumulative decrease in static and dynamic pain during the first 12 h by supplementing lateral transversus abdominis plane blocks with subcostal transversus abdominis plane blocks. Because the lateral approach provides minimal benefits for laparoscopic appendectomy,^{198,200} Tanngaard *et al.*'s encouraging results could perhaps be attributed to subcostal transversus abdominis plane blocks. Therefore, future trials should assess isolated subcostal as well as posterior transversus abdominis plane blocks in the setting of laparoscopic appendectomy.

Based on the current knowledge, we suggest the use of posterior or lateral transversus abdominis plane blocks for open appendectomy. The current evidence does not support the role of lateral transversus abdominis plane blocks for laparoscopic appendectomy. Further investigation is required to elucidate the potential benefits of subcostal or posterior transversus abdominis plane blocks for laparoscopic appendectomy.

Inguinal Hernia Repair

Transversus abdominis plane blocks have been extensively studied in the context of open^{201–206} and laparoscopic inguinal hernia repair.^{207–209} The most recent meta-analysis investigating the benefits of transversus abdominis plane blocks for hernia repair dates back to 2017.²¹⁰

For open inguinal repair, lateral or posterior transversus abdominis plane blocks result in lower pain scores and opioid consumption compared with no block^{203,206} or wound

infiltration.^{201,205} In fact, Petersen *et al.*²⁰² have shown that lateral transversus abdominis plane blocks provide similar efficacy to ilioinguinal blocks combined with wound infiltration. For laparoscopic inguinal hernia repair, two trials have also found decreased pain and opioid requirement with lateral transversus abdominis plane blocks compared with no block²⁰⁷ and portal local anesthetic infiltration.²⁰⁸ However, for bilateral laparoscopic inguinal hernia repair, preperitoneal instillation of local anesthetic outperforms transversus abdominis plane blocks.²⁰⁹ To date, of all published trials for open and laparoscopic inguinal hernia repair, only one²⁰⁸ has employed the recommended multimodal regimen, which includes acetaminophen, nonsteroidal antiinflammatory drugs, as well as local anesthetic infiltration.²¹¹ Thus, further investigation is required to determine whether the benefits of transversus abdominis plane blocks would persist despite the implementation of such multimodal analgesia.

In summary, based on the current knowledge, we suggest further investigation to determine whether the benefits of posterior and lateral transversus abdominis plane blocks for open and laparoscopic inguinal hernia repair would persist in the context of a multimodal analgesic regimen that includes acetaminophen, nonsteroidal antiinflammatory drugs, and local anesthetic infiltration.

Prostatectomy

To date, three studies have investigated the efficacy of transversus abdominis plane blocks for open prostatectomy.^{212–214} Two of the three trials could not detect significant benefit associated with lateral transversus abdominis plane blocks. Thus, we do not suggest their use for open prostatectomy. However future studies are required to investigate posterior transversus abdominis plane blocks for the latter as well as the potential benefits of transversus abdominis plane blocks for laparoscopic prostatectomy.

Bariatric Surgery

To date, three studies have investigated the efficacy of transversus abdominis plane blocks for (laparoscopic) bariatric surgery.^{55,215,216} Two studies reported that transversus abdominis plane blocks result in lower postoperative pain scores and analgesic consumption as well as quicker ambulation and oral intake.^{55,215} Although statistically significant, the differences in pain scores (less than 2 on a 0 to 10 scale), intravenous morphine consumption at 24 h (3.1 mg), ambulation (less than or equal to 1.7 h), and oral intake (2.4 h) may not be clinically relevant.^{55,215} Interestingly, in the only trial that used a multimodal analgesic regimen (*i.e.*, acetaminophen, ketorolac at the end of surgery, and periportal local anesthetic infiltration), Albrecht *et al.*²¹⁶ reported no clinical benefits associated with (subcostal) transversus abdominis plane blocks. Thus, further confirmatory investigation is required to elucidate the benefits of transversus abdominis plane blocks in the setting of multimodal analgesia.

Complications of Transversus Abdominis Plane Blocks

Complications related to transversus abdominis plane blocks can be attributed to the needle or the local anesthetic agent.

In terms of needle-related adverse events, the abdominal wall is sufficiently vascularized to sustain needle trauma, as evidenced by the recent report of a (self-resolving) abdominal wall hematoma in an obstetrical patient with HELLP syndrome.²¹⁷ Furthermore, during the performance of transversus abdominis plane blocks, the needle tip can inadvertently traverse the transversus abdominis muscle (and peritoneum) thereby resulting in peritoneal breach and visceral injury.^{43,218–220} Interestingly, if the needle tip is positioned just between the transversus abdominis muscle and the transversalis fascia (without puncturing the peritoneum), local anesthetic injection could result in transient femoral nerve blockade because the fascia iliaca constitutes the posterolateral continuation of the transversalis fascia.^{221–223} The preceding complications underscore the importance of visualizing the entire length of the needle during the performance of ultrasound-guided transversus abdominis plane blocks.²²⁴

Because transversus abdominis plane blocks require relatively large injectates and are often carried out bilaterally, local anesthetic systemic toxicity remains a concern especially in elderly patients or those with decreased muscle mass. There exist multiple reports of local anesthetic systemic toxicity after the administration of (levo) bupivacaine (2.7 to 2.9 mg/kg)^{225,226} as well as ropivacaine (4.9 to 7.9 mg/kg)^{226,227} for transversus abdominis plane blocks. In none of these cases did the operators use adjunctive epinephrine to curtail local anesthetic plasmatic absorption.²²⁸ Furthermore, in one report,²²⁵ the 2.9-mg/kg dose of bupivacaine was administered to a patient experiencing acute fatty liver of pregnancy, a condition known to increase the free fraction of plasma bupivacaine (attributable to a decreased production of local anesthetic-binding serum proteins).²²⁵ The prohibitively supratoxic dose (7.9 mg/kg) of ropivacaine reported by Sherrer *et al.*²²⁷ stemmed from a lack of communication between surgeon and anesthesiologist, as the former carried out intraperitoneal local anesthetic infiltration (using 20 ml of ropivacaine 0.75%) before the latter's performance of transversus abdominis plane blocks (using 40 ml of ropivacaine 0.75%). Finally, local anesthetic injection in the transversus abdominis plane compartment may result in motor block of the thoracolumbar nerves. In turn, this could result in paresis of the abdominal muscles as evidenced by a bulge in the abdominal wall when the patient coughs or bears down.^{229,230} In both reported cases, the bulge subsided uneventfully as the transversus abdominis plane block wore off.^{229,230}

In summary, based on the current knowledge, care must be taken to visualize the entire length of the needle during the performance of transversus abdominis plane blocks to prevent breaching the transversus abdominis muscle and the

peritoneum thereby minimizing the risk of femoral blockade and visceral injury. Furthermore, a thorough analysis of risks and benefits must be undertaken before the performance of transversus abdominis plane blocks in coagulopathic patients. Finally, in addition to respecting ceiling doses of local anesthetic, the prudent anesthesiologist should consider using dilute local anesthetic concentrations as well as adjunctive epinephrine to delay local anesthetic plasmatic absorption, especially in subsets of patients at risk for local anesthetic systemic toxicity. Moreover, communication between surgeon and anesthesiologist is paramount to avoid supratoxic cumulative doses resulting from concomitant local anesthetic infiltration and transversus abdominis plane blocks.

Alternative Truncal Blocks

From an anatomical standpoint, abdominal truncal blocks can be performed anywhere from neuraxial (*i.e.*, caudal block) and paraneuraxial (*e.g.*, thoracic paravertebral block, erector spinae plane block, retrolaminar, transmuscular quadratus lumborum blocks) locations to terminal compartments (*e.g.*, rectus sheath block) or terminal neural targets (*i.e.*, ilioinguinal and iliohypogastric nerve). To date, transversus abdominis plane blocks have been compared with a plethora of alternatives such as caudal blocks,^{231–233} thoracic paravertebral blocks,²³⁴ quadratus lumborum blocks,^{235–238} rectus sheath blocks,^{63,64,159,239} and ilioinguinal and iliohypogastric nerve blocks.^{233,240–244} To highlight the best evidence, only randomized controlled trials published in PubMed-indexed journals were retained for analysis.

Transversus Abdominis Plane Block versus Caudal Block (in Pediatric Patients)

Three randomized trials have compared ultrasound-guided (lateral or posterior) transversus abdominis plane blocks and (landmark- or ultrasound-guided) caudal blocks in children undergoing lower abdominal surgery (*i.e.*, ureteroneocystostomy, herniorrhaphy, orchidopexy, hydrocelectomy, testicular detorsion).^{231–233} In two trials, transversus abdominis plane blocks resulted in significant advantages compared with caudal blocks, as patients required less breakthrough intravenous morphine (0.05 mg/kg *vs.* 0.09 mg/kg) at 24 h.²³¹ Furthermore, fewer children reported pain during the 6-h to 24-h postoperative interval (44% *vs.* 75%).²³² However, one trial failed to detect significant differences between transversus abdominis plane and caudal blocks in terms of pain and analgesic consumption.²³³

Transversus Abdominis Plane Block versus Thoracic Paravertebral Block

To date, only one trial has compared lateral transversus abdominis plane and thoracic paravertebral blocks. In 2012, Melnikov *et al.*²³⁴ compared bilateral ultrasound-guided lateral transversus abdominis plane blocks with bilateral T10 thoracic paravertebral blocks in patients undergoing vertical

laparotomy for total hysterectomy with salpingo-oophorectomy. Although the transversus abdominis plane group displayed a significant higher cumulative opioid (ketomebion) consumption at 24 and 48 h, there were no intergroup differences in terms of pain scores and patient satisfaction.²³⁴

Transversus Abdominis Plane Block versus Quadratus Lumborum Block

Four randomized trials have compared ultrasound-guided lateral transversus abdominis plane blocks and quadratus lumborum blocks (with local anesthetic injection on the anterolateral aspect of the quadratus lumborum muscle) with similar results.^{235–238} In the setting of Cesarean section, open hysterectomy, inguinal hernia, orchiopexy, and lower abdominal surgery, quadratus lumborum blocks result in 2.5- to 7.5-mg decreases in morphine consumption at 24 h compared with their transversus abdominis plane counterparts.^{235,237,238} Furthermore, three of the four trials also found lower pain scores^{236–238} and two studies reported 80% longer analgesic duration with quadratus lumborum blocks.^{237,238}

Transversus Abdominis Plane Block versus Rectus Sheath Block

To date, two small pharmacologic trials (combined n = 72) have compared lateral ultrasound-guided transversus abdominis plane blocks and rectus sheath blocks in patients undergoing laparoscopic gynecologic surgery.^{63,64} Both studies reported that transversus abdominis plane blocks displayed a 34% to 47% earlier peak of local anesthetic plasma levels. Whereas one trial found no differences in postoperative analgesia,⁶⁴ the other one observed longer postoperative analgesia in the transversus abdominis plane group.⁶³ In a recent trial, Abo-Zeid *et al.*²³⁹ also reported longer analgesic duration (and lower breakthrough opioid consumption) after abdominoplasty with lateral transversus abdominis plane blocks compared with rectus sheath blocks. In 2017, Cowlshaw *et al.*¹⁵⁹ compared continuous subcostal transversus abdominis plane blocks (inserted with ultrasound guidance by anesthesiologists) and rectus sheath blocks (inserted under direct vision by surgeons) in patients undergoing midline laparotomy for gynecologic oncologic surgery. These authors found no intergroup differences in terms of postoperative pain and breakthrough opioid consumption.¹⁵⁹

The analgesic difference between transversus abdominis plane and rectus sheath blocks could be partly ascribed to the site of surgical incision. Because rectus sheath blocks anesthetize somatic structures confined to the territory of the rectus abdominis muscle, their clinical usefulness may be highest in the setting of midline laparotomy (as evidenced by Cowlshaw *et al.*'s results¹⁵⁹). In contrast, when the surgical incision exceeds the confines of the rectus abdominis muscle (*e.g.*, laparoscopic gynecologic surgery⁶³ or abdominoplasty,²³⁹) transversus abdominis plane blocks may offer improved versatility.

Transversus Abdominis Plane Blocks *versus* Ilioinguinal and Iliohypogastric Nerve Block

To date, five trials have compared lateral transversus abdominis plane blocks and ilioinguinal and iliohypogastric nerve blocks in the setting of inguinal hernia repair with mixed results.^{233,240–242,244} In two randomized controlled trials, transversus abdominis plane blocks provided better postoperative analgesia than ilioinguinal and iliohypogastric nerve blocks.^{233,241} However, the results of these two studies should be interpreted with caution, as one trial carried out ilioinguinal and iliohypogastric blocks with a blind technique,²⁴⁰ whereas the other attributed its findings to the operators' lack of experience with ilioinguinal and iliohypogastric nerve blocks.²³³ In fact, studies by Fredrickson *et al.*²⁴⁰ and Kamal *et al.*²⁴⁴ concluded that, when performed with ultrasound guidance, ilioinguinal and iliohypogastric nerve blocks result in superior postoperative analgesia²⁴⁰ as well as 28% longer analgesic duration²⁴⁴ and lower breakthrough analgesic consumption^{240,244} than lateral transversus abdominis plane blocks. To complicate matters further, Okur *et al.*²⁴² recently found minimal differences between the two blocks.

In 2017, one trial compared bilateral lateral transversus abdominis plane blocks with bilateral ilioinguinal and iliohypogastric nerve blocks for patients undergoing Cesarean delivery.²⁴³ Although postoperative pain scores were similar in both groups, patients allocated to transversus abdominis plane blocks required 1,000mg less breakthrough tramadol during the first 24h.

In summary, based on the current knowledge, we suggest the use of lateral quadratus lumborum blocks over lateral transversus abdominis plane blocks for lower abdominal surgery (*e.g.*, Cesarean delivery, hysterectomy, inguinal herniorrhaphy and orchiopexy surgery). In light of contradictory or preliminary findings, further trials are required to compare lateral and posterior transversus abdominis plane blocks with caudal blocks, thoracic paravertebral blocks, rectus sheath blocks, and ilioinguinal and iliohypogastric nerve blocks.

Current Knowledge and Future Research

In summary, over the last 18 yr, transversus abdominis plane blocks have been the topic of considerable research. At times,

the collective results of published trials can be difficult to interpret in light of two important confounding variables. First, the term *transversus abdominis plane block* encompasses various approaches that result in radically different somatic and visceral coverage. For instance, whereas the lateral approach can be used for infraumbilical surgery, its subcostal counterpart should be preferred for procedures involving the upper abdomen. Furthermore, of the three described approaches, only the posterior one can achieve local anesthetic spread to the paravertebral spaces, thereby providing sympathetic blockade and visceral analgesia. Therefore any positive (analgesic) outcome related to transversus abdominis plane block should be viewed as approach-specific. Conversely, even if a given approach fails to provide benefits for a surgical intervention, it should not deter operators (and researchers) from exploring an alternative approach. Second, the findings of any comparative trial axiomatically depend on the control group. Because multimodal analgesia has become normative in clinical practice, trials involving transversus abdominis plane blocks that omitted its use in their control group leave many questions unanswered. One need only think of the fact that the initial benefits reported with transversus abdominis plane blocks after Cesarean delivery quickly dissipated when intrathecal morphine was incorporated to the standard analgesic regimen. Unfortunately, to date, many published trials have either compared transversus abdominis plane blocks with no treatment or failed to provide adequate multimodal analgesia to their control groups.

Despite the contradictory findings, scarcity of evidence, and shortcomings afflicting some randomized controlled trials, certain clinical suggestions can nonetheless be made (table 1). Overall, transversus abdominis plane blocks appear most beneficial in the setting of open appendectomy (posterior or lateral approach). Lateral transversus abdominis plane blocks are not suggested for laparoscopic hysterectomy, laparoscopic appendectomy, and open prostatectomy. However, transversus abdominis plane blocks could serve as an analgesic option for Cesarean delivery (posterior or lateral approach) and open colorectal section (subcostal or lateral approach) if there exist contraindications to intrathecal morphine and thoracic epidural analgesia, respectively.

Table 1. Authors' Suggestions Pertaining to Clinical Indications and Alternatives for TAP Blocks

Clinical indications	<ul style="list-style-type: none"> • Cesarean delivery: posterior and lateral TAP block not recommended if long-acting intrathecal opioids are used (1) • Laparoscopic cholecystectomy: subcostal approach recommended over lateral approach if the operator elects to perform a TAP block (2) • Laparoscopic hysterectomy: lateral TAP block not recommended (1) • Open colorectal surgery: thoracic epidural block recommended (lateral or subcostal continuous TAP blocks recommended if contraindication to neuraxial block) (2) • Open appendectomy: posterior or lateral TAP block recommended (2) • Laparoscopic appendectomy: lateral TAP block not recommended (2) • Open prostatectomy: lateral TAP block not recommended (2)
Alternative truncal blocks	<ul style="list-style-type: none"> • Quadratus lumborum block (lateral or Type 1): recommended over lateral TAP block (2)

Levels of evidence are indicated in parentheses. Based on the Oxford Levels of Evidence (Level 1 = systematic review of randomized trials or n-of 1 trials; Level 2 = randomized trial or observational study with dramatic effect; Level 3 = nonrandomized controlled cohort or follow-up study; Level 4 = case-series or case-control studies, or historically controlled studies; Level 5 = mechanism-based reasoning). TAP, transversus abdominis plane.

Table 2. Clinical Areas Pertaining to TAP Blocks Warranting Further Investigation

- Comparison between subcostal and posterior TAP block
- Comparison between posterior TAP block and lateral (type 1) quadratus lumborum block
- Optimal technique for surgical TAP block
- Optimal single dose and mode of administration for either dexamethasone, dexmedetomidine, magnesium, or buprenorphine for TAP block
- Optimal combination of multimodal regional analgesia (dexamethasone ± dexmedetomidine ± magnesium ± buprenorphine) for TAP block
- Comparison between continuous TAP block and single-injection TAP block using liposomal bupivacaine
- Benefits of TAP blocks in the setting of multimodal analgesia for laparoscopic cholecystectomy (subcostal approach), hysterectomy (posterior/lateral approach), laparoscopic colorectal surgery (lateral approach), open/laparoscopic inguinal hernia repair (posterior/lateral approach), laparoscopic prostatectomy (posterior/lateral approach)
- Posterior TAP block for laparoscopic hysterectomy, laparoscopic appendectomy, and open prostatectomy
- Posterior or lateral TAP block for laparoscopic prostatectomy
- Comparison between posterior TAP block and thoracic epidural block for open colorectal surgery with emphasis on respiratory and gastrointestinal (*i.e.*, return of bowel function) outcomes
- Further comparison between (posterior/lateral) TAP block and caudal, thoracic paravertebral, rectus sheath, and ilioinguinal/iliohypogastric block
- Comparison between (posterior) TAP block and newer truncal block (*e.g.*, anterior quadratus lumborum block, retrolaminar block, erector spinae plane block)

TAP, transversus abdominis plane.

Currently, knowledge gaps remain that require further investigation (table 2). For instance, posterior and subcostal transversus abdominis plane blocks should be compared in clinical settings (upper abdominal surgery); differences between posterior transversus abdominis plane blocks and lateral (*i.e.*, type 1) quadratus lumborum blocks should be elucidated; the optimal dose, mode of administration, and combination of adjuvants to prolong transversus abdominis plane blocks requires future investigation. Furthermore, posterior transversus abdominis plane blocks should be investigated for surgical interventions in which their lateral counterparts have proven not to be beneficial (*i.e.*, laparoscopic hysterectomy, laparoscopic appendectomy, open prostatectomy). For such trials, it will be paramount that the control group receive adequate multimodal analgesia. More importantly, because posterior transversus abdominis plane blocks can purportedly provide sympathetic blockade and visceral analgesia, they should be compared with thoracic epidural analgesia for open colorectal surgery with emphasis on respiratory and gastrointestinal (*i.e.*, return of bowel function) outcomes as well as adverse events such as hypotension. Moreover, in the context of an ever-expanding array of ultrasound-guided truncal blocks,² the benefits (if any) of transversus abdominis plane blocks over newer and more proximal interfascial plane blocks (*i.e.*, retrolaminar, erector spinae plane, and anterior quadratus lumborum blocks) need to be investigated with well-designed and adequately powered trials.²⁴⁵ Finally, in addition to postoperative pain scores and breakthrough opioid consumption, future randomized controlled trials should consider including cost analyses as well as hard outcomes such as length of stay.

Research Support

Support for this study was provided solely from institutional and/or departmental sources.

Competing Interests

The authors declare no competing interests.

Correspondence

Address correspondence to Dr. Tran: St. Mary's Hospital, Department of Anesthesiology, 3830 Ave Lacombe, Montreal, Quebec, Canada H3T-1M5. de_tran@hotmail.com. Information on purchasing reprints may be found at www.anesthesiology.org or on the masthead page at the beginning of this issue. ANESTHESIOLOGY's articles are made freely accessible to all readers, for personal use only, 6 months from the cover date of the issue.

References

1. Rafi AN: Abdominal field block: A new approach via the lumbar triangle. *Anaesthesia* 2001; 56:1024–6
2. Chin KJ, McDonnell JG, Carvalho B, Sharkey A, Pawa A, Gadsden J: Essentials of our current understanding: Abdominal wall blocks. *Reg Anesth Pain Med* 2017; 42:133–83
3. Tsai HC, Yoshida T, Chuang TY, Yang SF, Chang CC, Yao HY, Tai YT, Lin JA, Chen KY: Transversus abdominis plane block: An updated review of anatomy and techniques. *Biomed Res Int* 2017; 2017:8284363
4. Rozen WM, Tran TM, Ashton MW, Barrington MJ, Ivanusic JJ, Taylor GI: Refining the course of the thoracolumbar nerves: A new understanding of the innervation of the anterior abdominal wall. *Clin Anat* 2008; 21:325–33
5. Hebbard PD, Barrington MJ, Vasey C: Ultrasound-guided continuous oblique subcostal transversus abdominis plane blockade: Description of anatomy and clinical technique. *Reg Anesth Pain Med* 2010; 35:436–41
6. Netter FH: *Abdomen, Atlas of human anatomy*, 7th edition. Edited by Netter FH. Philadelphia, Elsevier, c2019, pp275–366.e30.
7. Jankovic ZB, du Feu FM, McConnell P: An anatomical study of the transversus abdominis plane block: Location of the lumbar triangle of Petit and adjacent nerves. *Anesth Analg* 2009; 109:981–5

8. McDonnell JG, O'Donnell BD, Farrell T, Gough N, Tuite D, Power C, Laffey JG: Transversus abdominis plane block: A cadaveric and radiological evaluation. *Reg Anesth Pain Med* 2007; 32:399–404
9. Drake RL, Vogl WV, Mitchell AWM: Abdomen, Gray's atlas of anatomy, 2nd edition. Edited by Drake RL. Philadelphia, Churchill Livingstone, c2015, pp133–209.
10. Mokini Z, Vitale G: Yet more on TAP block nomenclature. *Anaesthesia* 2015; 70:369–70
11. Hebbard P: TAP block nomenclature. *Anaesthesia* 2015; 70:112–3
12. Hebbard P: Subcostal transversus abdominis plane block under ultrasound guidance. *Anesth Analg* 2008; 106:674–5; author reply 675
13. Hebbard PD: Cutaneous distribution of lateral transversus abdominis plane block. *Reg Anesth Pain Med* 2017; 42:267–8
14. Hebbard P, Fujiwara Y, Shibata Y, Royse C: Ultrasound-guided transversus abdominis plane (TAP) block. *Anaesth Intensive Care* 2007; 35:616–7
15. El-Dawlatly AA, Turkistani A, Kettner SC, Machata AM, Delvi MB, Thallaj A, Kapral S, Marhofer P: Ultrasound-guided transversus abdominis plane block: Description of a new technique and comparison with conventional systemic analgesia during laparoscopic cholecystectomy. *Br J Anaesth* 2009; 102:763–7
16. Carney J, Finnerty O, Rauf J, Bergin D, Laffey JG, Mc Donnell JG: Studies on the spread of local anaesthetic solution in transversus abdominis plane blocks. *Anaesthesia* 2011; 66:1023–30
17. O'Donnell BD, McDonnell JG, McShane AJ: The transversus abdominis plane (TAP) block in open retroperitoneal prostatectomy. *Reg Anesth Pain Med* 2006; 31:91
18. McDonnell JG, Laffey JG: In response. *Anesth Analg* 2007; 105:282–3
19. Vial F, Mory S, Guerci P, Grandjean B, Petry L, Perrein A, Bouaziz H: Evaluating the learning curve for the transversus abdominal plane block: A prospective observational study [in French]. *Can J Anaesth* 2015; 62:627–33
20. Shibata Y, Sato Y, Fujiwara Y, Komatsu T: Transversus abdominis plane block. *Anesth Analg* 2007; 105:883; author reply 883
21. Tran TM, Ivanusic JJ, Hebbard P, Barrington MJ: Determination of spread of injectate after ultrasound-guided transversus abdominis plane block: A cadaveric study. *Br J Anaesth* 2009; 102:123–7
22. Lee THW, Barrington MJ, Tran TMN, Wong D, Hebbard PD: Comparison of sensory blockade following posterior and subcostal approaches to ultrasound-guided transversus abdominis plane block. *Anaesth Intens Care* 2010; 38:452–60
23. Blanco R: TAP block under ultrasound guidance: The description of a no pops technique: 271[abstract]. *Reg Anesth Pain Med* 2007; 32:S130
24. Nee RM, McDonnell J: A call for scrutiny of the transversus abdominis plane block label. *Reg Anesth Pain Med* 2018; 43:563
25. Carline L, McLeod GA, Lamb C: A cadaver study comparing spread of dye and nerve involvement after three different quadratus lumborum blocks. *Br J Anaesth* 2016; 117:387–94
26. Tamura T, Yokota S, Ito S, Shibata Y, Nishiwaki K: Local anesthetic spread into the paravertebral space with two types of quadratus lumborum blocks: A crossover volunteer study. *J Anesth* 2019; 33:26–32
27. Milan Z, Tabor D, McConnell P, Pickering J, Kocarev M, du Feu F, Barton S: Three different approaches to Transversus abdominis plane block: A cadaveric study. *Med Glas (Zenica)* 2011; 8:181–4
28. Abdallah FW, Laffey JG, Halpern SH, Brull R: Duration of analgesic effectiveness after the posterior and lateral transversus abdominis plane block techniques for transverse lower abdominal incisions: A meta-analysis. *Br J Anaesth* 2013; 111:721–35
29. Bhatia N, Arora S, Jyotsna W, Kaur G: Comparison of posterior and subcostal approaches to ultrasound-guided transversus abdominis plane block for postoperative analgesia in laparoscopic cholecystectomy. *J Clin Anesth* 2014; 26:294–9
30. Shin HJ, Oh AY, Baik JS, Kim JH, Han SH, Hwang JW: Ultrasound-guided oblique subcostal transversus abdominis plane block for analgesia after laparoscopic cholecystectomy: A randomized, controlled, observer-blinded study. *Minerva Anestesiologica* 2014; 80:185–93
31. Oksar M, Koyuncu O, Turhanoglu S, Temiz M, Oran MC: Transversus abdominis plane block as a component of multimodal analgesia for laparoscopic cholecystectomy. *J Clin Anesth* 2016; 34:72–8
32. Khan KK, Khan RI: Analgesic effect of bilateral subcostal tap block after laparoscopic cholecystectomy. *J Ayub Med Coll Abbottabad* 2018; 30:12–5
33. Faiz SHR, Alebouyeh MR, Derakhshan P, Imani F, Rahimzadeh P, Ghaderi Ashtiani M: Comparison of ultrasound-guided posterior transversus abdominis plane block and lateral transversus abdominis plane block for postoperative pain management in patients undergoing cesarean section: A randomized double-blind clinical trial study. *J Pain Res* 2018; 11:5–9
34. Furuya T, Kato J, Yamamoto Y, Hirose N, Suzuki T: Comparison of dermatomal sensory block following ultrasound-guided transversus abdominis plane block by the lateral and posterior approaches: A randomized controlled trial. *J Anaesthesiol Clin Pharmacol* 2018; 34:205–10
35. Børglum J, Maschmann C, Bellhage B, Jensen K: Ultrasound-guided bilateral dual transversus abdominis plane block: A new four-point approach. *Acta Anaesthesiol Scand* 2011; 55:658–63

36. Borglum J, Jensen K, Christensen AF, Hoegberg LC, Johansen SS, Lönnqvist PA, Jansen T: Distribution patterns, dermatomal anesthesia, and ropivacaine serum concentrations after bilateral dual transversus abdominis plane block. *Reg Anesth Pain Med* 2012; 37:294–301
37. Niraj G, Kelkar A, Hart E, Horst C, Malik D, Yeow C, Singh B, Chaudhri S: Comparison of analgesic efficacy of four-quadrant transversus abdominis plane (TAP) block and continuous posterior TAP analgesia with epidural analgesia in patients undergoing laparoscopic colorectal surgery: An open-label, randomised, non-inferiority trial. *Anaesthesia* 2014; 69:348–55
38. Rafi AN: Abdominal field block via the lumbar triangle revisited. *Anaesthesia* 2012; 67:1399–401
39. Reid SA: The transversus abdominis plane block. *Anesth Analg* 2007; 105:282; author reply 282–3
40. Nteli Chatzioglou G, Bagheri H, Pinar Y, Govsa F: Anatomical topography of the inferior lumbar triangle for transversus abdominis block. *Surg Radiol Anat* 2018; 40:99–107
41. Loukas M, Tubbs RS, El-Sedfy A, Jester A, Polepalli S, Kinsela C, Wu S: The clinical anatomy of the triangle of Petit. *Hernia* 2007; 11:441–4
42. McDermott G, Korba E, Mata U, Jaigirdar M, Narayanan N, Boylan J, Conlon N: Should we stop doing blind transversus abdominis plane blocks? *Br J Anaesth* 2012; 108:499–502
43. Farooq M, Carey M: A case of liver trauma with a blunt regional anesthesia needle while performing transversus abdominis plane block. *Reg Anesth Pain Med* 2008; 33:274–5
44. Walter EJ, Smith P, Albertyn R, Uncles DR: Ultrasound imaging for transversus abdominis blocks. *Anaesthesia* 2008; 63:211
45. Neal JM, Brull R, Horn JL, Liu SS, McCartney CJ, Perlas A, Salinas FV, Tsui BC: The second American Society of Regional Anesthesia and Pain Medicine evidence-based medicine assessment of ultrasound-guided regional anesthesia: Executive summary. *Reg Anesth Pain Med* 2016; 41:181–94
46. Moeschler SM, Murthy NS, Hoelzer BC, Gazelka HM, Rho RH, Pingree MJ: Ultrasound-guided transversus abdominis plane injection with computed tomography correlation: A cadaveric study. *J Pain Res* 2013; 6:493–6
47. Barrington MJ, Ivanusic JJ, Rozen WM, Hebbard P: Spread of injectate after ultrasound-guided subcostal transversus abdominis plane block: A cadaveric study. *Anaesthesia* 2009; 64:745–50
48. West C, Milner CS: A simple modification to the transversus abdominis plane block provides safe and effective analgesia in TRAM/DIEP flap patients. *Plast Reconstr Surg* 2010; 126:146e–7e
49. Araco A, Pooney J, Araco F, Gravante G: Transversus abdominis plane block reduces the analgesic requirements after abdominoplasty with flank liposuction. *Ann Plast Surg* 2010; 65:385–8
50. Elamin G, Waters PS, Hamid H, O’Keeffe HM, Waldron RM, Duggan M, Khan W, Barry MK, Khan IZ: Efficacy of a laparoscopically delivered transversus abdominis plane block technique during elective laparoscopic cholecystectomy: A prospective, double-blind randomized trial. *J Am Coll Surg* 2015; 221:335–44
51. Chetwood A, Agrawal S, Hrouda D, Doyle P: Laparoscopic assisted transversus abdominis plane block: A novel insertion technique during laparoscopic nephrectomy. *Anaesthesia* 2011; 66:317–8
52. Owen DJ, Harrod I, Ford J, Luckas M, Gudimetla V: The surgical transversus abdominis plane block—a novel approach for performing an established technique. *BJOG* 2011; 118:24–7
53. Bharti N, Kumar P, Bala I, Gupta V: The efficacy of a novel approach to transversus abdominis plane block for postoperative analgesia after colorectal surgery. *Anesth Analg* 2011; 112:1504–8
54. Wheble GA, Tan EK, Turner M, Durrant CA, Heppell S: Surgeon-administered, intra-operative transversus abdominis plane block in autologous breast reconstruction: A UK hospital experience. *J Plast Reconstr Aesthet Surg* 2013; 66:1665–70
55. Said AM, Balamoun HA: Continuous transversus abdominis plane blocks via laparoscopically placed catheters for bariatric surgery. *Obes Surg* 2017; 27:2575–82
56. Ravichandran NT, Sistla SC, Kundra P, Ali SM, Dhanapal B, Galidevara I: Laparoscopic-assisted transversus abdominis plane (TAP) block versus ultrasonography-guided transversus abdominis plane block in postlaparoscopic cholecystectomy pain relief: Randomized controlled trial. *Surg Laparosc Endosc Percutan Tech* 2017; 27:228–32
57. Park SY, Park JS, Choi GS, Kim HJ, Moon S, Yeo J: Comparison of analgesic efficacy of laparoscope-assisted and ultrasound-guided transversus abdominis plane block after laparoscopic colorectal operation: A randomized, single-blind, non-inferiority trial. *J Am Coll Surg* 2017; 225:403–10
58. Narasimhulu DM, Scharfman L, Minkoff H, George B, Homel P, Tyagaraj K: A randomized trial comparing surgeon-administered intraoperative transversus abdominis plane block with anesthesiologist-administered transcatheter block. *Int J Obstet Anesth* 2018; 35:26–32
59. Zaghiyan K, Mendelson B, Eng M, Ovsepyan G, Mirocha J, Fleshner P: Randomized clinical trial comparing laparoscopic versus ultrasound-guided transversus abdominis plane block in minimally invasive colorectal surgery. *Dis Colon Rectum* 2019; 62:203–10

60. Griffiths JD, Barron FA, Grant S, Bjorksten AR, Hebbard P, Royse CF: Plasma ropivacaine concentrations after ultrasound-guided transversus abdominis plane block. *Br J Anaesth* 2010; 105:853–6
61. Latzke D, Marhofer P, Kettner SC, Koppatz K, Turnheim K, Lackner E, Sauermann R, Müller M, Zeitlinger M: Pharmacokinetics of the local anesthetic ropivacaine after transversus abdominis plane block in healthy volunteers. *Eur J Clin Pharmacol* 2012; 68:419–25
62. Kitayama M, Wada M, Hashimoto H, Kudo T, Takada N, Hirota K: Effects of adding epinephrine on the early systemic absorption kinetics of local anesthetics in abdominal truncal blocks. *J Anesth* 2014; 28:631–4
63. Murouchi T, Iwasaki S, Yamakage M: Chronological changes in ropivacaine concentration and analgesic effects between transversus abdominis plane block and rectus sheath block. *Reg Anesth Pain Med* 2015; 40:568–71
64. Yasumura R, Kobayashi Y, Ochiai R: A comparison of plasma levobupivacaine concentrations following transversus abdominis plane block and rectus sheath block. *Anaesthesia* 2016; 71:544–9
65. Kato N, Fujiwara Y, Harato M, Kurokawa S, Shibata Y, Harada J, Komatsu T: Serum concentration of lidocaine after transversus abdominis plane block. *J Anesth* 2009; 23:298–300
66. Rosenberg PH, Veering BT, Urmey WF: Maximum recommended doses of local anesthetics: A multifactorial concept. *Reg Anesth Pain Med* 2004; 29:564–75; discussion 524
67. Neal JM, Barrington MJ, Fettiplace MR, Gitman M, Memtsoudis SG, Mörwald EE, Rubin DS, Weinberg G: The third American Society of Regional Anesthesia and Pain Medicine practice advisory on local anesthetic systemic toxicity: Executive summary 2017. *Reg Anesth Pain Med* 2018; 43:113–23
68. Torup H, Mitchell AU, Breindahl T, Hansen EG, Rosenberg J, Møller AM: Potentially toxic concentrations in blood of total ropivacaine after bilateral transversus abdominis plane blocks: A pharmacokinetic study. *Eur J Anaesthesiol* 2012; 29:235–8
69. Griffiths JD, Le NV, Grant S, Bjorksten A, Hebbard P, Royse C: Symptomatic local anaesthetic toxicity and plasma ropivacaine concentrations after transversus abdominis plane block for Caesarean section. *Br J Anaesth* 2013; 110:996–1000
70. Kitayama M, Wada M, Hashimoto H, Kudo T, Yakoshi C, Hirota K: Plasma ropivacaine concentrations after ultrasound-guided transversus abdominis plane block for open retropubic prostatectomy. *J Anesth* 2014; 28:576–9
71. Toju K, Shiraiishi K, Hakozaki T, Isosu T, Murakawa M: Plasma ropivacaine concentration following ultrasound-guided subcostal transversus abdominis plane block in adults. *J Anesth* 2015; 29:146–8
72. Ollier E, Heritier F, Bonnet C, Hodin S, Beauchesne B, Molliex S, Delavenne X: Population pharmacokinetic model of free and total ropivacaine after transversus abdominis plane nerve block in patients undergoing liver resection. *Br J Clin Pharmacol* 2015; 80:67–74
73. Ding W, Li W, Zeng X, Li J, Jiang J, Guo C, Li W: Effect of adding dexmedetomidine to ropivacaine on ultrasound-guided dual transversus abdominis plane block after gastrectomy. *J Gastrointest Surg* 2017; 21:936–46
74. Li Z, Tang XH, Li Q, Zhang WJ, Tao T, Zhu T: Ultrasound-guided oblique sub-costal transversus abdominis plane block as the principal anesthesia technique in peritoneal dialysis catheter implantation and plasma ropivacaine concentration evaluation in ESRD patients: A prospective, randomized, double-blinded, controlled trial. *Perit Dial Int* 2018; 38:192–9
75. Corvetto MA, Echevarría GC, De La Fuente N, Mosqueira L, Solari S, Altermatt FR: Comparison of plasma concentrations of levobupivacaine with and without epinephrine for transversus abdominis plane block. *Reg Anesth Pain Med* 2012; 37:633–7
76. Ishida T, Tanaka S, Sakamoto A, Hirabayashi T, Kawamata M: Plasma ropivacaine concentration after TAP block in a patient with cardiac and renal failure. *Local Reg Anesth* 2018; 11:57–60
77. Lacassie HJ, Rolle A, Cortínez LI, Solari S, Corvetto MA, Altermatt FR: Pharmacokinetics of levobupivacaine with epinephrine in transversus abdominis plane block for postoperative analgesia after Caesarean section. *Br J Anaesth* 2018; 121:469–75
78. Sola C, Menacé C, Bringuier S, Saour AC, Raux O, Mathieu O, Capdevila X, Dadure C: Transversus abdominal plane block in children: Efficacy and safety: A randomized clinical study and pharmacokinetic profile. *Anesth Analg* 2019; 128:1234–41
79. Suresh S, De Oliveira GS Jr: Blood bupivacaine concentrations after transversus abdominis plane block in neonates: A prospective observational study. *Anesth Analg* 2016; 122:814–7
80. Trabelsi B, Charfi R, Bennasr L, Marzouk SB, Eljebari H, Jebabli N, Sassi MB, Trabelsi S, Maghrebi H: Pharmacokinetics of bupivacaine after bilateral ultrasound-guided transversus abdominis plane block following cesarean delivery under spinal anesthesia. *Int J Obstet Anesth* 2017; 32:17–20
81. Kumar SK, Rao V, Morris RG, Watts RW, Westley IS: Ropivacaine (total and unbound) and AGP concentrations after transversus abdominis plane block for analgesia after abdominal surgery. *Ther Drug Monit* 2014; 36:759–64
82. Hessian EC, Evans BE, Woods JA, Taylor DJ, Kinkel E, Bjorksten AR: Plasma ropivacaine concentrations during bilateral transversus abdominis plane infusions. *Br J Anaesth* 2013; 111:488–95

83. Sinha S, Palta S, Saroa R, Prasad A: Comparison of ultrasound-guided transversus abdominis plane block with bupivacaine and ropivacaine as adjuncts for postoperative analgesia in laparoscopic cholecystectomies. *Indian J Anaesth* 2016; 60:264–9
84. Ng SC, Habib AS, Sodha S, Carvalho B, Sultan P: High-dose versus low-dose local anaesthetic for transversus abdominis plane block post-Caesarean delivery analgesia: A meta-analysis. *Br J Anaesth* 2018; 120:252–63
85. Lahlou-Casulli M, Chaize-Avril C, Pouliquen E, Desfourneaux V, Mazoit JX, Malledant Y, Beloeil H: The median effective analgesic dose (ED50) of ropivacaine in ultrasound-guided transversus abdominis plane block for analgesia in reversal of ileostomy: A double-blind up-down dose-finding study. *Eur J Anaesthesiol* 2015; 32:640–4
86. Sola C, Menace C, Rochette A, Raux O, Bringuier S, Molinari N, Kalfa N, Capdevila X, Dadure C: Ultrasound-guided transversus abdominis plane block for herniorrhaphy in children: What is the optimal dose of levobupivacaine? *Eur J Anaesthesiol* 2014; 31:327–32
87. Raof RA, El Metainy SA, Alia DA, Wahab MA: Dexmedetomidine decreases the required amount of bupivacaine for ultrasound-guided transversus abdominis plane block in pediatric patients: A randomized study. *J Clin Anesth* 2017; 37:55–60
88. Ra YS, Kim CH, Lee GY, Han JI: The analgesic effect of the ultrasound-guided transverse abdominis plane block after laparoscopic cholecystectomy. *Korean J Anesthesiol* 2010; 58:362–8
89. De Oliveira GS Jr, Fitzgerald PC, Marcus RJ, Ahmad S, McCarthy RJ: A dose-ranging study of the effect of transversus abdominis block on postoperative quality of recovery and analgesia after outpatient laparoscopy. *Anesth Analg* 2011; 113:1218–25
90. Abdul Jalil RM, Yahya N, Sulaiman O, Wan Mat WR, Teo R, Izaham A, Rahman RA: Comparing the effectiveness of ropivacaine 0.5% versus ropivacaine 0.2% for transabdominis plane block in providing postoperative analgesia after appendectomy. *Acta Anaesthesiol Taiwan* 2014; 52:49–53
91. Erdoğan Arı D, Yıldırım Ar A, Karadoğan F, Özcabı Y, Koçoğlu A, Kılıç F, Akgün FN: Ultrasound-guided transversus abdominis plane block in patients undergoing open inguinal hernia repair: 0.125% bupivacaine provides similar analgesic effect compared to 0.25% bupivacaine. *J Clin Anesth* 2016; 28:41–6.
92. Prabhu R, Singh DR, Krishnaveni N: A comparative study of postoperative analgesia provided by ultrasound-guided transversus abdominis plane block using two concentrations of bupivacaine in patients undergoing inguinal hernia repair. *Anesth Essays Res* 2017; 11:934–9
93. Pinto Filho WA, Fernandes CR, Vale ML, Gomes JMA: Evaluation of transversus abdominis plane block in open appendectomy in paediatrics: Comparison of ropivacaine in two different concentrations. *Eur J Anaesthesiol* 2018; 35:547–8
94. Ping-Chen, Lin Q-S, Lin X-Z: Optimal concentration of the transversus abdominis plane block in enhanced recovery after surgery protocols for patients of advanced age undergoing laparoscopic rectal cancer surgery. *J Int Med Res* 2018; 46:4437–46
95. Baeriswyl M, Kirkham KR, Kern C, Albrecht E: The analgesic efficacy of ultrasound-guided transversus abdominis plane block in adult patients: A meta-analysis. *Anesth Analg* 2015; 121:1640–54
96. Abdallah FW, Chan VW, Brull R: Transversus abdominis plane block: A systematic review. *Reg Anesth Pain Med* 2012; 37:193–209
97. Forero M, Heikkila A, Paul JE, Cheng J, Thabane L: Lumbar transversus abdominis plane block: the role of local anesthetic volume and concentration—A pilot, prospective, randomized, controlled trial. *Pilot Feasibility Stud* 2015; 1:10
98. Şahin AS, Ay N, Şahbaz NA, Akay MK, Demiraran Y, Derbent A: Analgesic effects of ultrasound-guided transverse abdominis plane block using different volumes and concentrations of local analgesics after laparoscopic cholecystectomy. *J Int Med Res* 2017; 45:211–9
99. Kadam VR, Van Wijk RM, Moran JL, Ganesh S, Kumar A, Sethi R, Williams P: Continuous transversus abdominis plane block vs intermittent bolus for analgesia after abdominal surgery: A randomized trial. *J Pain Res* 2017; 10:1705–11
100. Khatibi B, Said ET, Sztain JF, Monahan AM, Gabriel RA, Furnish TJ, Tran JT, Donohue MC, Ilfeld BM: Continuous transversus abdominis plane nerve blocks. *Anesth Analg* 2017; 124:1298–303
101. Pehora C, Pearson AME, Kaushal A, Crawford MW, Johnston B: Dexamethasone as an adjuvant to peripheral nerve block. *Cochrane Database of Systematic Reviews* 2017, Issue 11. Art. No.: CD011770
102. Chen Q, An R, Zhou J, Yang B: Clinical analgesic efficacy of dexamethasone as a local anesthetic adjuvant for transversus abdominis plane (TAP) block: A meta-analysis. *PLoS One* 2018; 13:e0198923
103. Singh R, Kumar N, Jain A, Joy S: Addition of clonidine to bupivacaine in transversus abdominis plane block prolongs postoperative analgesia after cesarean section. *J Anaesthesiol Clin Pharmacol* 2016; 32:501–4
104. Sun Q, Liu S, Wu H, Ma H, Liu W, Fang M, Liu K, Pan Z: Dexmedetomidine as an adjuvant to local anesthetics in transversus abdominis plane block: A systematic review and meta-analysis. *Clin J Pain* 2019; 35:375–84

105. Almarakbi WA, Kaki AM: Addition of dexmedetomidine to bupivacaine in transversus abdominis plane block potentiates post-operative pain relief among abdominal hysterectomy patients: A prospective randomized controlled trial. *Saudi J Anaesth* 2014; 8:161–6
106. Rana S, Verma RK, Singh J, Chaudhary SK, Chandel A: Magnesium sulphate as an adjuvant to bupivacaine in ultrasound-guided transversus abdominis plane block in patients scheduled for total abdominal hysterectomy under subarachnoid block. *Indian J Anaesth* 2016; 60:174–9
107. Al-Refaey K, Usama EM, Al-Hefnawey E: Adding magnesium sulfate to bupivacaine in transversus abdominis plane block for laparoscopic cholecystectomy: A single blinded randomized controlled trial. *Saudi J Anaesth* 2016; 10:187–91
108. Abd-Elsalam KA, Fares KM, Mohamed MA, Mohamed MF, El-Rahman AMA, Tohamy MM: Efficacy of magnesium sulfate added to local anesthetic in a transversus abdominis plane block for analgesia following total abdominal hysterectomy: A randomized trial. *Pain Physician* 2017; 20:641–7
109. Ammar AS, Mahmoud KM, Kasemy ZA: Comparison between adenosine and magnesium sulphate as adjuvants for transversus abdominis plane block: A prospective randomized controlled trial. *Minerva Anesthesiol* 2018; 84:304–10
110. Hutchins J, Delaney D, Vogel RI, Ghebre RG, Downs LS Jr, Carson L, Mullany S, Teoh D, Geller MA: Ultrasound guided subcostal transversus abdominis plane (TAP) infiltration with liposomal bupivacaine for patients undergoing robotic assisted hysterectomy: A prospective randomized controlled study. *Gynecol Oncol* 2015; 138:609–13
111. Hutchins JL, Kesha R, Blanco F, Dunn T, Hochhalter R: Ultrasound-guided subcostal transversus abdominis plane blocks with liposomal bupivacaine vs. non-liposomal bupivacaine for postoperative pain control after laparoscopic hand-assisted donor nephrectomy: A prospective randomised observer-blinded study. *Anaesthesia* 2016; 71:930–7
112. Williams BA, Ibinson JW, Mangione MP, Scanlan RL, Cohen PZ: Clinical benchmarks regarding multimodal peripheral nerve blocks for postoperative analgesia: observations regarding combined perineural midazolam-clonidine-buprenorphine-dexamethasone. *Pain Med* 2015; 16:1–6
113. Kumar K, Kirksey MA, Duong S, Wu CL: A review of opioid-sparing modalities in perioperative pain management: Methods to decrease opioid use postoperatively. *Anesth Analg* 2017; 125:1749–60
114. McDonnell JG, Curley G, Carney J, Benton A, Costello J, Maharaj CH, Laffey JG: The analgesic efficacy of transversus abdominis plane block after cesarean delivery: A randomized controlled trial. *Anesth Analg* 2008; 106:186–91, table of contents
115. Belavy D, Coliha PJ, Hoe M, Phillip F: Ultrasound-guided transversus abdominis plane block for Caesarean delivery. *Br J Anaesth* 2009; 103:726–30
116. Costello JF, Moore AR, Wiczorek PM, Macarthur AJ, Balki M, Carvalho JC: The transversus abdominis plane block, when used as part of a multimodal regimen inclusive of intrathecal morphine, does not improve analgesia after cesarean delivery. *Reg Anesth Pain Med* 2009; 34:586–9
117. Kanazi GE, Aouad MT, Abdallah FW, Khatib MI, Adham AM, Harfoush DW, Siddik-Sayyid SM: The analgesic efficacy of subarachnoid morphine in comparison with ultrasound-guided transversus abdominis plane block after cesarean delivery: A randomized controlled trial. *Anesth Analg* 2010; 111:475–81
118. Baaj JM, Alsatli RA, Majaj HA, Babay ZA, Thallaj AK: Efficacy of ultrasound-guided transversus abdominis plane (TAP) block for postcesarean section delivery: A double-blind, placebo-controlled randomized study. *Middle East J Anaesthesiol* 2000; 20:821–6
119. McMorrow RC, Ni Mhuircheartaigh RJ, Ahmed KA, Aslani A, Ng SC, Conrick-Martin I, Dowling JJ, Gaffney A, Loughrey JP, McCaul CL: Comparison of transversus abdominis plane block vs spinal morphine for pain relief after Caesarean section. *Br J Anaesth* 2011; 106:706–12
120. Tan TT, Teoh WH, Woo DC, Ocampo CE, Shah MK, Sia AT: A randomised trial of the analgesic efficacy of ultrasound-guided transversus abdominis plane block after caesarean delivery under general anaesthesia. *Eur J Anaesthesiol* 2012; 29:88–94
121. Eslamian L, Jalili Z, Jamal A, Marsoosi V, Movafegh A: Transversus abdominis plane block reduces postoperative pain intensity and analgesic consumption in elective cesarean delivery under general anesthesia. *J Anesth* 2012; 26:334–8
122. Loane H, Preston R, Douglas MJ, Massey S, Papsdorf M, Tyler J: A randomized controlled trial comparing intrathecal morphine with transversus abdominis plane block for post-cesarean delivery analgesia. *Int J Obstet Anesth* 2012; 21:112–8
123. Singh S, Dhir S, Marmai K, Rehoul S, Silva M, Bradbury C: Efficacy of ultrasound-guided transversus abdominis plane blocks for post-cesarean delivery analgesia: A double-blind, dose-comparison, placebo-controlled randomized trial. *Int J Obstet Anesth* 2013; 22:188–93
124. Lee AJ, Palte HD, Chehade JM, Arheart KL, Ranasinghe JS, Penning DH: Ultrasound-guided bilateral transversus abdominis plane blocks in conjunction with intrathecal morphine for postcesarean analgesia. *J Clin Anesth* 2013; 25:475–82

125. McKeen DM, George RB, Boyd JC, Allen VM, Pink A: Transversus abdominis plane block does not improve early or late pain outcomes after Cesarean delivery: A randomized controlled trial. *Can J Anaesth* 2014; 61:631–40
126. Chandon M, Bonnet A, Burg Y, Barnichon C, DesMesnards-Smaja V, Sitbon B, Foiret C, Dreyfus JF, Rahmani J, Laloë PA, Fischler M, Le Guen M: Ultrasound-guided transversus abdominis plane block versus continuous wound infusion for post-caesarean analgesia: A randomized trial. *PLoS One* 2014; 9:e103971
127. Telnes A, Skogvoll E, Lonnée H: Transversus abdominis plane block vs. wound infiltration in Caesarean section: A randomised controlled trial. *Acta Anaesthesiol Scand* 2015; 59:496–504
128. Klasek F, Bourgoin A, Antonini F, Dazeas E, Bretelle F, Martin C, Baumstarck K, Leone M: Postoperative analgesia after caesarean section with transversus abdominis plane block or continuous infiltration wound catheter: A randomized clinical trial. *TAP vs. infiltration after caesarean section. Anaesth Crit Care Pain Med* 2016; 35:401–6
129. Jarraya A, Zghal J, Abidi S, Smaoui M, Kolsi K: Subarachnoid morphine versus TAP blocks for enhanced recovery after caesarean section delivery: A randomized controlled trial. *Anaesth Crit Care Pain Med* 2016; 35:391–3
130. Fusco P, Cofini V, Petrucci E, Scimia P, Pozzone T, Paladini G, Carta G, Necozone S, Borghi B, Marinangeli F: Transversus abdominis plane block in the management of acute postoperative pain syndrome after caesarean section: A randomized controlled clinical trial. *Pain Physician* 2016; 19:583–91
131. Tawfik MM, Mohamed YM, Elbadrawi RE, Abdelkhalek M, Mogahed MM, Ezz HM: Transversus abdominis plane block versus wound infiltration for analgesia after cesarean delivery: A randomized controlled trial. *Anesth Analg* 2017; 124:1291–7
132. Kupiec A, Zwierzchowski J, Kowal-Janicka J, Goździk W, Fuchs T, Pomorski M, Zimmer M, Kübler A: The analgesic efficiency of transversus abdominis plane (TAP) block after caesarean delivery. *Ginekol Pol* 2018; 89:421–4
133. Canacki E, Gultekien A, Cebeci Z, Hanedan B, Kilinc A: The analgesic efficacy of transverse abdominis plane block versus epidural block after Cesarean delivery: Which one is effective? TAP block? Epidural block? *Pain Res Manag* 2018 Oct 17; 2018:3562701
134. Champaneria R, Shah L, Wilson MJ, Daniels JP: Clinical effectiveness of transversus abdominis plane (TAP) blocks for pain relief after caesarean section: A meta-analysis. *Int J Obstet Anesth* 2016; 28:45–60
135. Mishriky BM, George RB, Habib AS: Transversus abdominis plane block after Cesarean delivery: A systematic review and meta-analysis. *Can J Anaesth* 2012; 59:766–78.
136. Abdallah FW, Halpern SH, Margarido CB: Transversus abdominis plane block for postoperative analgesia after Caesarean delivery performed under spinal anaesthesia? A systematic review and meta-analysis. *Br J Anaesth* 2012; 109:679–87
137. Ortiz J, Suliburk JW, Wu K, Bailard NS, Mason C, Minard CG, Palvadi RR: Bilateral transversus abdominis plane block does not decrease postoperative pain after laparoscopic cholecystectomy when compared with local anesthetic infiltration of trocar insertion sites. *Reg Anesth Pain Med* 2012; 37:188–92
138. Petersen PL, Stjernholm P, Kristiansen VB, Torup H, Hansen EG, Mitchell AU, Moeller A, Rosenberg J, Dahl JB, Mathiesen O: The beneficial effect of transversus abdominis plane block after laparoscopic cholecystectomy in day-case surgery: A randomized clinical trial. *Anesth Analg* 2012; 115:527–33
139. Chen CK, Tan PC, Phui VE, Teo SC: A comparison of analgesic efficacy between oblique subcostal transversus abdominis plane block and intravenous morphine for laparoscopic cholecystectomy. A prospective randomized controlled trial. *Korean J Anesthesiol* 2013; 64:511–6
140. Kokulu S, Bakı ED, Kaçar E, Bal A, Şenay H, Üstün KD, Yılmaz S, Ela Y, Sivacı RG: Effect of transversus abdominis plane block on cost of laparoscopic cholecystectomy anesthesia. *Med Sci Monit* 2014; 20:2794–8
141. Basaran B, Basaran A, Kozanhan B, Kasdogan E, Eryilmaz MA, Ozmen S: Analgesia and respiratory function after laparoscopic cholecystectomy in patients receiving ultrasound-guided bilateral oblique subcostal transversus abdominis plane block: A randomized double-blind study. *Med Sci Monit* 2015; 21:1304–12
142. Bava EP, Ramachandran R, Rewari V, Chandralekha, Bansal VK, Trikha A: Analgesic efficacy of ultrasound guided transversus abdominis plane block versus local anesthetic infiltration in adult patients undergoing single incision laparoscopic cholecystectomy: A randomized controlled trial. *Anesth Essays Res* 2016; 10:561–7
143. Breazu CM, Ciobanu L, Bartos A, Bodea R, Mircea PA, Ionescu D: Pethidine efficacy in achieving the ultrasound-guided oblique subcostal transversus abdominis plane block in laparoscopic cholecystectomy: A prospective study. *Bosn J Basic Med Sci* 2017; 17:67–73
144. Choi YM, Byeon GJ, Park SJ, Ok YM, Shin SW, Yang K: Postoperative analgesic efficacy of single-shot and continuous transversus abdominis plane block after laparoscopic cholecystectomy: A randomized controlled clinical trial. *J Clin Anesth* 2017; 39:146–51

145. Peng K, Ji FH, Liu HY, Wu SR: Ultrasound-guided transversus abdominis plane block for analgesia in laparoscopic cholecystectomy: A systematic review and meta-analysis. *Med Princ Pract* 2016; 25:237–46
146. Mitra S, Khandelwal P, Roberts K, Kumar S, Vadivelu N: Pain relief in laparoscopic cholecystectomy: A review of the current options. *Pain Pract* 2012; 12:485–96
147. Carney J, McDonnell JG, Ochana A, Bhinder R, Laffey JG: The transversus abdominis plane block provides effective postoperative analgesia in patients undergoing total abdominal hysterectomy. *Anesth Analg* 2008; 107:2056–60
148. Griffiths JD, Middle JV, Barron FA, Grant SJ, Popham PA, Royse CF: Transversus abdominis plane block does not provide additional benefit to multimodal analgesia in gynecological cancer surgery. *Anesth Analg* 2010; 111:797–801
149. AmrYA, Amin SA: Comparative study between effect of pre- versus post-incisional transversus abdominis plane block on acute and chronic post-abdominal hysterectomy pain. *Anesth Essays Res* 2011; 5:77–82
150. Atim A, Bilgin F, Kilickaya O, Purtuloglu T, Alanbay I, Orhan ME, Kurt E: The efficacy of ultrasound-guided transversus abdominis plane block in patients undergoing hysterectomy. *Anaesth Intensive Care* 2011; 39:630–4
151. Gharaei H, Imani F, Almasi F, Solimani M: The effect of ultrasound-guided TAPB on pain management after total abdominal hysterectomy. *Korean J Pain* 2013; 26:374–8
152. Gasanova I, Grant E, Way M, Rosero EB, Joshi GP: Ultrasound-guided transversus abdominal plane block with multimodal analgesia for pain management after total abdominal hysterectomy. *Arch Gynecol Obstet* 2013; 288:105–11
153. Bhattacharjee S, Ray M, Ghose T, Maitra S, Layek A: Analgesic efficacy of transversus abdominis plane block in providing effective perioperative analgesia in patients undergoing total abdominal hysterectomy: A randomized controlled trial. *J Anaesthesiol Clin Pharmacol* 2014; 30:391–6
154. Rojskjaer JO, Gade E, Kiel LB, Lind MN, Pedersen LM, Kristensen BB, Rasmussen YH, Foss NB: Analgesic effect of ultrasound-guided transversus abdominis plane block after total abdominal hysterectomy: A randomized, double-blind, placebo-controlled trial. *Acta Obstet Gynecol Scand* 2015; 94:274–8
155. Ishida T, Sakamoto A, Tanaka H, Ide S, Ishida K, Tanaka S, Mori T, Kawamata M: Transversus abdominis plane block with 0.25 % levobupivacaine: A prospective, randomized, double-blinded clinical study. *J Anesth* 2015; 29:557–61
156. Gasanova I, Alexander J, Ogunnaik B, Hamid C, Rogers D, Minhajuddin A, Joshi GP: Transversus abdominis plane block versus surgical site infiltration for pain management after open total abdominal hysterectomy. *Anesth Analg* 2015; 121:1383–8
157. Moyo N, Madzimbamuto FD, Shumbairerwa S: Adding a transversus abdominis plane block to parenteral opioid for postoperative analgesia following trans-abdominal hysterectomy in a low resource setting: A prospective, randomised, double blind, controlled study. *BMC Res Notes* 2016; 9:50
158. Ranjit S, Shrestha SK: Comparison of ultrasound guided transversus abdominis plane block versus local wound infiltration for post operative analgesia in patients undergoing gynaecological surgery under general anaesthesia. *Kathmandu Univ Med J (KUMJ)* 2014; 12:93–6
159. Cowlshaw PJ, Kotze PJ, Gleeson L, Chetty N, Stanbury LE, Harms PJ: Randomised comparison of three types of continuous anterior abdominal wall block after midline laparotomy for gynaecological oncology surgery. *Anaesth Intensive Care* 2017; 45:453–8
160. De Oliveira GS Jr, Milad MP, Fitzgerald P, Rahmani R, McCarthy RJ: Transversus abdominis plane infiltration and quality of recovery after laparoscopic hysterectomy: A randomized controlled trial. *Obstet Gynecol* 2011; 118:1230–7
161. Kane SM, Garcia-Tomas V, Alejandro-Rodriguez M, Astley B, Pollard RR: Randomized trial of transversus abdominis plane block at total laparoscopic hysterectomy: Effect of regional analgesia on quality of recovery. *Am J Obstet Gynecol* 2012; 207:419. e1–5
162. Calle GA, López CC, Sánchez E, De Los Ríos JF, Vásquez EM, Serna E, Arango AM, Castañeda JD, Vásquez RA, González A, Escobar A, Almanza LA: Transversus abdominis plane block after ambulatory total laparoscopic hysterectomy: Randomized controlled trial. *Acta Obstet Gynecol Scand* 2014; 93:345–50
163. Torup H, Bøgeskov M, Hansen EG, Palle C, Rosenberg J, Mitchell AU, Petersen PL, Mathiesen O, Dahl JB, Møller AM: Transversus abdominis plane (TAP) block after robot-assisted laparoscopic hysterectomy: A randomised clinical trial. *Acta Anaesthesiol Scand* 2015; 59:928–35
164. Ghisi D, Fanelli A, Vianello F, Gardini M, Mensi G, La Colla L, Danelli G: Transversus abdominis plane block for postoperative analgesia in patients undergoing total laparoscopic hysterectomy: A randomized, controlled, observer-blinded trial. *Anesth Analg* 2016; 123:488–92
165. Guardabassi DS, Lupi S, Agejas R, Allub JM, García-Fornari G: Efficacy of transversus abdominis plane block in laparoscopic hysterectomy. *Clinical trial. Rev Esp Anesthesiol Reanim* 2017; 64:257–61

166. Kawahara R, Tamai Y, Yamasaki K, Okuno S, Hanada R, Funato T: The analgesic efficacy of ultrasound-guided transversus abdominis plane block with mid-axillary approach after gynecologic laparoscopic surgery: A randomized controlled trial. *J Anaesthesiol Clin Pharmacol* 2015; 31:67–71
167. El Hachem L, Small E, Chung P, Moshier EL, Friedman K, Fenske SS, Gretz HF 3rd: Randomized controlled double-blind trial of transversus abdominis plane block versus trocar site infiltration in gynecologic laparoscopy. *Am J Obstet Gynecol* 2015; 212:182.e1–9
168. Hotujec BT, Spencer RJ, Donnelly MJ, Bruggink SM, Rose SL, Al-Niaimi A, Chappell R, Stewart SL, Kushner DM: Transversus abdominis plane block in robotic gynecologic oncology: A randomized, placebo-controlled trial. *Gynecol Oncol* 2015; 136:460–5
169. Korkmaz Toker M, Altiparmak B, Uysal Aİ, Demirebilek SG: The analgesic efficacy of oblique subcostal transversus abdominis plane block after laparoscopic hysterectomy: A randomized, controlled, observer-blinded study. *Medicine (Baltimore)* 2019; 98:e13994
170. Zhou H, Ma X, Pan J, Shuai H, Liu S, Luo X, Li R: Effects of transversus abdominis plane blocks after hysterectomy: A meta-analysis of randomized controlled trials. *J Pain Res* 2018; 11:2477–89
171. Bacal V, Rana U, McIsaac DI, Chen I: Transversus abdominis plane block for post hysterectomy pain: A systematic review and meta-analysis. *J Minim Invasive Gynecol* 2019; 26:40–52
172. Li XD, Han C, Yu WL: Is gabapentin effective and safe in open hysterectomy? A PRISMA compliant meta-analysis of randomized controlled trials. *J Clin Anesth* 2017; 41:76–83
173. Munro A, Sjaus A, George RB: Anesthesia and analgesia for gynecological surgery. *Curr Opin Anaesthesiol* 2018; 31:274–9
174. McDonnell JG, O'Donnell B, Curley G, Heffernan A, Power C, Laffey JG: The analgesic efficacy of transversus abdominis plane block after abdominal surgery: A prospective randomized controlled trial. *Anesth Analg* 2007; 104:193–7
175. Lapmahapaisan S, Tantemsapya N, Aroonpruksakul N, Maisat W, Suraseranivongse S: Efficacy of surgical transversus abdominis plane block for postoperative pain relief following abdominal surgery in pediatric patients. *Paediatr Anaesth* 2015; 25:614–20
176. Walter CJ, Maxwell-Armstrong C, Pinkney TD, Conaghan PJ, Bedfordth N, Gornall CB, Acheson AG: A randomised controlled trial of the efficacy of ultrasound-guided transversus abdominis plane (TAP) block in laparoscopic colorectal surgery. *Surg Endosc* 2013; 27:2366–72
177. Keller DS, Ermlich BO, Schiltz N, Champagne BJ, Reynolds HL Jr, Stein SL, Delaney CP: The effect of transversus abdominis plane blocks on postoperative pain in laparoscopic colorectal surgery: A prospective, randomized, double-blind trial. *Dis Colon Rectum* 2014; 57:1290–7
178. Smith SR, Draganic B, Pockney P, Holz P, Holmes R, Mcmanus B, Carroll R: Transversus abdominis plane blockade in laparoscopic colorectal surgery: A double-blind randomized clinical trial. *Int J Colorectal Dis* 2015; 30:1237–45
179. Torup H, Hansen EG, Bøgeskov M, Rosenberg J, Mitchell AU, Petersen PL, Mathiesen O, Dahl JB, Møller AM: Transversus abdominis plane block after laparoscopic colonic resection in cancer patients: A randomised clinical trial. *Eur J Anaesthesiol* 2016; 33:725–30
180. Tikuisis R, Miliuskas P, Lukoseviciene V, Samalavicius N, Dulskas A, Zabulienė L, Zabulis V, Urbonienė J: Transversus abdominis plane block for postoperative pain relief after hand-assisted laparoscopic colon surgery: A randomized, placebo-controlled clinical trial. *Tech Coloproctol* 2016; 20:835–44
181. Oh TK, Yim J, Kim J, Eom W, Lee SA, Park SC, Oh JH, Park JW, Park B, Kim DH: Effects of preoperative ultrasound-guided transversus abdominis plane block on pain after laparoscopic surgery for colorectal cancer: A double-blind randomized controlled trial. *Surg Endosc* 2017; 31:127–34
182. Rashid A, Gorissen KJ, Ris E, Gosselink MP, Shorthouse JR, Smith AD, Pandit JJ, Lindsey I, Crabtree NA: No benefit of ultrasound-guided transversus abdominis plane blocks over wound infiltration with local anaesthetic in elective laparoscopic colonic surgery: Results of a double-blind randomized controlled trial. *Colorectal Dis* 2017; 19:681–9
183. Liu L, Xie YH, Zhang W, Chai XQ: Effect of transversus abdominis plane block on postoperative pain after colorectal surgery: A meta-analysis of randomized controlled trials. *Med Princ Pract* 2018; 27:158–65
184. Oh TK, Lee SJ, Do SH, Song IA: Transversus abdominis plane block using a short-acting local anesthetic for postoperative pain after laparoscopic colorectal surgery: A systematic review and meta-analysis. *Surg Endosc* 2018; 32:545–52
185. Tornero-Campello G: Transversus abdominis plane block should be compared with epidural for postoperative analgesia after abdominal surgery. *Anesth Analg* 2007; 105:281–2; author reply 282–3
186. Rao Kadam V, Van Wijk RM, Moran JI, Miller D: Epidural versus continuous transversus abdominis plane catheter technique for postoperative analgesia after abdominal surgery. *Anaesth Intensive Care* 2013; 41:476–81

187. Wu Y, Liu F, Tang H, Wang Q, Chen L, Wu H, Zhang X, Miao J, Zhu M, Hu C, Goldsworthy M, You J, Xu X: The analgesic efficacy of subcostal transversus abdominis plane block compared with thoracic epidural analgesia and intravenous opioid analgesia after radical gastrectomy. *Anesth Analg* 2013; 117:507–13
188. Torgeson M, Kileny J, Pfeifer C, Narkiewicz L, Obi S: Conventional epidural vs transversus abdominis plane block with liposomal bupivacaine: A randomized trial in colorectal surgery. *J Am Coll Surg* 2018; 227:78–83
189. Felling DR, Jackson MW, Ferraro J, Battaglia MA, Albright JJ, Wu J, Genord CK, Brockhaus KK, Bhave RA, McClure AM, Shanker BA, Cleary RK: Liposomal bupivacaine transversus abdominis plane block versus epidural analgesia in a colon and rectal surgery enhanced recovery pathway: A randomized clinical trial. *Dis Colon Rectum* 2018; 61:1196–204
190. Shaker TM, Carroll JT, Chung MH, Koehler TJ, Lane BR, Wolf AM, Wright GP: Efficacy and safety of transversus abdominis plane blocks versus thoracic epidural anesthesia in patients undergoing major abdominal oncologic resections: A prospective, randomized controlled trial. *Am J Surg* 2018; 215:498–501
191. Maeda A, Shibata SC, Kamibayashi T, Fujino Y: Continuous subcostal oblique transversus abdominis plane block provides more effective analgesia than single-shot block after gynaecological laparotomy: A randomised controlled trial. *Eur J Anaesthesiol* 2015; 32:514–5
192. Niraj G, Kelkar A, Jeyapalan I, Graff-Baker P, Williams O, Darbar A, Maheshwaran A, Powell R: Comparison of analgesic efficacy of subcostal transversus abdominis plane blocks with epidural analgesia following upper abdominal surgery. *Anaesthesia* 2011; 66:465–71
193. Wahba SS, Kamal SM: Analgesic efficacy and outcome of transversus-abdominis plane block versus low thoracic-epidural analgesia after laparotomy in ischemic heart disease patients. *J Anesth* 2014; 28:517–23
194. Ganapathy S, Sondekoppam RV, Terlecki M, Brookes J, Das Adhikary S, Subramanian L: Comparison of efficacy and safety of lateral-to-medial continuous transversus abdominis plane block with thoracic epidural analgesia in patients undergoing abdominal surgery: A randomised, open-label feasibility study. *Eur J Anaesthesiol* 2015; 32:797–804
195. Niraj G, Searle A, Mathews M, Misra V, Baban M, Kiani S, Wong M: Analgesic efficacy of ultrasound-guided transversus abdominis plane block in patients undergoing open appendectomy. *Br J Anaesth* 2009; 103:601–5
196. Carney J, Finnerty O, Rauf J, Curley G, McDonnell JG, Laffey JG: Ipsilateral transversus abdominis plane block provides effective analgesia after appendectomy in children: A randomized controlled trial. *Anesth Analg* 2010; 111:998–1003
197. Ghimire A, Bhattarai B, Prasad JN, Shah SP: The analgesic effectiveness of ipsilateral transversus abdominis plane block in adult patients undergoing appendectomy: A prospective randomized controlled trial. *Kathmandu Univ Med J (KUMJ)* 2015; 13:361–5
198. Sandeman DJ, Bennett M, Dilley AV, Perczuk A, Lim S, Kelly KJ: Ultrasound-guided transversus abdominis plane blocks for laparoscopic appendectomy in children: a prospective randomized trial. *Br J Anaesth* 2011; 106:882–6
199. Tanggaard K, Jensen K, Lenz K, Vazin M, Binzer J, Lindberg-Larsen VO, Niegsch M, Bendtsen TF, Jorgensen LN, Børglum J: A randomised controlled trial of bilateral dual transversus abdominis plane blockade for laparoscopic appendectomy. *Anaesthesia* 2015; 70:1395–400
200. Tupper-Carey DA, Fathil SM, Tan YK, Kan YM, Cheong CY, Siddiqui FJ, Assam PN: A randomised controlled trial investigating the analgesic efficacy of transversus abdominis plane block for adult laparoscopic appendectomy. *Singapore Med J* 2017; 58:481–7
201. Sahin L, Sahin M, Gul R, Saricicek V, Isikay N: Ultrasound-guided transversus abdominis plane block in children: A randomised comparison with wound infiltration. *Eur J Anaesthesiol* 2013; 30:409–14
202. Petersen PL, Mathiesen O, Stjernholm P, Kristiansen VB, Torup H, Hansen EG, Mitchell AU, Moeller A, Rosenberg J, Dahl JB: The effect of transversus abdominis plane block or local anaesthetic infiltration in inguinal hernia repair: A randomised clinical trial. *Eur J Anaesthesiol* 2013; 30:415–21
203. Salman AE, Yetişir F, Yürekli B, Aksoy M, Yildirim M, Kiliç M: The efficacy of the semi-blind approach of transversus abdominis plane block on postoperative analgesia in patients undergoing inguinal hernia repair: A prospective randomized double-blind study. *Local Reg Anesth* 2013; 6:1–7
204. Heil JW, Nakanote KA, Madison SJ, Loland VJ, Mariano ER, Sandhu NS, Bishop ML, Agarwal RR, Proudfoot JA, Ferguson EJ, Morgan AC, Ilfeld BM: Continuous transversus abdominis plane (TAP) blocks for postoperative pain control after hernia surgery: A randomized, triple-masked, placebo-controlled study. *Pain Med* 2014; 15:1957–64
205. Kendigelen P, Tutuncu AC, Erbabacan E, Ekici B, Köksal G, Altındaş F, Kaya G: Ultrasound-assisted transversus abdominis plane block vs wound infiltration in pediatric patient with inguinal hernia: randomized controlled trial. *J Clin Anesth* 2016; 30:9–14
206. Abu Elyazed MM, Mostafa SF, Abdullah MA, Eid GM: The effect of ultrasound-guided transversus abdominis plane (TAP) block on postoperative analgesia and neuroendocrine stress response in pediatric

- patients undergoing elective open inguinal hernia repair. *Paediatr Anaesth* 2016; 26:1165–71
207. Kim MG, Kim SI, Ok SY, Kim SH, Lee SJ, Park SY, Lee SM, Jung BI: The analgesic effect of ultrasound-guided transverse abdominis plane block after laparoscopic totally extraperitoneal hernia repair. *Korean J Anesthesiol* 2012; 63:227–32
 208. Arora S, Chhabra A, Subramaniam R, Arora MK, Misra MC, Bansal VK: Transversus abdominis plane block for laparoscopic inguinal hernia repair: A randomized trial. *J Clin Anesth* 2016; 33:357–64
 209. Sakamoto B, Harker G, Eppstein AC, Gwirtz K: Efficacy of local anesthetic with dexamethasone on the quality of recovery following total extraperitoneal bilateral inguinal hernia repair: A randomized clinical trial. *JAMA Surg* 2016; 151:1108–14
 210. Gao T, Zhang JJ, Xi FC, Shi JL, Lu Y, Tan SJ, Yu WK: Evaluation of transversus abdominis plane (TAP) block in hernia surgery: A meta-analysis. *Clin J Pain* 2017; 33:369–75
 211. Joshi GP, Rawal N, Kehlet H, Bonnet F, Camu F, Fischer HB, Neugebauer EA, Schug SA, Simanski CJ; PROSPECT collaboration: Evidence-based management of postoperative pain in adults undergoing open inguinal hernia surgery. *Br J Surg* 2012; 99:168–85
 212. Skjelsager A, Ruhnau B, Kistorp TK, Kridina I, Hvarnæs H, Mathiesen O, Dahl JB: Transversus abdominis plane block or subcutaneous wound infiltration after open radical prostatectomy: A randomized study. *Acta Anaesthesiol Scand* 2013; 57:502–8
 213. Elkassabany N, Ahmed M, Malkowicz SB, Heitjan DF, Isserman JA, Ochroch EA: Comparison between the analgesic efficacy of transversus abdominis plane (TAP) block and placebo in open retropubic radical prostatectomy: A prospective, randomized, double-blinded study. *J Clin Anesth* 2013; 25:459–65
 214. Maquoi I, Joris JL, Dresse C, Vandenbosch S, Venneman I, Brichant JF, Hans GA: Transversus abdominis plane block or intravenous lignocaine in open prostate surgery: A randomized controlled trial. *Acta Anaesthesiol Scand* 2016; 60:1453–60
 215. Sinha A, Jayaraman L, Punhani D: Efficacy of ultrasound-guided transversus abdominis plane block after laparoscopic bariatric surgery: A double blind, randomized, controlled study. *Obes Surg* 2013; 23:548–53
 216. Albrecht E, Kirkham KR, Endersby RV, Chan VW, Jackson T, Okrainec A, Penner T, Jin R, Brull R: Ultrasound-guided transversus abdominis plane (TAP) block for laparoscopic gastric-bypass surgery: A prospective randomized controlled double-blinded trial. *Obes Surg* 2013; 23:1309–14
 217. Shirozu K, Kuramoto S, Kido S, Hayamizu K, Karashima Y, Hoka S: Hematoma after transversus abdominis plane block in a patient with HELLP syndrome: A case report. *A A Case Rep* 2017; 8:257–60
 218. Jankovic Z, Ahmad N, Ravishankar N, Archer F: Transversus abdominis plane block: How safe is it? *Anesth Analg* 2008; 107:1758–9
 219. Lancaster P, Chadwick M: Liver trauma secondary to ultrasound-guided transversus abdominis plane block. *Br J Anaesth* 2010; 104:509–10
 220. Long JB, Birmingham PK, De Oliveira GS Jr, Schaldenbrand KM, Suresh S: Transversus abdominis plane block in children: A multicenter safety analysis of 1994 cases from the PRAN (Pediatric Regional Anesthesia Network) database. *Anesth Analg* 2014; 119:395–9
 221. Walker G: Transversus abdominis plane block: A note of caution! *Br J Anaesth* 2010; 104:265
 222. Manatakis DK, Stamos N, Agalianos C, Karvelis MA, Gkiaourakis M, Davides D: Transient femoral nerve palsy complicating “blind” transversus abdominis plane block. *Case Rep Anesthesiol* 2013; 2013:874215
 223. Salaria ON, Kannan M, Kerner B, Goldman H: A rare complication of a TAP block performed after caesarean delivery. *Case Rep Anesthesiol* 2017; 2017:1072576
 224. Lancaster PS, Chadwick M: In reply. *Br J Anaesth* 2010; 104:783
 225. Naidu RK, Richebe P: Probable local anesthetic systemic toxicity in a postpartum patient with acute Fatty liver of pregnancy after a transversus abdominis plane block. *A A Case Rep* 2013; 1:72–4
 226. Weiss E, Jolly C, Dumoulin JL, Meftah RB, Blanié P, Laloë PA, Tabary N, Fischler M, Le Guen M: Convulsions in 2 patients after bilateral ultrasound-guided transversus abdominis plane blocks for cesarean analgesia. *Reg Anesth Pain Med* 2014; 39:248–51
 227. Scherrer V, Compere V, Loisel C, Dureuil B: Cardiac arrest from local anesthetic toxicity after a field block and transversus abdominis plane block: A consequence of miscommunication between the anesthesiologist and surgeon. *A A Case Rep* 2013; 1:75–6
 228. Corvetto MA, Altermatt FR: Improving transversus abdominis plane block safety. *Reg Anesth Pain Med* 2014; 39:440–1
 229. Furstein JS, Abd-Elsayed A, Wittkugel EP, Barnett S, Sadhasivam S: Motor blockade of abdominal muscles following a TAP block presenting as an abdominal bulge. *Paediatr Anaesth* 2013; 23:963–4
 230. Bortolato A, Ori C, Freo U: Transient abdominal motor block after a transversus abdominis plane block in an elderly patient. *Can J Anaesth* 2015; 62:837–8
 231. Bryskin RB, Londergan B, Wheatley R, Heng R, Lewis M, Barraza M, Mercer E, Ye G: Transversus abdominis plane block versus caudal epidural for lower abdominal surgery in children: A double-blinded randomized controlled trial. *Anesth Analg* 2015; 121:471–8

232. Sethi N, Pant D, Dutta A, Koul A, Sood J, Chugh PT: Comparison of caudal epidural block and ultrasonography-guided transversus abdominis plane block for pain relief in children undergoing lower abdominal surgery. *J Clin Anesth* 2016; 33:322–9
233. Sahin L, Soydinc MH, Sen E, Cavus O, Sahin M: Comparison of 3 different regional block techniques in pediatric patients. A prospective randomized single-blinded study. *Saudi Med J* 2017; 38:952–9
234. Melnikov AL, Bjoergo S, Kongsgaard UE: Thoracic paravertebral block versus transversus abdominis plane block in major gynecological surgery: A prospective, randomized, controlled, observer-blinded study. *Local Reg Anesth* 2012; 5:55–61
235. Blanco R, Ansari T, Riad W, Shetty N: Quadratus lumborum block versus transversus abdominis plane block for postoperative pain after cesarean delivery: A randomized controlled trial. *Reg Anesth Pain Med* 2016; 41:757–62
236. Öksüz G, Bilal B, Gürkan Y, Urfalioğlu A, Arslan M, Gişi G, Öksüz H: Quadratus lumborum block versus transversus abdominis plane block in children undergoing low abdominal surgery: A randomized controlled trial. *Reg Anesth Pain Med* 2017; 42:674–9
237. Yousef NK: Quadratus lumborum block versus transversus abdominis plane block in patients undergoing total abdominal hysterectomy: A randomized prospective controlled trial. *Anesth Essays Res* 2018; 12:742–7
238. Kumar GD, Gnanasekar N, Kurhekar P, Prasad TK: A comparative study of transversus abdominis plane block versus quadratus lumborum block for postoperative analgesia following lower abdominal surgeries: A prospective double-blinded study. *Anesth Essays Res* 2018; 12:919–23
239. Abo-Zeid MA, Al-Refaey AK, Zeina AM: Surgically-assisted abdominal wall blocks for analgesia after abdominoplasty: A prospective randomized trial. *Saudi J Anaesth* 2018; 12:593–8
240. Fredrickson MJ, Paine C, Hamill J: Improved analgesia with the ilioinguinal block compared to the transversus abdominis plane block after pediatric inguinal surgery: A prospective randomized trial. *Paediatr Anaesth* 2010; 20:1022–7
241. Aveline C, Le Hetet H, Le Roux A, Vautier P, Cognet F, Vinet E, Tison C, Bonnet F: Comparison between ultrasound-guided transversus abdominis plane and conventional ilioinguinal/iliohypogastric nerve blocks for day-case open inguinal hernia repair. *Br J Anaesth* 2011; 106:380–6
242. Okur O, Tekgul ZT, Erkan N: Comparison of efficacy of transversus abdominis plane block and iliohypogastric/ilioinguinal nerve block for postoperative pain management in patients undergoing inguinal herniorrhaphy with spinal anesthesia: A prospective randomized controlled open-label study. *J Anesth* 2017; 31:678–85
243. Kiran LV, Sivashanmugam T, Kumar VRH, Krishnaveni N, Parthasarathy S: Relative efficacy of ultrasound-guided ilioinguinal-iliohypogastric nerve block versus transverse abdominis plane block for postoperative analgesia following lower segment cesarean section: A prospective, randomized observer-blinded trial. *Anesth Essays Res* 2017; 11:713–7
244. Kamal K, Jain P, Bansal T, Ahlawat G: A comparative study to evaluate ultrasound-guided transversus abdominis plane block versus ilioinguinal iliohypogastric nerve block for postoperative analgesia in adult patients undergoing inguinal hernia repair. *Indian J Anesth* 2018; 62:292–7
245. Tran DQ, Boezaart AP, Neal JM: Beyond ultrasound guidance for regional anesthesiology. *Reg Anesth Pain Med* 2017; 42:556–63