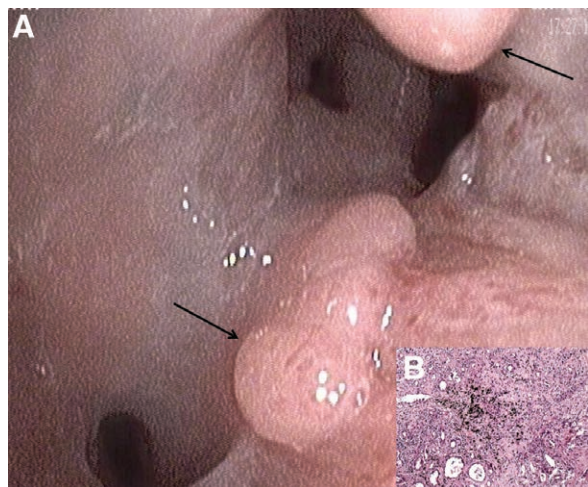


Tracheobronchial Polyposis after Inhalation Trauma

Jonas S. Heitmann, M.D., Birgit Federmann, M.D., Jürgen Hetzel, M.D., Maik Häntschel, M.D.



There is a huge variety of reasons for difficult weaning. This image represents a rare case of weaning failure, which was taken 8 weeks after admission to hospital by flexible bronchoscopy (*panel A*). It revealed multiple endotracheal and endobronchial polypoid lesions (*arrows*), accompanied by a severe bronchial edema. All parts of the bronchial tree were affected to a different degree (see video, Supplemental Digital Content, <http://links.lww.com/ALN/C54>).

Besides obvious burn injuries, in rare cases inhalation trauma leads to severe, obstructing tracheobronchial polyposis. Therefore, repetitive bronchoscopy should be considered based on the appearance of subsequent symptoms such as stridor, coughing, hemoptysis, wheezing, or recurrent airway infections. The stenosis of the central airways may hamper or even prevent successful weaning.

Tracheobronchial polyposis is usually associated with malignancies (*e.g.*, metastasis or primary lung tumor) or infection (*e.g.*, papilloma virus, mycobacteriosis).^{1,2} Polyposis is also described after inhalation trauma; however,

pathogenesis has so far not been definitely clarified.³ Histological examination (hematoxylin and eosin staining, 10× original magnification) of bronchoscopic cryobiopsy revealed anthracotic pigment (soot) surrounded by granulomatosis with both acute and chronic inflammation (*panel B*). Due to lacking evidence-based treatment and as suggested by others and us, interventional bronchoscopy (*e.g.*, bronchoscopic cryorecanalizations) should be used in order to remove the stenosing polyps and to restore airway patency.³ Moreover, treating physicians should consider treatment with inhalative and systemic steroids.

In conclusion, early and subsequent bronchoscopy as part of posttrauma management should be performed in all patients with burn injuries who are suspicious for inhalation, in particular soot.

Competing Interests

The authors declare no competing interests.

Correspondence

Address correspondence to Dr. Häntschel: maik.haentschel@med.uni-tuebingen.de

References

- Asano T, Itoh G, Itoh M: Disseminated mycobacterium intracellulare infection in an HIV-negative, nonimmunosuppressed patient with multiple endobronchial polyps. *Respiration* 2002; 69:175–7
- Dursun AB, Demirag F, Bayiz H, Sertkaya D: Endobronchial metastases: A clinicopathological analysis. *Respirology* 2005; 10:510–4
- Shin B, Kim M, Yoo H, Kim SJ, Lee JE, Jeon K: Tracheobronchial polyps following thermal inhalation injury. *Tuberc Respir Dis (Seoul)* 2014; 76:237–9

Supplemental Digital Content is available for this article. Direct URL citations appear in the printed text and are available in both the HTML and PDF versions of this article. Links to the digital files are provided in the HTML text of this article on the Journal's Web site (www.anesthesiology.org).

From the Department of Hematology, Oncology, Rheumatology and Immunology, (J.S.H.), Institute of Pathology and Neuropathology (B.F.), and Department of Medical Oncology and Pulmonology (J.H., M.H.), University Hospital Tübingen, University of Tübingen, Tübingen, Germany.

Copyright © 2019, the American Society of Anesthesiologists, Inc. All Rights Reserved. *Anesthesiology* 2020; 132:157. DOI: 10.1097/ALN.0000000000002972