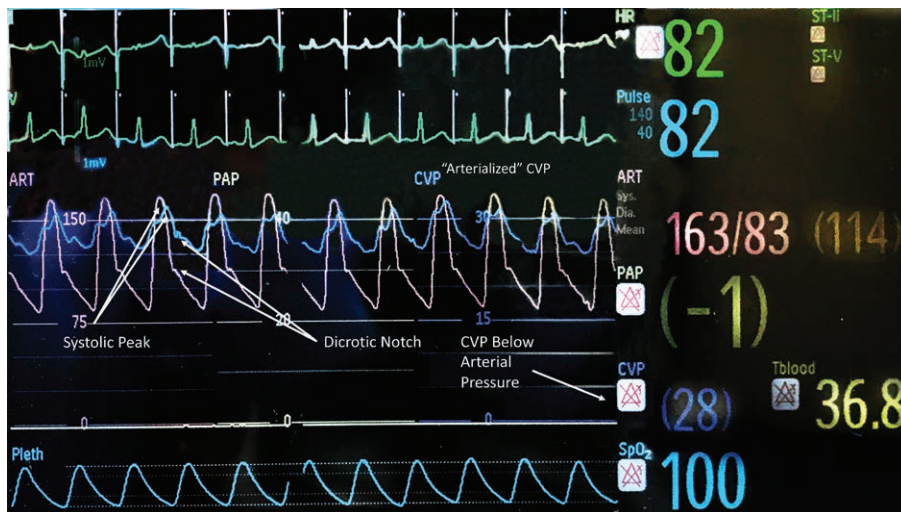


# “Arterialization” of the Central Venous Pressure Waveform from a Peripheral Arteriovenous Fistula

Adam D. Lichtman, M.D., F.A.S.E.



A 65-yr-old male had a history of end-stage renal disease requiring hemodialysis *via* a left forearm arteriovenous fistula. After placement of a left-sided internal jugular vein catheter, a central venous waveform was noted (see *Image*).

Patients with renal failure often receive hemodialysis *via* a surgically created arteriovenous fistula. As the central line is on the ipsilateral side as the fistula “arterialized,” or miniaturized, arterial tracing is produced in the venous waveform. The peak of the central venous pulsations corresponds with the systolic peak of the arterial blood pressure. A dicotic notch is also noted and corresponds with that of the arterial wave.

In patients requiring central venous access, pulsatile flow is most commonly associated with arterial puncture. Arteriovenous fistula creation causes arterial blood to enter the low-resistance venous circulation, increasing cardiac preload.<sup>1</sup> This may cause “arterialization” or pulsatile venous flow resembling an arterial wave form if a central line is placed on the ipsilateral side to an arteriovenous fistula.<sup>2</sup> When encountering “arterialization,” proper confirmation of catheter location to exclude arterial puncture is required. Methods to ensure correct location include: pressure transduction, identification of the guide wire in the right atrium using echocardiography or fluoroscopy, and compression of the venous limb of the fistula to eliminate the referred arterial wave.<sup>3</sup>

For anesthesiologists who infrequently place central venous catheters, “arterialization” may not be recognized

as a normal variant. Recognition will prevent the misperception of inadvertent arterial puncture and potentially subjecting patients to additional venipuncture attempts.

## Competing Interests

The author declares no competing interests.

## Correspondence

Address correspondence to Dr. Lichtman: lichtad@med.cornell.edu

## References

1. Yee LL, Despotis GJ: Increased venous hemoglobin saturation during percutaneous right internal jugular vein cannulation in a patient with a mature right forearm arteriovenous hemodialysis fistula. *ANESTHESIOLOGY* 1990; 73:184–6
2. Williamson RM, Werstler E: Central lines in patients with AV fistula. *Anaesthesia* 2006; 61:819–20
3. Angaramo G, Francalancia N, Shubjeet K, Brea F: A novel maneuver used to rule out intraarterial placement of the introducer sheath in a patient with an ipsilateral mature forearm hemodialysis fistula. *ANESTHESIOLOGY* 2004; 101:1052

Published online first on September 12, 2019. From the Department of Anesthesiology, Weill Medical College of Cornell University, New York, New York.

Copyright © 2020, the American Society of Anesthesiologists, Inc. All Rights Reserved. *Anesthesiology* 2020; 132:373. DOI: 10.1097/ALN.0000000000002984