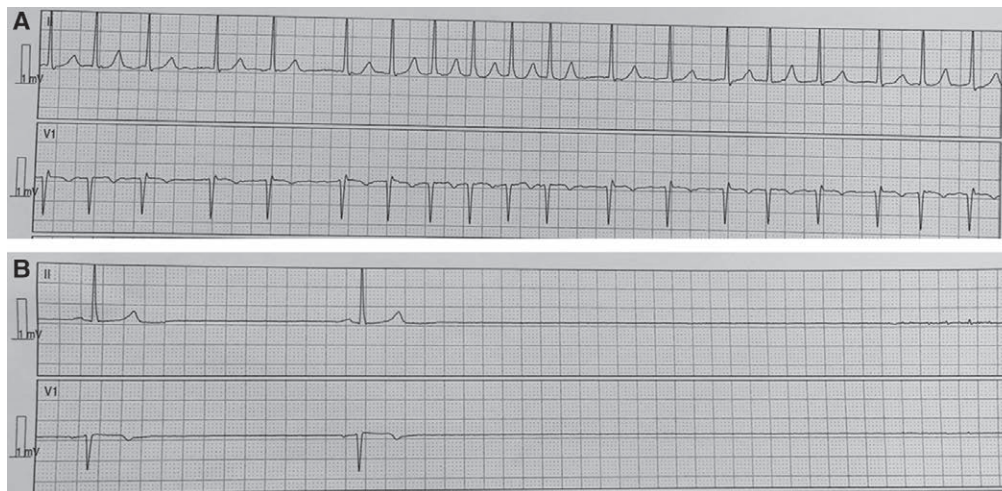
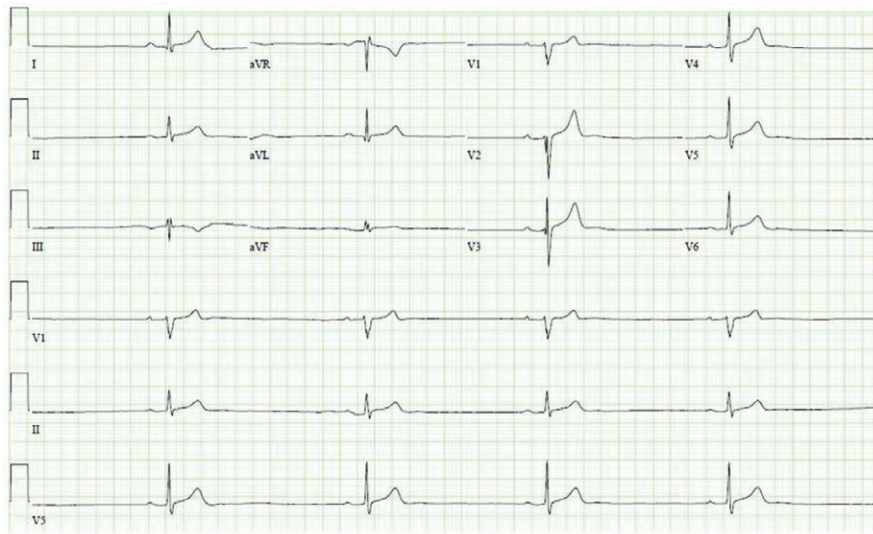


# Sick Sinus Syndrome

## Sinus Node Dysfunction in the Elderly

Sandeep Khanna, M.D., Roshni Sreedharan, M.D., Carlos Trombetta, M.D., M.Ed., Kurt Ruetzler, M.D.



Sick sinus syndrome is a clinical syndrome characterized by sinus node dysfunction. It presents in elderly patients with bradyarrhythmias and nonspecific symptoms such as fatigue or syncope. Consequently, the diagnosis is often overlooked. Anesthesia can unmask sinus node dysfunction, which then manifests as significant atrial dysrhythmias and “rarely” asystole.<sup>1–3</sup> The

accompanying images demonstrate this circumstance and are from an elderly patient who underwent pericardial drainage under propofol sedation. While marked sinus bradycardia is seen on the preoperative electrocardiogram (*top image*), the postprocedure electrocardiogram demonstrates supraventricular tachycardia (*bottom image A*) that eventually transitions to asystole (*bottom image B*).

Published online first on October 14, 2019. From the Departments of General Anesthesiology (S.K., R.S., K.R.), Outcomes Research (S.K., K.R.), Critical Care Medicine (R.S.), and Cardiothoracic Anesthesiology (C.T.), Cleveland Clinic Foundation, Cleveland, Ohio.

Copyright © 2020, the American Society of Anesthesiologists, Inc. All Rights Reserved. Anesthesiology 2020; 132:377–8. DOI: 10.1097/ALN.0000000000003004

Although asymptomatic sinus bradycardia does not necessitate postponement of surgery, presence of a significant bradyarrhythmia requires consultation. Regardless of how slow the heart rate is, a clinically important bradyarrhythmia is distinguished by the presence of symptoms such as syncope, confusion, and dyspnea. Bradycardia-mediated reduction in cardiac output compromises cerebral perfusion, resulting in syncope. Additionally, severe bradycardia increases left ventricular end-diastolic pressure, precipitating pulmonary congestion and dyspnea.

Autonomic imbalances from central neuraxial anesthesia-induced sympathectomy and use of sympatholytic drugs, such as propofol, remifentanyl, dexmedetomidine, or vecuronium, during general anesthesia can unveil latent sinus node dysfunction and trigger life-threatening atropine-resistant bradyarrhythmias. Accompanying features in anesthetized patients include precipitous hypotension, declining oxygen saturation, and pulmonary rales. Such bradyarrhythmias often require treatment with epinephrine or external pacing. As transcutaneous pacing may not provide reliable electrical capture, it is advisable to institute

temporary transvenous pacing before anesthesia induction when sinus node dysfunction is suspected.<sup>1-3</sup>

### Competing Interests

The authors declare no competing interests.

### Correspondence

Address correspondence to Dr. Khanna: khannas@ccf.org

### References

1. Staikou C, Chondrogiannis K, Mani A: Perioperative management of hereditary arrhythmogenic syndromes. *Br J Anaesth* 2012; 108:730–44
2. Atlee JL: Perioperative cardiac dysrhythmias: Diagnosis and management. *ANESTHESIOLOGY* 1997; 86:1397–424
3. Underwood SM, Glynn CJ: Sick sinus syndrome manifest after spinal anaesthesia. *Anaesthesia* 1988; 43:307–9