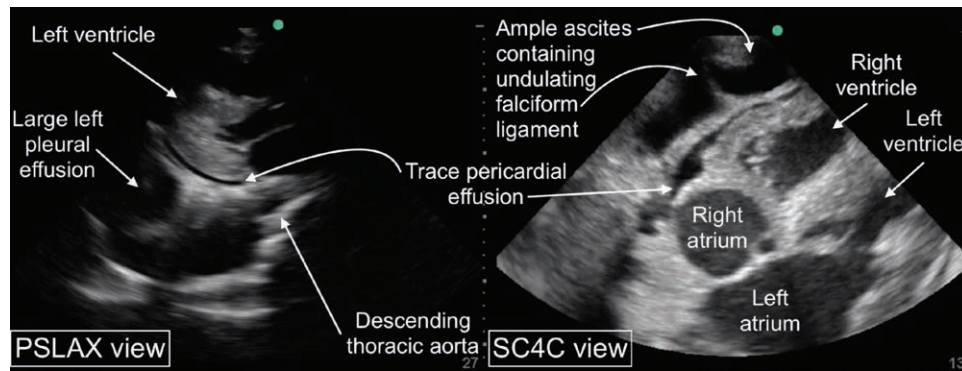


Not All Pericardiac Fluid Is Pericardial

Ultrasound of Pericardial Effusion and Two of Its Mimics

Yuriy S. Bronshteyn, M.D., F.A.S.E., Jennifer N. Hauck, M.D., Rebecca A. Schroeder, M.D., Atilio Barbeito, M.D., M.P.H.



Focused cardiac ultrasound is emerging as a useful tool in preoperative evaluation and crisis management. Focused cardiac ultrasound's scope of practice includes screening for the presence/absence of pericardial effusion.¹ Thus, practitioners of focused cardiac ultrasound should be able to differentiate a pericardial effusion from conditions that can mimic it, especially in an emergency. These focused cardiac ultrasound images were obtained in a patient who presented with hypotension and was found to have a trace pericardial effusion along with two other conditions that are often misdiagnosed as pericardial effusion.^{2,3}

Fluid collections on ultrasound appear as anechoic/hypoechoic (dark) spaces with posterior acoustic enhancement (brightness deep to the effusion). In this parasternal long-axis view (PSLAX), two such fluid collections are seen posterior to the heart. In any parasternal long-axis view, fluid that dissects into the plane between the heart and descending aorta is pericardial whereas fluid deep to the heart unable to dissect into this plane is classically a left pleural effusion.³ Thus, this parasternal long-axis view shows a trace pericardial effusion and a large left pleural effusion containing atelectatic lung (Supplemental Digital Content 1, <http://links.lww.com/ALN/C91>).

In the subcostal four-chamber view (SC4C), two fluid collections appear superficial to the heart. In any subcostal four-chamber view, circumferential pericardial fluid follows the contours of the heart. In contrast, ascites fails to

follow the contours of the heart and additionally contains an undulating falciform ligament² (Supplemental Digital Content 2, <http://links.lww.com/ALN/C92>). Thus, this image shows the patient's trace pericardial effusion and also prominent ascites.

Competing Interests

The authors declare no competing interests.

Correspondence

Address correspondence to Dr. Bronshteyn: Yuriy.bronshteyn@gmail.com

References

1. Via G, Hussain A, Wells M, Reardon R, ElBarbary M, Noble VE, Tsung JW, Neskovic AN, Price S, Oren-Grinberg A, Liteplo A, Cordioli R, Naqvi N, Rola P, Poelaert J, Gulić TG, Sloth E, Labovitz A, Kimura B, Breikreutz R, Masani N, Bowra J, Talmor D, Guarracino F, Goudie A, Xiaoting W, Chawla R, Galderisi M, Blaivas M, Petrovic T, Storti E, Neri L, Melniker L; International Liaison Committee on Focused Cardiac UltraSound (ILC-FoCUS); International Conference on Focused Cardiac UltraSound (IC-FoCUS): International evidence-based recommendations for

Supplemental Digital Content is available for this article. Direct URL citations appear in the printed text and are available in both the HTML and PDF versions of this article. Links to the digital files are provided in the HTML text of this article on the Journal's Web site (www.anesthesiology.org).

Published online first on November 14, 2019. From the Department of Anesthesiology, Duke University School of Medicine, Duke University Medical Center (J.N.H.), Durham Veterans Affairs Health Care System (Y.S.B., R.A.S., A.B.), Durham, North Carolina.

Copyright © 2019, the American Society of Anesthesiologists, Inc. All Rights Reserved. *Anesthesiology* 2020; 132:584–5. DOI: 10.1097/ALN.0000000000003047

- focused cardiac ultrasound. *J Am Soc Echocardiogr* 2014; 27:683.e1–683.e33
2. Cardello FP, Yoon DH, Halligan RE Jr, Richter H: The falciform ligament in the echocardiographic diagnosis of ascites. *J Am Soc Echocardiogr* 2006; 19:1074.e3–4
 3. Haaz WS, Mintz GS, Kotler MN, Parry W, Segal BL: Two dimensional echocardiographic recognition of the descending thoracic aorta: Value in differentiating pericardial from pleural effusions. *Am J Cardiol* 1980; 46:739–43