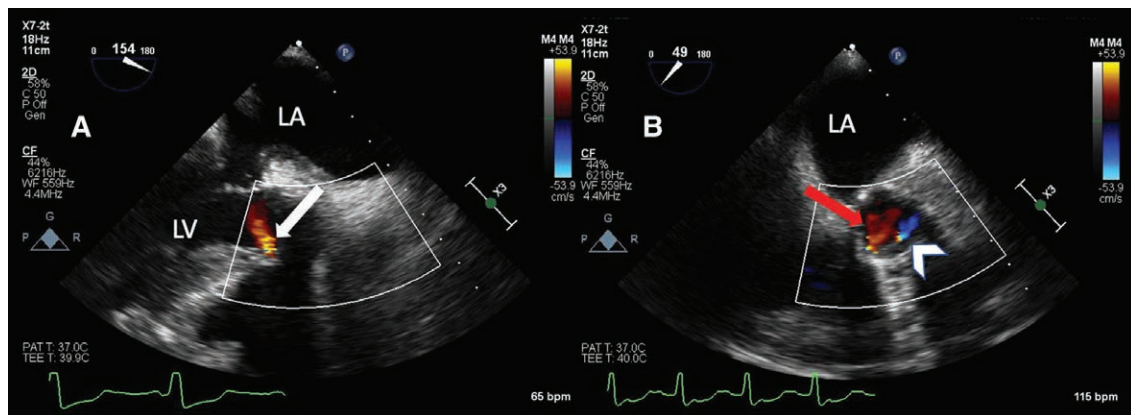


Temporary Prosthetic Valvular Insufficiency with the Inspiris Aortic Valve

Donn Marciniak, M.D., Andrej Alfirevic, M.D., Raphaele Chemtob, M.D., Per Wierup, M.D., Ph.D.



The Edwards Inspiris Resilia valve is a new bioprosthetic aortic valve designed to accept future valve-in-valve replacement *via* transcatheter aortic valve replacement. It is our repeated experience that this valve develops a significant but transient intravalvular leak immediately after separation from cardiopulmonary bypass (CPB) that mimics a paravalvular leak. Panel A of this image is a mid-esophageal long-axis view demonstrating a highly eccentric, posteriorly directed jet between the non- and right coronary cusps (*white arrow; LA indicates left atrium and LV is left ventricle*). Panel B is a mid-esophageal aortic valve short-axis view with an additional jet between the right and left coronary cusps (*red arrow*). Resolution occurs spontaneously in the minutes after separation from CPB.

Identification of the origin of prosthetic valvular insufficiency may be difficult due to highly eccentric jets and shadowing artifact. Misidentification as paravalvular insufficiency may result in an unnecessary attempt at revision, or conversely the risk of anemia, heart failure, and additional surgery if dismissed.¹ Multiplanar and three-dimensional images are needed for the challenging task of identifying jet origin and severity of prosthetic insufficiency.¹ The deep transgastric view can be particularly useful differentiating intra- *versus* paravalvular insufficiency due to the minimization of shadowing artifact. Epicardial echocardiography may be necessary because of shadowing artifact from the anterior sewing ring.^{2,3} It is our suspicion that this transient insufficiency is attributable to leakage through the expandable frame of the valve or to hydration of the leaflets. Careful assessment and tincture of time may be appropriate before attempting revision.

Competing Interests

The authors declare no competing interests.

Correspondence

Address correspondence to Dr. Marciniak: marcind@ccf.org

References

1. Ruiz CE, Hahn RT, Berrebi A, Borer JS, Cutlip DE, Fontana G, Gerosa G, Ibrahim R, Jelmin V, Jilaihawi H, Jolicoeur EM, Kliger C, Kronzon I, Leipsic J, Maisano F, Millan X, Nataf P, O'Gara PT, Pibarot P, Ramee SR, Rihal CS, Rodes-Cabau J, Sorajja P, Suri R, Swain JA, Turi ZG, Tuzcu EM, Weissman NJ, Zamorano JL, Serruys PW, Leon MB; Paravalvular Leak Academic Research Consortium: Clinical trial principles and endpoint definitions for paravalvular leaks in surgical prosthesis: An expert statement. *J Am Coll Cardiol* 2017; 69:2067–87
2. Jilaihawi H, Chakravarty T, Shiota T, Rafique A, Harada K, Shibayama K, Doctor N, Kashif M, Nakamura M, Mirocha J, Rami T, Okuyama K, Cheng W, Sadruddin O, Siegel R, Makkar RR: Heart-rate adjustment of transcatheter haemodynamics improves the prognostic evaluation of paravalvular regurgitation after transcatheter aortic valve implantation. *EuroIntervention* 2015; 11:456–64
3. Teeter EG, Dakik C, Cooter M, Samad Z, Ghadimi K, Harrison JK, Gaca J, Stafford-Smith M, Bottiger BA: Assessment of paravalvular leak after transcatheter aortic valve replacement: Transesophageal echocardiography compared with transthoracic echocardiography. *J Cardiothorac Vasc Anesth* 2017; 31:1278–84

Published online first on December 30, 2019. From the Departments of Cardiothoracic Anesthesia (D.M., A.A.) and Cardiothoracic Surgery (R.C., P.W.), Cleveland Clinic Foundation, Cleveland, Ohio.

Copyright © 2019, the American Society of Anesthesiologists, Inc. All Rights Reserved. *Anesthesiology* 2020; 132:897. DOI: 10.1097/ALN.0000000000003094