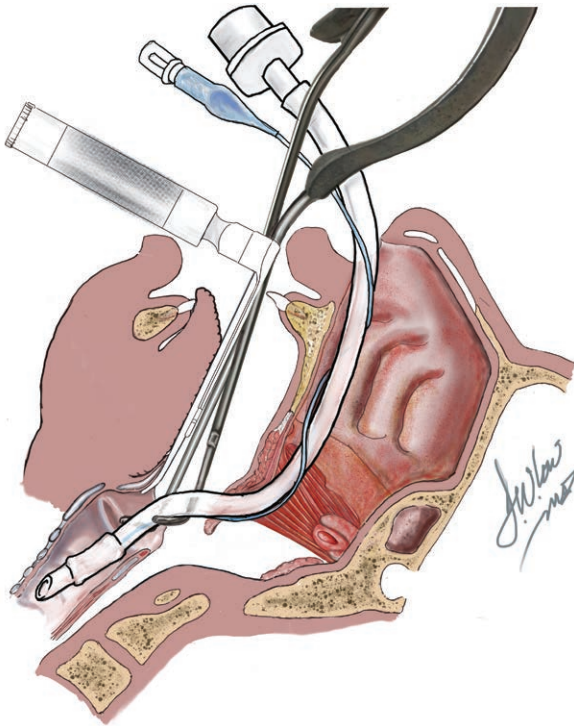


# Don't Let Your Student Fall Asleep

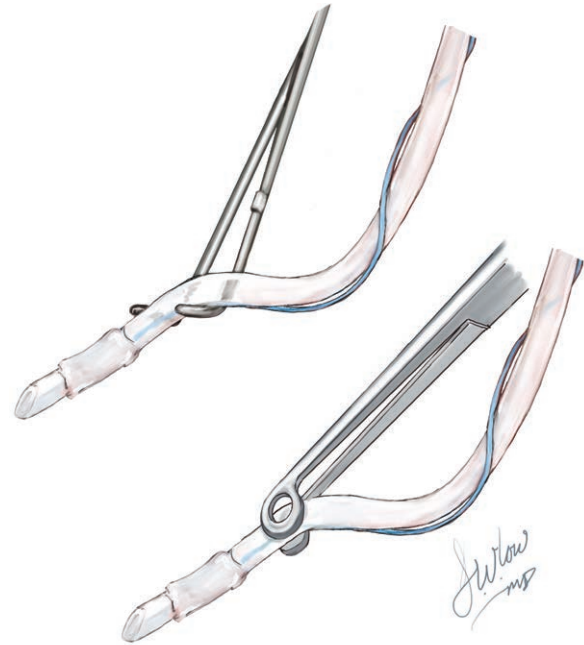
Alan Jay Schwartz, M.D., M.S.Ed., David W. Low, M.D., Samuel Hunter, M.D., Justin Lockman, M.D., M.S.Ed.



A student will often be overcome by sleep before understanding a teacher's words describe what can be depicted in an instant with an image. (Leonardo da Vinci, paraphrased, [https://en.wikipedia.org/wiki/A\\_picture\\_is\\_worth\\_a\\_thousand\\_words](https://en.wikipedia.org/wiki/A_picture_is_worth_a_thousand_words))

Teaching and learning psychomotor skills is difficult!<sup>1</sup> Effectively learning clinical skills requires the student to (1) understand the psychomotor task relevance, (2) view a skill demonstration by an expert, (3) hear a teacher's step-by-step verbalization of the task sequence, (4) understand what was said, and (5) perform the skill under a teacher's guidance.<sup>2</sup> The student must convert the teacher's words into a "mind's eye" image of what success looks like. Adding an image to the teacher's words conspicuously enhances the student's gestalt of the task.<sup>3</sup>

Nasotracheal intubation is a skill that exemplifies the value of coupling image(s) with words to facilitate learning. The learner must grasp both that the arc of the nasopharynx aims the tip of the endotracheal tube toward the anterior wall of the larynx and that the tip needs to be reoriented (bent) to the path of the glottis as it enters the trachea. The left image displays a sagittal drawing of the nasopharynx, glottis, and trachea with a laryngoscope exposing the glottis



and a tube bender reorienting an endotracheal tube so it slides into the trachea. The image clearly converts a teacher's words into an explicit and essential "mind's eye" image that the student needs to comprehend to successfully perform this psychomotor skill. Once conceptualized, the student can use the tube bender (right image, *top*) or more commonly available Magill forceps (right image, *bottom*) to successfully reorient the direction of the tube into the glottis and trachea without grabbing the cuff and potentially damaging it.

## Competing Interests

The authors declare no competing interests.

## Correspondence

Address correspondence to Dr. Schwartz: [schwartz@chop.edu](mailto:schwartz@chop.edu)

## References

1. Fred HL: Hyposkillia: Deficiency of clinical skills. *Tex Heart Inst J* 2005; 32:255–7
2. George JH, Doto FX: A simple five-step method for teaching clinical skills. *Fam Med* 2001; 33:577–8
3. Norris EM: The constructive use of images in medical teaching: A literature review. *JRSM Short Rep* 2012; 3:33

Published online first on February 18, 2020. From the Department of Anesthesiology and Critical Care Medicine (A.J.S., S.H., J.L.) and Department of Surgery, Division of Plastic Surgery (D.W.L.), Children's Hospital of Philadelphia, Philadelphia, Pennsylvania; Department of Clinical Anesthesiology and Critical Care (A.J.S., S.H., J.L.) and Department of Surgery, Division of Plastic Surgery (D.W.L.), Perelman School of Medicine, University of Pennsylvania, Philadelphia, Pennsylvania.

Copyright © 2020, the American Society of Anesthesiologists, Inc. All Rights Reserved. *Anesthesiology* 2020; 132:1556. DOI: 10.1097/ALN.0000000000003219