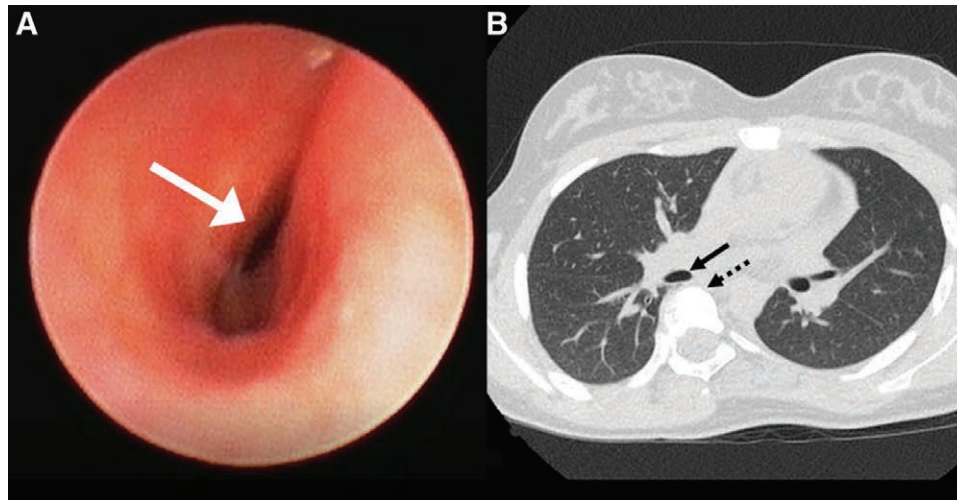


# Bronchus Intermedius Compression from Idiopathic Thoracic Scoliosis

Meenakshi Atteri, M.D., Christopher Allphin, M.D., Mohamed Mahmoud, M.D., Michale S. Ok, M.D.



A 14-yr-old female with adolescent idiopathic thoracic dextroscoliosis, moderate restrictive lung disease on pulmonary function testing, and persistent cough presented for posterior spinal fusion. After induction, flexible bronchoscopy revealed moderate to severe obstruction of the bronchus intermedius (image A, *white arrow*, and Supplemental Digital Content, <http://links.lww.com/ALN/C349>). The preoperative computed tomography scan demonstrates how the thoracic spine (image B, *black dotted arrow*) compresses the bronchus intermedius (image B, *black arrow*).

Idiopathic scoliosis can have significant effects on the respiratory system, including decreased lung volumes, impaired respiratory mechanics, decreased lung and chest wall compliance, and even pulmonary hypertension or respiratory failure if the curvature is severe.<sup>1</sup> Although restrictive lung disease is the most prevalent abnormality on pulmonary function testing in idiopathic scoliosis, obstructive or mixed lung disease has also been reported.<sup>1,2</sup> Specifically, bronchus intermedius obstruction is thought to occur when the natural thoracic kyphotic curve is lost as a result of dextroscoliosis.<sup>3</sup> This leads to the thoracic spine pushing forward onto the bronchus intermedius, resulting in external compression and obstruction.

Bronchial compression should be included in the differential diagnosis when patients with thoracic scoliosis are difficult to oxygenate or ventilate. Flexible bronchoscopy will provide rapid assessment of the airway and may prevent

unnecessary interventions which will ultimately be futile without surgical correction. Flexible bronchoscopy may be useful in confirming the resolution of airway compression after surgical correction of the spinal curvature. Patients with signs of respiratory dysfunction such as resting hypoxemia, dyspnea on exertion, or persistent cough should be considered for further pulmonary evaluation, including pulmonary function testing and radiographic examination.

## Competing Interests

The authors declare no competing interests.

## Correspondence

Address correspondence to Dr. Atteri: [Meenakshi.atteri@cchmc.org](mailto:Meenakshi.atteri@cchmc.org)

## References

1. Tsiligiannis T, Grivas T: Pulmonary function in children with idiopathic scoliosis. *Scoliosis* 2012; 7:7
2. Bartlett W, Garrido E, Wallis C, Tucker SK, Noordeen H: Lordoscoliosis and large intrathoracic airway obstruction. *Spine (Phila Pa 1976)* 2009; 34:E59–65
3. Farrell J, Garrido E: Effect of idiopathic thoracic scoliosis on the tracheobronchial tree. *BMJ Open Respir Res* 2018; 5:e000264

Supplemental Digital Content is available for this article. Direct URL citations appear in the printed text and are available in both the HTML and PDF versions of this article. Links to the digital files are provided in the HTML text of this article on the Journal's Web site ([www.anesthesiology.org](http://www.anesthesiology.org)).

Published online first on April 14, 2020. From the Department of Anesthesia, Cincinnati Children's Hospital Medical Center, Cincinnati, Ohio.

Copyright © 2020, the American Society of Anesthesiologists, Inc. All Rights Reserved. *Anesthesiology* 2020; 133:195. DOI: 10.1097/ALN.0000000000003311