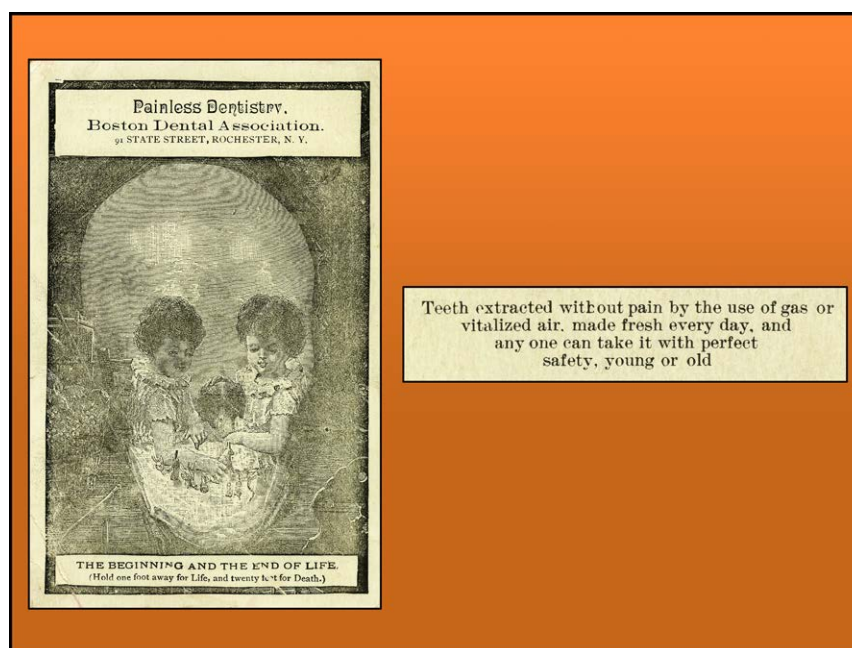


- free radicals in intact rabbit hearts subjected to ischemia and reflow. *J Biol Chem* 1993; 268:18532–41
47. Zorov DB, Juhaszova M, Sollott SJ: Mitochondrial reactive oxygen species (ROS) and ROS-induced ROS release. *Physiol Rev* 2014; 94:909–50
  48. Shigenaga MK, Hagen TM, Ames BN: Oxidative damage and mitochondrial decay in aging. *Proc Natl Acad Sci U S A* 1994; 91:10771–8
  49. Landis GN, Abdueva D, Skvortsov D, Yang J, Rabin BE, Carrick J, Tavaré S, Tower J: Similar gene expression patterns characterize aging and oxidative stress in *Drosophila melanogaster*. *Proc Natl Acad Sci U S A* 2004; 101:7663–8
  50. Lopez MG, Hughes CG, DeMatteo A, O’Neal JB, McNeil JB, Shotwell MS, Morse J, Petracek MR, Shah AS, Brown NJ, Billings FT 4th: Intraoperative oxidative damage and delirium after cardiac surgery. *ANESTHESIOLOGY* 2020; 132:551–61
  51. Rosenfeldt F, Marasco S, Lyon W, Wowk M, Sheeran F, Bailey M, Esmore D, Davis B, Pick A, Rabinov M, Smith J, Nagley P, Pepe S: Coenzyme Q10 therapy before cardiac surgery improves mitochondrial function and *in vitro* contractility of myocardial tissue. *J Thorac Cardiovasc Surg* 2005; 129:25–32

## ANESTHESIOLOGY REFLECTIONS FROM THE WOOD LIBRARY-MUSEUM

### Boston Skulling, Not Sculling: Anesthetic Advertising by Daring Dentists



Because this month is one in which Americans celebrate the haunting holiday of Halloween, this October Anesthesiology Reflection presents one of the more ghoulish trade cards used in advertising anesthesia. From their State Street office in Rochester, New York, the Boston Dental Association used a grinning skull on the obverse of their ill-advised advertisement to promote both pure and adulterated nitrous-oxide (“vitalized air”) anesthetics for dental surgery. The association boasted that their anesthetic gases were “made fresh every day” and that “any one can take it with perfect safety, young or old” (*right*, extracted from the card’s reverse). To underscore their claim, the association issued this trade card (*left*) as a “treat” depicting a “trick” image that symbolized Life (two young girls playing with a puppy) when viewed from “one foot away” and, in an optical illusion, depicted Death (a grinning skull) from 20 feet away. Ironically, the skull, advertising “the beginning and the end of life” on this 1890 trade card, may have foreshadowed the association’s demise...that same year. (Copyright © the American Society of Anesthesiologists’ Wood Library-Museum of Anesthesiology, Schaumburg, Illinois.)

*Melissa L. Coleman, M.D., Penn State College of Medicine, Hershey, Pennsylvania, and George S. Bause, M.D., M.P.H., Case Western Reserve University, Cleveland, Ohio.*